

Complete Remission of Lambert-Eaton Myasthenic Syndrome after Successful Treatment of Small-Cell Lung Cancer

Thomas Zambelis*, Vassiliki Zouvelou and Nikolaos Karandreas

Department of Neurology, University of Athens, Aeghinition Hospital, EMG laboratory, Athens, Greece.

*Corresponding author: Thomas Zambelis, Aeghinition Hospital. 74, Vass. Sofias Ave. 11528Athens, Greece, Tel: +30210-7250410; E-mail: tzabelis@med.uoa.gr

Received date: 20 July 2015; Accepted date: 25 August 2015; Published date: 30 August 2015.

Citation: Zambelis T, Zouvelou V, Karandreas N (2015) Complete Remission of Lambert-Eaton Myasthenic Syndrome after Successful Treatment of Small-Cell Lung Cancer. Autoimmun Infec Dis 1 (1): doi <http://dx.doi.org/10.16966/2470-1025.105>

Copyright: © 2015 Zambelis T, et al. This is an open-access article distributed under the terms of the Creative Commons Attribution License, which permits unrestricted use, distribution, and reproduction in any medium, provided the original author and source are credited.

Keywords: Lambert-eaton myasthenic syndrome; Small cell lung cancer

Introduction

Lambert-Eaton myasthenic syndrome (LEMS) is a rare presynaptic autoimmune disease of the neuromuscular transmission with an incidence of 0.5 per million and a prevalence of 3.4 per million [1]. It is mediated by antibodies directed mainly against P/Q type of voltage-gated calcium channels (VGCC) which are detected in about 85%-90% of the patients [2]. A tumor, mainly a small cell lung cancer (SCLC) is detected in about 60% of the patients [3,4] while other tumors (thymoma, lymphoma, leukemia, prostate cancer) are rarely diagnosed. Remission of symptoms is rare in the SCLC-LEMS. In the non-tumor-LEMS (NT-LEMS) the prognosis is favorable [5] while in the tumor LEMS (T-LEMS) it is related to tumor treatment [6].

Case Report

A 58 years old man, ex smoker, was referred for electrodiagnostic consultation because of fluctuating proximal weakness for the last 6 months, dry mouth, sexual dysfunction and mild constipation. Neurologic examination showed weakness of the proximal limb muscles and absent tendon reflexes. Compound muscle action potential (CMAP) from abductor digiti minimi (ADM) was 3.8 mV at rest and showed increment 138% (9mV) immediately after 10 seconds of maximal muscle contraction (Figure 1). Repetitive nerve stimulation (RNS) showed a decrement of CMAP 24% at 3Hz and an increment 176% at 30Hz. With the diagnosis of LEMS the patient was admitted to the hospital. SCLC was diagnosed by Chest CT and biopsy (the patient had no symptoms of SCLC). VGCC antibodies were positive. The patient was transferred to an oncologic department and the tumor was treated with chemotherapy and radiotherapy. Amifampridine 10 mg x3 was prescribed. When back at home the patient felt well and referred no weakness. We saw him 3 months later. There was no muscle weakness and the tendon reflexes were reduced. Amifampridine was withdrawn and a new electrophysiological study was performed one week later. CMAP amplitude at rest from ADM was 22 mV and RNS was normal and VGCC antibodies were not found. On follow up, on July 2015, one and half year from amifampridine withdrawal, the patient is still asymptomatic.

Discussion

LEMS is a presynaptic autoimmune or paraneoplastic neuromuscular junction disorder. About 60% of patients with LEMS have a SCLC [4]. The syndrome is frequently misdiagnosed and the time to diagnosis is 0.6-40 months after the onset of the symptoms in the SCLC-LEMS [3].

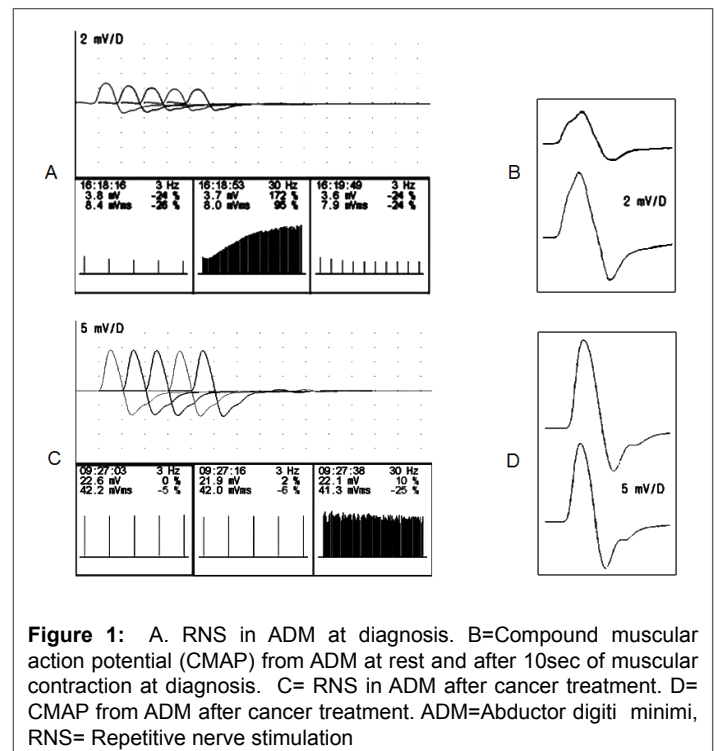


Figure 1: A. RNS in ADM at diagnosis. B=Compound muscular action potential (CMAP) from ADM at rest and after 10sec of muscular contraction at diagnosis. C= RNS in ADM after cancer treatment. D= CMAP from ADM after cancer treatment. ADM=Abductor digiti minimi, RNS= Repetitive nerve stimulation

Clinically it presents proximal muscle weakness, absent tendon reflexes and autonomic symptoms mainly dry mouth, erectile dysfunction and constipation. Electrophysiologically it is characterized by a triad of findings: Low amplitude of compound muscle action potential (CMAP) at rest, a decrement of CMAP amplitude at low rates (2-5 Hz) of repetitive nerve stimulation (RNS), and an increment in CMAP amplitude (>100%) at high rates of stimulation (30-50Hz) or after 10-15 seconds of maximal voluntary contraction [7]. Remission of symptoms is rare in the SCLC-LEMS. Chalk et al [6] reported neurological improvement in 7 of their 13 patients with SCLC and one showed complete remission for seven years. There are also a few cases of LEMS associated with thymoma remitted after successful treatment of the tumor [8,9].

Our patient presented a SCLC-LEMS diagnosed six months from the onset of the symptoms and remitted completely (clinically,

electrophysiologically and serologically) after successful treatment of the tumor. The remission of LEMS and the absence of VGCC antibodies after SCLC treatment is a clear evidence of the paraneoplastic nature of the disease. The reduction or removal of the antigen with the treatment of the SCLC may improve or completely cure the LEMS [6].

References:

1. Wirtz PW, Nijhuis MG, Sotodeh M, Willems LNA, Brahim JJ, et al. (2003) The epidemiology of myasthenia gravis, Lambert-Eaton myasthenic syndrome and their associated tumors in the northern part of the province of South Holland. *J Neurol* 250: 698-701.
2. Motomura M, Lang B, Johnston I, Palace J, Vincent A, et al. (1997) Incidence of serum anti-P/Q-type and anti-N-type calcium channel autoantibodies in the Lambert-Eaton myasthenic syndrome. *J Neurol Sci* 147: 35-42.
3. Titulaer MJ, Maddison P, Sont JK, Wirtz PW, Hilton-jones D, et al. (2011) Clinical Dutch-English Lambert-Eaton myasthenic syndrome (LEMS) tumor association prediction score accurately predicts small-cell lung cancer in the LEMS. *J Clin Oncol* 29: 902-908.
4. O'Neill JH, Murray NM, Newsom-Davis J (1988) The Lambert-Eaton myasthenic syndrome. A review of 50 cases. *Brain* 111: 577-596.
5. Maddison P, Lang B, Mills K, Newsom-Davis J (2001) Long term outcome in Lambert-Eaton myasthenic syndrome without lung cancer. *J Neurol Neurosurg Psychiatr* 70: 212-217.
6. Chalk H, Murray NMF, Newsom-Davis J, O'Neill JH, Spiro SG (1990) Response of the Lambert-Eaton myasthenic syndrome to treatment of associated small-cell lung carcinoma. *Neurology* 40: 1552-1556.
7. AEEM quality assurance committee (2001) Literature review of the usefulness of repetitive nerve stimulation and single fiber EMG in the electrodiagnostic evaluation of patients with suspected myasthenia gravis or Lambert-Eaton myasthenic syndrome. *Muscle Nerve* 24: 1239-1247.
8. Fernandez-Torron R, Arcocha J, Lopez-Picazo JM, Pardo J, Tamura MA, et al. (2011) Isolated dysphagia due to paraneoplastic myasthenic syndrome with anti-P/Q-type voltage-gated calcium-channel and anti-acetylcholine receptor antibodies. *Neuromusc Disord* 21: 126-128.
9. Morimoto M, Osaki T, Nagara Y, Kodate M, Motomura M, Murai H (2010) Thymoma with Lambert-Eaton myasthenic syndrome. *Ann Thor Surg* 89: 2001-2003.