

Splenic Infarct Due to Wandering Spleen in an Adult Patient

Solano Díaz P*, Sánchez Linares LM and Briceño García EM

Hospital Regional Carlos Haya, Málaga, España

*Corresponding author: Solano Díaz P, Hospital Regional Carlos Haya, Málaga, España, E-mail: psd_1980@hotmail.com

Received date: 30 Mar 2017; Accepted date: 05 May 2017; Published date: 11 May 2017.

Citation: Solano Díaz P, Sánchez Linares LM, Briceño García EM (2017) Splenic Infarct Due to Wandering Spleen in an Adult Patient. J Clin Case Stu 2(3): doi <http://dx.doi.org/10.16966/2471-4925.144>

Copyright: © 2017 Solano Díaz P, et al. This is an open-access article distributed under the terms of the Creative Commons Attribution License, which permits unrestricted use, distribution, and reproduction in any medium, provided the original author and source are credited.

Case Presentation

We present the case of an eighteen years old woman with the maturational disorder who went to the emergency area because of abdominal pain, focused on the left iliac fossa, fever and vomiting, since four days ago. The blood test showed 15.000 leukocytes, with 81% of neutrophils and PCR, 154. On the physical exploration, a mass on the left quadrant was noticed and positive peritonism signs. The imaging diagnosis consisted of an abdominal X-ray that displayed a lack of sign on the left quadrant and displacement of the bowel luminogram (Figure 1a). Due to these findings, the patient underwent an ultrasound scan, identifying a big and low left positioned spleen, which leads us to complete a CT scan with intravenous iodinated contrast. The CT scan confirmed splenomegaly of 15.6 cm and a wrong localization of the spleen at the left iliac fossa. Not only the spleen showed a low enhancement over more than the 60 percent, (figures 1b and 1c) which correlated with splenic infarct; but wheel sign on the splenic hilus that indicated completed torsion, too (Figure 1d). These findings were in connection with splenic infarct due to twisted hilus in a wandering spleen context. The woman underwent a casualty surgery by laparotomy which confirmed the whole torsion of the splenic vascular pedicle, including the pancreatic tail, and the massive splenic infarct (Figure 1e). Despite the detorsion of the splenic vascular hilus, total splenectomy could not be avoided. After a fair postoperative evolution, the patient was discharged by adding vaccination recommendations against encapsulated germs, through the acquired cell immunodeficiency due to splenectomy.

Wandering spleen is a rare clinical entity that results from a wrong laxity of the suspensory spleen ligaments [1].

This can become a cause of splenectomy in a 0.5% of the cases. In the revised literature this pathology is more frequent in the pediatric population [2,3]. There are congenital and acquired causes. On one hand, the congenital causes include laxity of the gastrosplenic ligament due to an incomplete fusion of the dorsal mesogastrium around the fifth week in the embryonal life [4]. That is the reason why we can find it in people under 10 years old. And on the other hand, we can find it for adults from 20 to 40 years old, more frequently in women, for 15 times more, perhaps, because of the hormonal influx [5].

However, acquired causes as splenomegaly or abdominal hit cannot be discarded [6]. Symptoms can stand very changeable, depending on the level of vascular torsion, reaching several possibilities: from no pain until acute abdomen because of the splenic infarct [1,5]. We must also consider the chronic torsion, in which symptoms will be more larvated. This fact can trigger a congestive spleen and moreover, chronic abdominal pain episodes. Complete torsion can develop an acute infarct and the acute abdominal pain [1].

Diagnosis

Diagnosis can turn difficult in this entity. Ultrasound scan gives the wrong location and lack of Doppler sign.

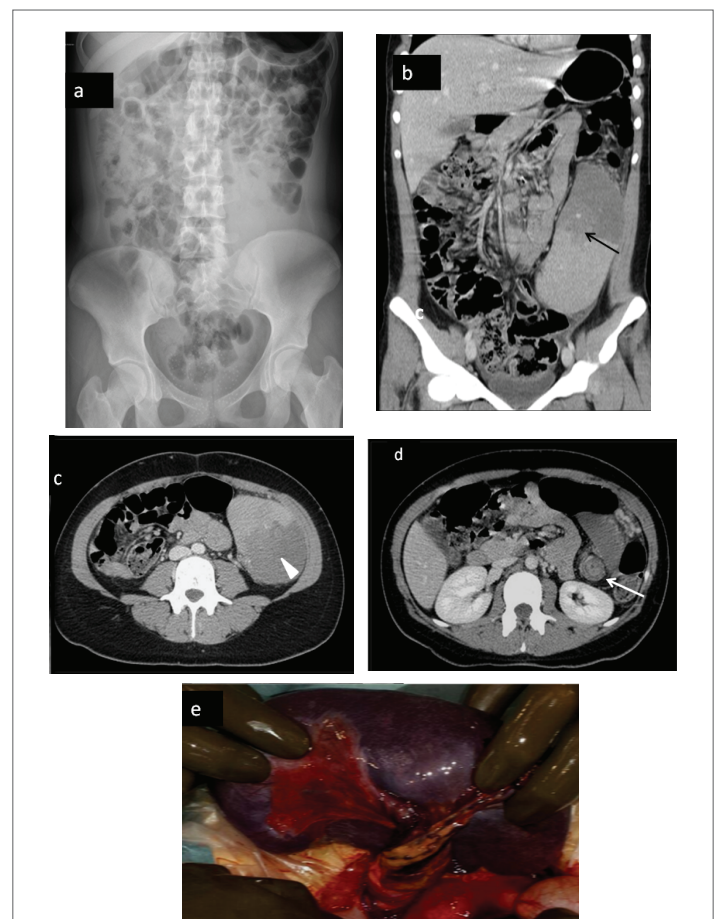


Figure 1: a) Abdominal X-Ray: displacement of the bowel and lack of gas on left low quadrant
b and c) Multiplanar reconstruction of CT scan; splenomegaly and wrong position of the spleen with the long infarcted area. See the correlation with X-Ray imaging
d) Axial imaging of CT-scan: lack of attenuation in the infarcted area (head of the arrow) and 'whirlpool sign' (white arrow) specific of vascular hilus torsioned
e) Surgical imaging with the infarcted spleen and the hole torsion of vascular splenic hilus including the pancreatic tail

CT scan shows the lack of splenic enhancement and whirlpool sign that becomes the most specific sign of splenic torsion [5]. However, definitive diagnosis is given by angiography, where lack of vascular supply is shown [7].

In our case, abdominal x-ray imaging supposed an important clue, as the displacement of gutter was identified and furthermore, US and CT scan for confirmation of the wandering spleen and the massive infarct. Differential diagnosis must include ovarian cyst, tubo ovarian abscess, diverticulitis, intestinal obstruction and acute pancreatitis [5]. We can find several complications as; splenic abscess, gangrene, peritonitis, and pancreatic tail necrosis, as in our case, too [7]. Gastric volvulus can be included in the pediatric population [8].

Treatment

Treatment consists of surgery. Diverse options can be contemplated depending on splenic ischemic degree: from splenopexy to partial or total splenectomy (opened or laparoscope access).

In our case patient underwent complete splenectomy [1]. There are studies where imperative splenectomies were carried out with exit index similar to open splenectomy [9]. Finally, vaccination against encapsulated germs like as *S. pneumonia*, *H. influenzae* and *N. Meningitidis* [6] must offer to the patient.

Conclusion

In conclusion, we think this case can become important because wandering spleen establishes a funny abdominal pain, furthermore in adult people. This etiology must be included in the differential diagnosis of recurrent left quadrant pain in young people. Imaging diagnosis can confirm the cause, and consequently avoid splenectomy and secondary cell immunodeficiency.

Conflict of Interest

All authors have participated in this work and the final version has been approved by all of them.

We have no conflict of interest.

References

1. Chauhan NS1, Kumar S (2016) Torsion of a Wandering Spleen Presenting as Acute Abdomen. *Pol J Radiol* 81: 110-113.
2. Brown CV, Virgilio GR, Vazquez WD (2003) Wandering spleen and its complications in children: a case series and review of the literature. *J Pediatr Surg* 38: 1676-1679.
3. Zúñigar S, Soto G, Ronco R, Abarca K, García C (2002) Bazo errante complicado: el caso de un lactante de 13 meses. *Rev. Chilena de Cirugía* 4: 396-400.
4. Freeman JL, Jafri SZ, Roberts JL, Mezwa DG, Shirkhoda A (1993) CT of congenital and acquired abnormalities of the spleen. *Radiographics* 13: 579-610.
5. Sarría Octavio de Toledo L, Cozcolluela Cabrejas R, García Asensio S, Martínez-Berganza T (2011) Wandering spleen associated to inflammatory pseudotumor. *Radiología* 48: 173-176.
6. Hussain M, Deshpande R, Bailey ST (2010) Splenic torsion: a case report. *Ann R Coll Surg Engl* 92: W51-W52.
7. Shelfin JR, Lee CM, Kretchmar KA (1984) Torsion of wanderin spleen and distal pancreas. *AJR Am J Roentgenol* 142: 100-101.
8. Chawla S, Boal DK, Dillon PW (2003) Splenic Torsion. *Radiographics* 23: 305-308.
9. Planellas P, Farrés R, Rodríguez JI, Pujadas M, Codina A (2012) Laparoscopic approach of acute abdomen by splenic torsion. *Spanish Surgery* 90: 54-67.