

Primary Vaginal Stones in an 11-Year-Old Girl

Samera F AlBasri^{1*}, Mahmoud Al Garoushah¹, Mohammad Hani², Hasan Farsi² and Hanan Shamrani¹¹Department of Obstetrics and Gynecology, King Abdulaziz University Hospital, Jeddah, Kingdom of Saudi Arabia²Department of Urology, King Abdulaziz University Hospital, Jeddah, Kingdom of Saudi Arabia***Corresponding author:** Samera F AlBasri, Department of Obstetrics and Gynecology, King Abdulaziz University Hospital, Jeddah, Kingdom of Saudi Arabia, **E-mail:** salbasri@kau.edu.sa**Received date:** 08 Jan 2017; **Accepted date:** 28 Aug 2017; **Published date:** 31 Aug 2017.**Citation:** AlBasri SF, Garoushah MA, Hani M, Farsi H, Shamrani H (2017) Primary Vaginal Stones in an 11-Year-Old Girl. *J Clin Case Stu* 2(4): doi <http://dx.doi.org/10.16966/2471-4925.150>**Copyright:** © 2017 AlBasri SF, et al. This is an open-access article distributed under the terms of the Creative Commons Attribution License, which permits unrestricted use, distribution, and reproduction in any medium, provided the original author and source are credited.**Abstract**

Primary vaginal stones are a rare finding in children and removal can sometimes be challenging. We describe an 11-year-old girl who was referred to our department for recurrent urinary tract infections and continuous urinary incontinence. Clinical and paraclinical examination revealed findings consistent with vaginal stones. Diagnostic studies of kidney and bladder function showed no abnormalities, but radiographs revealed a highly calcified mass exerting pressure on the bladder. Examination under anesthesia revealed no fistula, and urethrocytostcopy revealed no stones or abnormalities, except for a short, wide urethra pulled backward by a mass-like structure. After informed consent and double J catheter insertion, a second procedure to disintegrate the stones involved the insertion of a nephroscope into the vagina and the use of an ultrasonic device. Three-month follow-up showed resolution of incontinence. We recommend vaginoscopy to visualize the vagina and cervix and to facilitate instrumentation in young girls.

Keywords: Incontinence; Lithotripsy; Vaginal stone; Vaginoscopy**Introduction**

Primary vaginal stones are very rare and typically arise from the stasis of urine in the vagina or as a result of an anatomical defect (e.g. fistula). In children without anatomical defects, vaginal stones are usually formed following crystallization around a foreign body [1]. In our case, even though no fistula was seen on examination, the stone was considered to be primary because analysis of the stone helped eliminate the possibility of a foreign body. In young girls, diagnosis and removal of such stones are challenging, but utilization of vaginoscopy for diagnosis and, with the aid of a nephroscope, disintegration using a lithotripsy device are effective [2]. We describe an 11-year-old girl with vaginal stone who presented with recurrent urinary tract infections and continuous urinary incontinence.

Case

An 11-year-old girl was referred with recurrent febrile urinary tract infections and continuous urinary incontinence since early childhood, which was suspected to be the result of the pressure effect of a pelvic mass seen on radiographic examination (Figure 1). The patient was a term infant who underwent laparotomy for abdominal distension on her first day of life, followed the next day by transvaginal drainage of fluid. No medical report existed to clarify the condition, and the parents could provide no further information on her neonatal course. Thereafter, no concerns were noted by the parents until toilet training, when they reported she continuously wet herself. She had frequent hospital visits for antibiotic treatment of recurrent urinary tract infections but never required hospitalization. She was continent for gas and stool, and a review of other systems was unremarkable.

On physical examination, she appeared uncomfortable but was of normal weight and height for her age and race. Pelvic examination was deferred until the patient was under anesthesia, but, except for a transverse mid-abdominal scar from her previous surgery, no abnormalities were noted in the rest of the examination (no abdominal mass was felt) (Figure2)

- Ultrasonography of abdomen demonstrated no dilatation of the kidneys and a bladder void of urine.
- No sign of reflux was detected on a voiding cystogram and renal function appeared normal.
- Ultrasound of the pelvis was limited because of an inability to fill the bladder.
- A computed tomography scan revealed a highly calcified mass behind the urinary bladder measuring 5 × 6 cm, but was otherwise normal.
- A cystometrogram showed normal bladder capacity and contractility.

Thus, laparotomy was offered with the intent of incising the bladder and removing the mass. However, no bladder stones were identified during the procedure, but the urethra appeared to be short and wide, and pulled backward and upward by a mass-like structure behind the bladder trigone. A methylene blue dye test was performed and excluded a fistula (the dye did not appear in the vagina when instilled in the bladder).

During an examination of the rectum, two apparently mobile stones were palpated in the vagina. No structural anomalies of the vulva or hymen were detected. Vaginoscopy identified a large stone, which precluded removal due to its size and hardness. A second intervention was scheduled after intra operative consultation with a urologist, who inserted a double J catheter for retrograde pyelography the following day; the results of this study were normal (Figure 3). The patient's parents were informed, and a different approach was suggested for the second procedure. After general anesthesia, a small nasal speculum was used to examine the vaginal stones. The stones were then successfully disintegrated using pneumatic lithoclast, and the fragments were extracted completely and sent for analysis. No mass was palpable after repeated digital examination. Successive examinations demonstrated an intact vaginal wall and the absence of stones in the vagina. Stone analysis revealed a calcium oxalate composition. The patient's pressure symptoms completely disappeared,

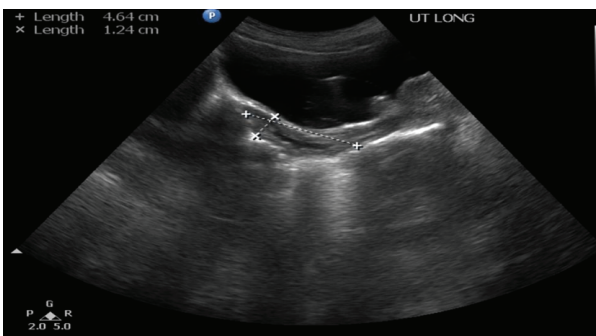


Figure 1: Pelvic ultrasound imaging: Normal size and shape of uterus with pressure effect from highly calcified mass at the level of vagina of unknown origin

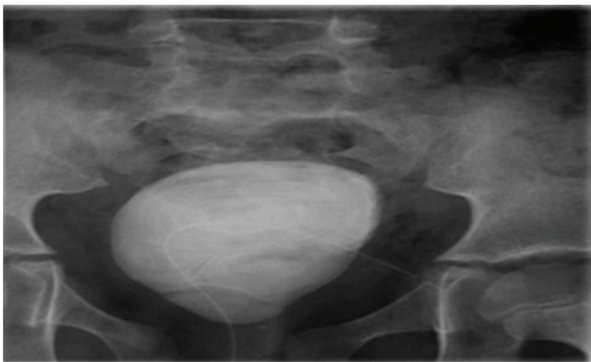


Figure 2: Preoperative pelvic x-ray: Highly calcified mass of smooth surface in the pelvic area.

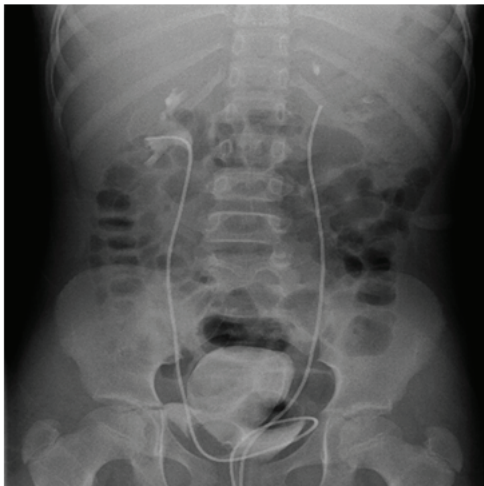


Figure 3: Intraoperative double J stent: Normal urinary system

and she was discharged the following day on antibiotics, with readmission and follow-up evaluation planned in 6-8 weeks.

Six weeks later, she was doing very well with daytime continence and only nocturnal enuresis. Follow-up examination under anesthesia and cystoscopy showed no abnormalities, and the urethra appeared almost normal. Regular follow-up was planned for every 3 months.

Discussion

This report describes a case of primary vaginal stones diagnosed in an 11-year-old girl. Primary vaginal stones are caused by several factors, including anatomical defects, neurogenic diseases affecting bladder and

urethral function, vaginal obstructive lesions (e.g. stricture, septum), prolapse of anterior vaginal wall (e.g. cystocele), urethral diverticulum and genitourinary system anomalies (e.g. ectopic vaginal ureter); primary stones may also be seen in association with obstructive uterine anomalies [3-6].

No genitourinary tract abnormalities were detected on initial examination of the patient, but the definitive diagnosis was based on examination under anesthesia and endoscopic examination. A vesicovaginal fistula was excluded by urethroscopy and instillation of methylene blue into the bladder. Because the patient's hymen was intact, it was unlikely that her symptoms were due to the presence of a foreign body in the vagina.

Neurological disease was excluded since the patient had normal intellectual development and was continent for gas and stool. In general, the pooling of urine in the vagina is due to incontinence, whereas vaginal stones can be formed as a result of infection following contamination of the urine with stool. Urease-producing bacteria appear to be a major factor of stone formation in the vagina [7]. These bacteria change the normally acidic pH of the vagina to an alkaline pH, consequently increasing the risk of stone formation (specifically triple phosphate calculi). However, in this case, analysis showed a different stone composition. The comparatively low levels of estrogen in prepubertal girls and postmenopausal women can also cause an alkaline vaginal pH due to the absence of lactic acid, which may increase an individual's risk of developing infections due to urease-producing bacteria [8-10]. Young patients might also benefit from nephroscopy when vaginoscopy is recommended. Moreover, in cases where instrumentation is needed, nephroscopy can provide further benefits. In prepubertal girls, a better panoramic view of the vagina can be obtained by using a vaginoscope with an irrigating endoscope (such as a nephroscope) compared to a nasal speculum.

Shock wave lithotripsy has been demonstrated to be beneficial in stone breakage. However, it is thought that therapeutic ultrasound can cause soft tissue damage through driving bubble activity [11]. One area that has been extensively studied is the role of cavitation in both natural and artificial kidney stones. In fact, it is thought that cavitation bubble activity helps in the stone breaking process, and findings from previous studies suggest that these bubble interactions contribute to the tissue injury that occurs during shock wave treatment [12-14]. In one report [15], investigators used high-speed photography to demonstrate that cavitation helped in stone fragmentation through erosion and pitting. Further, they suggested a possible link between cavitation bubble cluster activity and the formation of fractures in kidney stones in shock wave treatment.

Overall, primary vaginal stone is a rare finding in prepubertal girls, and it is probably caused by the interaction of several factors, including urinary stasis, contamination with stool, and chronic infection. A nephroscope and vaginoscopy might be beneficial in visualizing the vagina in prepubertal patients. As demonstrated in our case, vaginal stones can be disintegrated and safely removed using a pneumatic lithoclast.

References

1. Kolte SP, Choube S, Phulare S, Johrapurkar SR (2002) Primary Vaginoliths. *Ind J Radiol Imag* 12: 511-512.
2. Jaspers JW, Kuppens SM, van Zundert AA, de Wildt MJ (2010) Vaginal stones in a 5-year-old girl: a novel approach of removal. *J Pediatr Adolesc Gynecol* 23: e23-e25.
3. Venet C, Clapuyt P, Wese FX (1997) Vaginal stone in a teenager. *Br J Urol* 79: 804-805.
4. Thompson JD, Rock JA (1992) *Te Linde's Operative Gynecology*. 10th ed. Philadelphia: Lippincott 275.
5. Petrillo CR, Borelli M, Botelho C (1981) Primary vaginal calculus in a patient with meningomyelocele. *Arch Phys Med Rehabil* 62: 227-229.

6. Miller, Norman L (1973) Primary Vaginal Stones. *Obstet Gynecol* 41: 459-460.
7. Liu B, Huang X, Lu J, Zhang Z, Wang P, et al. (2008) Vaginal calculi secondary to urethrovaginal fistula with vaginal stenosis in a 14-year-old girl. *Urol Res* 36: 73–75.
8. Navani S, Tessier PA (1970) A primary vaginal stone. *Br J Radiol* 43: 222-223.
9. Tsung-Chin Ho, Lina LI (2008) Primary Vaginal Stone in a Young Active Woman. *Taiwan J Obstet Gynecol* 47: 457-459.
10. Bissada NK, Hanash KA (1983) Primary vaginal stones. *Urology* 21: 512-513.
11. Movahed P, Kreider W, Maxwell AD, Dunmire B, Freund JB (2017) Ultrasound-Induced Bubble Clusters in Tissue-Mimicking Agar Phantoms. *Ultrasound Med Biol* 43: 2318-2328.
12. Evan AP, Willis LR, McAteer JA, Bailey MR, Connors BA, et al. (2002) Kidney damage and renal functional changes are minimized by waveform control that suppresses cavitation in shock wave lithotripsy. *J Urol* 168: 1556-1562.
13. Sapozhnikov OA, Bailey MR, Crum LA, Miller NA, Cleveland RO, et al. (2001) Ultrasound-guided localized detection of cavitation during lithotripsy in pig kidney in vivo. *Proc IEEE Ultrasonics Symp.*
14. Zhong P, Zhou Y, Zhu S (2001) Dynamics of bubble oscillation in constrained media and mechanisms of vessel rupture in SWL. *Ultrasound Med Biol* 27: 119-134.
15. Pishchalnikov YA, Sapozhnikov OA, Bailey MR, Williams JC Jr, Cleveland RO, et al. (2003) Cavitation bubble cluster activity in the breakage of kidney stones by lithotripter shockwaves. *J Endourol* 17: 435-446.