

New Technique to Overcome Vasovagal Syncope

Shahd Al Nojaidi¹, Najd Al Nojaidi², Taif Al Nojaidi³, Sawsan Al Yousef^{4,5*}, Shahd Al Yousef², Daad Al Yousef⁶, Faisal Al Amri^{4,5}, Mohammad Al Amar^{4,5} and Jalal Froukh^{4,5}

¹Dental student at DarAlUloom University, Riyadh, Saudi Arabia

²Medical Student at Almaarefa University, Riyadh, Saudi Arabia

³Medical student at Allmamm University, Riyadh, Saudi Arabia

⁴Pediatric Intensive care consultant, Riyadh, Saudi Arabia

⁵King Fahad Medical City Center for Research, Education & Simulation Enhanced Training (CRESENT), Riyadh, Saudi Arabia

⁶Riyadh Dental College, Riyadh, Saudi Arabia

Received: 11 Oct, 2018 | **Accepted:** 31 Oct, 2018 | **Published:** 06 Nov, 2018

***Corresponding author:** Sawsan Al Yousef, King Fahad Medical City Center for Research, Education and Simulation Enhanced Training (CRESENT), Riyadh, Saudi Arabia, E-mail: sawsan_35@hotmail.com

Citation: Al Nojaidi S, Al Nojaidi N, Al Nojaidi T, Al Yousef S, Al-Yousef S, et al. (2018) New Technique to Overcome Vasovagal Syncope. J Clin Case Stu 3(4): dx.doi.org/10.16966/2471-4925.177

Copyright: © 2018 Al Nojaidi S, et al. This is an open-access article distributed under the terms of the Creative Commons Attribution License, which permits unrestricted use, distribution, and reproduction in any medium, provided the original author and source are credited.

Abstract

Vasovagal syncope is common in clinical practice, and referred to as neurocardiogenic syncope [1,2]. Vasovagal syncope is noncardiogenic kind of syncope, and it is different from orthostatic hypotension [3]. At initial stage of vasovagal syncope, there are tachycardia with normal blood pressure followed by bradycardia which leads to decrease blood flow to the brain, causing brief lose consciousness. Vasovagal syncope mostly proceeded by sight of blood or extreme emotional distress [4]. It is usually harmless and does not require treatment, unless there is a trauma risk during vasovagal syncope episode. There are several maneuver mentioned in literature to prevent it as the Applied Tension Technique (which was developed by Lars-Göran Öst). The technique involves tensing the muscles in the body, which will raise the blood pressure and so reduces faint episodes [5]. We report a case in which she completely recovered from vasovagal syncope after using a venepuncture training Pad.

Case report

A 20-year-old female dental student was completely healthy and asymptomatic till the age of 17 years when she fainted during blood extraction test, second similar episodes at age of 19 years following blood sight for college test, after this patient was trained on tension technique also had different exposures by watching movies on blood extraction and surgeries, but in spite of these methods, recently she developed third episode after vaccination. All the 3 episodes were short for 1 minute and recovered fast after laying her down and raising her feet up she developed nausea and lightheadedness for 30 minutes during recovery phase. There was no history of orthostatic hypotension, cardiac or neurological abnormalities, has strong family history of similar symptoms in mother, two of her uncles and grandfather from mother side. Physical examinations including vital signs were all normal. Her resting heart rate of 75 beat/minute and blood pressure of 110/75 mm Hg. So just before patient start her clinical practice in dentistry, she was trained on venepuncture Pad (Figure 1) simulator which used to train nurses and junior physician on blood extraction and intravenous canulation which has blood like color solution (Figure 2). While the patient was doing her first trial on the venepuncture pad she felt sweating and dizziness when she saw the blood but only for few seconds without fainting then she resumed the training smoothly, she continued training on the venepuncture pads

several time per day for 3 days without any problem. One month later, patient start her clinical training at dentistry college (4th year) and she was able to inject anesthesia to patients without any complication also she received her 3rd dose of hepatitis vaccine and she was totally asymptomatic.

Discussion and Conclusion

Typical and infrequent vasovagal syncope usually diagnosed by history only and do not need further investigation such as head-up tilt-table test (HUTT) which is usually required for atypical features, seizure activity and older patients [6]. Avoiding the trigger event is the best treatment for infrequent and typical presentation of vasovagal syncope [7]. But this is not feasible in our patient as she is dentistry student. Medical therapy such as beta-adrenergic blockers did not show efficacy in preventing syncope [8], other studies showed that repeated exposure to triggers can decrease fear, if not then apply tension physical maneuvers which showed its effectiveness on certain patients [9] and it is done by alternating action of muscle tensing in arms, trunk, buttocks, while crossing the legs for 10 to 15 seconds followed by body relax for 20 to 30 seconds, repeat 5 times [10,11]. In case of frequent episodes or atypical presentation of vasovagal syncope, studies had showed that electro-anatomic-mapping (EAM)-guided cardioneuroablation (CAN) strategy is feasible and safe in vasovagal

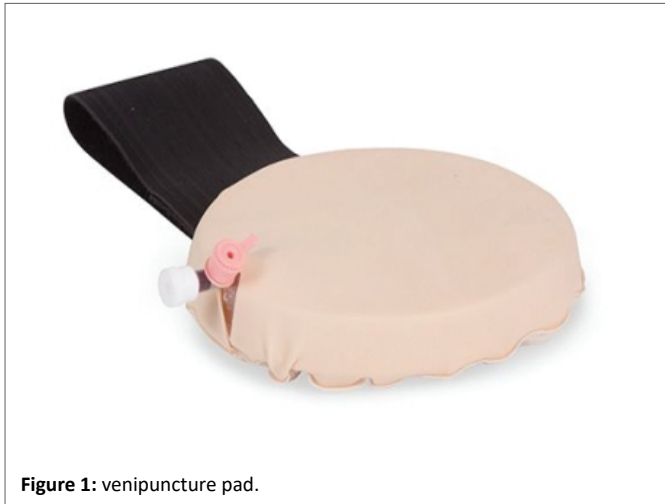

Figure 1: venipuncture pad.

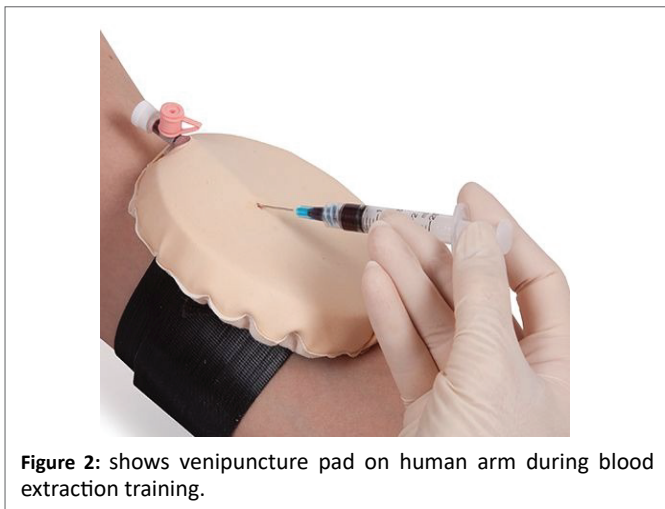


Figure 2: shows venipuncture pad on human arm during blood extraction training.

syncope especially for patients resistant to conventional therapies [12]. Our patient was seen by neurologist and diagnosed as typical infrequent vasovagal syncope and recommended conservative non medical therapy such as tension physical maneuver which didn't help our patient. The advantage of venepuncture pads is you can fix it on real patient arm, it has the real feeling of blood vessels morphology also the back flow of the blood like color solution during aspiration with the needle and syringe (Figure 2) simulated exactly real patient plus it is easy to perform, safe,

fun and inexpensive. Our patient got great benefit from training on venepuncture Pad and she was able to overcome vasovagal syncope due to blood and needle phobia. We would recommend such hands on exposure for patients with blood-needle phobia to prevent vasovagal syncope.

References

1. Kaufmann H (1997) Syncope. A neurologist's viewpoint. *Cardiol Clin* 15: 177-194.
2. Diehl RR, Linden D, Chalkiadaki A, Diehl A (1999) Cerebrovascular mechanisms in neurocardiogenic syncope with and without postural tachycardia syndrome. *J Auton Nerv Syst* 76: 159-166.
3. Weimer LH (1999) Autonomic function. In: Evans RW (Ed) *Diagnostic testing in neurology*. W.B. Saunders, Philadelphia, USA, 337-365.
4. Accurso V, Winnicki M, Shamsuzzaman AS, Wenzel A, Johnson AK, et al. (2001) Predisposition to vasovagal syncope in subjects with blood/injury phobia. *Circulation* 104: 903-907.
5. Han BI, Oh HJ, Bang OY, Lee JH (2006) Successful treatment of vasovagal syncope due to blood-injury phobia by physical maneuvering. *J Clin Neurol* 2: 66-69.
6. Tan MP, Duncan GW, Parry SW (2009) Head-up Tilt Table Testing: a state-of-the-art review. *Minerva Med* 100: 329-338.
7. Hagopian LP, Crockett JL, Keeney KM (2001) Multicomponent treatment for blood-injury-injection phobia in a young man with mental retardation. *Res Dev Disabil* 22: 141-149.
8. Brignole M, Alboni P, Benditt DG, Bergfeldt L, Blanc JJ, et al. (2004) Guidelines on management (diagnosis and treatment) of syncope-update 2004. Executive Summary. *Eur Heart J* 25: 2054-2072.
9. Hellström K, Fellenius J, Ost LG (1996) One versus five sessions of applied tension in the treatment of blood phobia. *Behav Res Ther* 34: 101-112.
10. Krediet CT, van Dijk N, Linzer M, van Lieshout JJ, Wieling W (2002) Management of vasovagal syncope: controlling or aborting faints by leg crossing and muscle tensing. *Circulation* 106: 1684-1689.
11. van Dijk N, de Bruin IG, Gisolf J, de Bruin-Bon HA, Linzer M, et al. (1985) Hemodynamic effects of leg crossing and skeletal muscle tensing during free standing in patients with vasovagal syncope. *J Appl Physiol* 98: 584-590.
12. Aksu T, Guler TE, Mutluer FO, Bozyel S, Golcuk SE, et al. (2018) Electroanatomic-mapping-guided cardioneuroablation versus combined approach for vasovagal syncope: a cross-sectional observational study. *J Interv Card Electrophysiol*.