

Immunotherapy for Advanced Small Cell Lung Cancer: A Case Report

Jinshuai Wang, Chaoxun Deng, Xuefeng Zhu, Xianjun Zou, and Jun Wang*

Department of Thoracic and Cardiovascular Surgery, Tongren People's Hospital, Guizhou Province, Tongren 554300, China

*Corresponding authors: Jun Wang, Department of Thoracic and Cardiovascular Surgery, Tongren People's Hospital, Guizhou Province, 120 Taoyuan Avenue, Bijiang District, Tongren 554300, China, Email: wangjun13398563110@163.com

Received: 08 Jul, 2021 | Accepted: 15 Sep, 2021 | Published: 23 Sep, 2021

Citation: Wang J, Deng C, Zhu X, Zou X, Wang J (2021) Immunotherapy for Advanced Small Cell Lung Cancer: A Case Report. J Clin Case Stu 6(5): dx.doi.org/10.16966/2471-4925.235

Copyright: © 2021 Wang J, et al. This is an open-access article distributed under the terms of the Creative Commons Attribution License, which permits unrestricted use, distribution, and reproduction in any medium, provided the original author and source are credited.

Abstract

In recent years, extraordinary achievements have been made in treating tumor immune checkpoints as targets, which significantly contributes to the research and development of novel immunologic drugs and their application in treating malignant tumors. However, few immunologic drugs can be administered to treat Small Cell Lung Cancer (SCLC). Currently, the focus of most clinical studies is placed on treating SCLC with a combination of immunotherapy and chemotherapy, which is relatively expensive and not covered by medical insurance, thus imposing a heavy economic burden on patients. Meanwhile, obvious adverse reactions occur during chemotherapy, which is still unacceptable to many patients and hence has not yet been widely adopted in clinical practice. Therefore, whether immunotherapy alone can help patients with SCLC, improve their quality of life, and prolong their survival time is a topic we will study in the future. In this case, an attempt was made to apply camrelizumab, an immunologic drug, in the treatment of SCLC in advanced stages, and a favorable efficacy was achieved.

Keywords: Camrelizumab; Immune checkpoint inhibitor (ICI); Immunotherapy; Small cell lung cancer (SCLC); Programmed death receptor-1/ligand 1 (PD-1/L1)

Introduction

Currently, immune checkpoint molecules mainly include Programmed Death Receptor 1 (PD-1)/Programmed Death Ligand 1 (PD-L1), and Cytotoxic T Lymphocyte Associated Antigen-4 (CTLA-4) [1-2]. Their corresponding ICIs, such as pembrolizumab, nivolumab, atezolizumab, and ipilimumab, have been applied in clinical practice and achieved remarkable results [3-4]. Meanwhile, the PD-1 inhibitor camrelizumab (AiRuiKa™) [5] independently developed by China has also been approved for marketing and application in the treatment of malignant tumors, with favorable anti-tumor activity shown in clinical trials for various malignant tumors [6], such as Esophageal Squamous Cell Carcinoma (ESCC), Hepatocellular Carcinoma (HCC), Nasopharyngeal Carcinoma (NPC), Non-Small Cell Lung Cancer (NSCLC), Gastric Cancer (GC), and Esophagogastric Junction Cancer (EGJC).

Camrelizumab is a selective, humanized, and high-affinity IgG4 monoclonal antibody [6], which can target and bind to PD-1 on the surface of CD4+ and CD8+ T cells, B lymphocytes, Natural Killer (NK) cells, Dendritic Cells (DCs), and other cells [7]. In addition, camrelizumab can block the interaction between PD-L1 on the surface of malignant tumor cells, Tumor Infiltrating Dendritic Cells (TIDCs), Tumor Infiltrating Lymphocytes (TILs), Antigen Presenting Cells (APCs), and other cells [8], and PD-L2 on the surface of activated macrophages and DC, relieve the immunosuppression of T cells mediated by the PD-1 pathway, further induce the activation of T lymphocytes on the surface of activated macrophages and DC,

reconstruct the immune system's capabilities to monitor and kill tumor cells, and ultimately achieve anti-tumor effects [9-11]. There are differences in the half maximum inhibitory concentrations (IC50) and the concentrations for 50% of maximum effect (EC50) between different PD-1 inhibitors. Commonly, lower IC50 and EC50 values of PD-1 inhibitors indicate a higher affinity for binding PD-1 and stronger anti-tumor effect [12]. The IC50 value of camrelizumab binding PD-1 is 0.7nmol/L, and the EC50 value is 0.38nmol/L, and its IC50 and EC50 values are similar to those of pembrolizumab; The IC50 values of toripalimab binding PD-L1 and PD-L2 are 3.0nmol/L and 3.1nmol/L, respectively. The EC50 value is 21nmol/L, which indicates that camrelizumab has a higher affinity for binding PD-1 and a stronger anti-tumor effect compared with toripalimab [13]. Moreover, it has been demonstrated in other studies [6] that after the first cycle (28d) of injection, the average occupancy rates of 60mg, 200mg, and 400mg of camrelizumab on PD-1 receptors are 81%, 85%, and 88%, respectively, which indicates that camrelizumab can achieve lasting anti-tumor effects.

The adverse reactions from camrelizumab are relatively mild, most of which are Grade I or Grade II in the phase I/II clinical trials for treating various malignant tumors, including Reactive Cutaneous Capillary Endothelial Proliferation (RCCEP) [14], fever [15], fatigue [16], hypothyroidism [16], proteinuria [5], coughing [5], anorexia and diarrhea [6], rash [6], etc. No obvious adverse reactions were observed in this patient, who only presented with slight anorexia during treatment, which luckily soon dissipated. In this case, an attempt was made to apply camrelizumab for treating advanced-stage SCLC, and a

favorable efficacy was ultimately achieved, which provides a reference for clinical trials of camrelizumab in treating advanced-stage SCLC.

Case Presentation

The patient, a 55-year-old female who weighed 54.30kg, came to our hospital on May 26, 2020 due to “Coughing and headaches for over 2 months, and chest pain for 3 days”. Since March 2020, this patient presented with coughing, headaches, and discomfort with no obvious causes, specifically manifesting paroxysmal irritating dry cough, with heavier signs in the morning and at night, which could be induced by fast speech; the headache mainly occurred on the left portion of the head and was characterized by the distending pain in most time, the moderate to severe pain degrees, the wandering type, and the duration of about 3 minutes, even through the night in severe cases. She took orally “Paracetamol” occasionally, but the efficacy was not favorable; there was no expectoration, hemoptysis, or other symptoms; on May 22, 2020, this patient developed chest pain and discomfort, with an obtuse pain in most time, which lasted for several seconds and would relieve without the need of treatment. After completing relevant examinations, the plain spiral CT scan and intensive pattern showed that (Figure 1): there may be lesions in the upper lobe of the left lung. The nature of multiple nodules in both lungs was not determined, and multiple mediastinal lymph nodes were enlarged. Fiberoptic bronchoscopy showed that there were lesions in the upper lobe of the left lung, and extrinsic deformities were detected in the opening of the lower lobe of the left lung, with the possibility of cancer. Biopsy samples under fiberoptic bronchoscopes indicated SCLC (Figure 2), and no abnormalities were found in the head CT, abdominal CT, or whole body nuclear medicine examination. As per the expressions of tumor markers for lung cancer, Neuron-Specific Enolase (NSE) was 33.65ng/ml, serum ferritin (SF) was 419.17ng/ml, and pro-gastrin-releasing peptide (ProGRP) was 722.52pg/ml. There were no abnormalities found in other blood related tests. According to the examination results, this patient was diagnosed with left primary bronchogenic carcinoma and SCLC stage VI (cT4N2M1a). On June 3, 2020, the first cycle of chemotherapy with “110mg of etoposide in D1-3+40mg nedaplatin in D1-3” was administered, with the interval between each chemotherapy cycle being 21 days. By July 26, 2020, a total of 3 cycles of chemotherapy were performed, and the lung CT showed that the tumor was significantly diminished (Figure 3). The

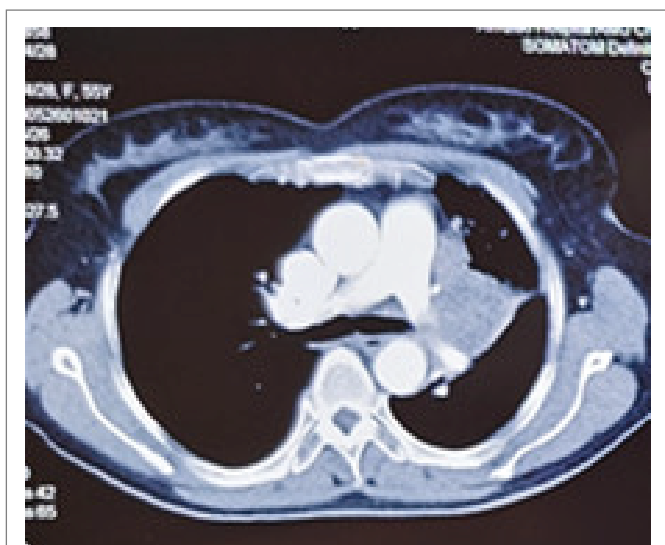


Figure 1: Mediastinal window before chemotherapy.

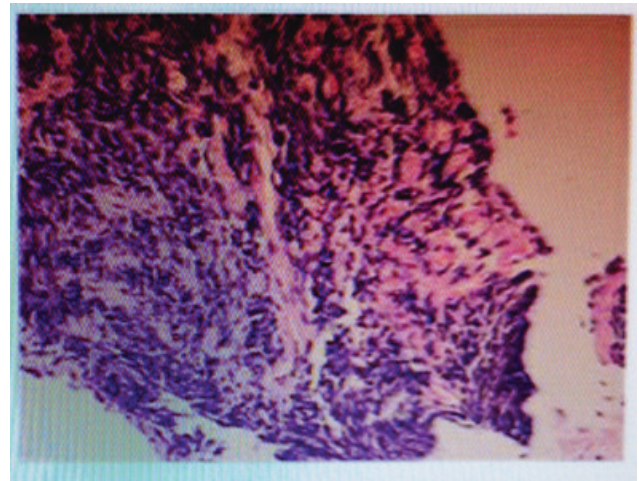

Figure 2: Pathological section.

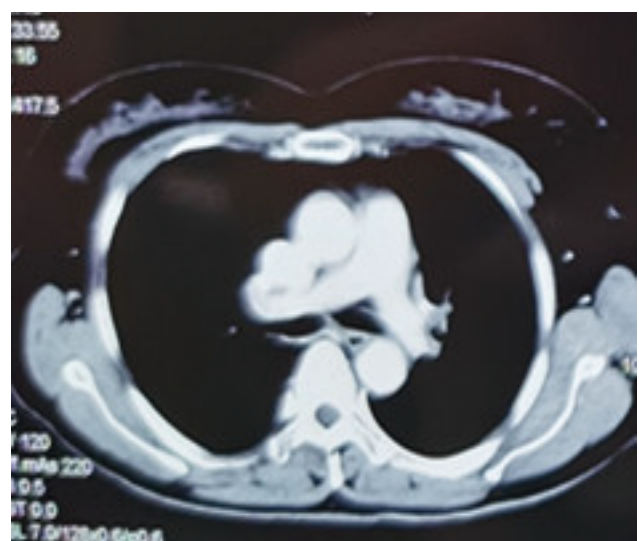


Figure 3: Mediastinal window after chemotherapy.

expressions of tumor markers for lung cancer, NSE was 14.00ng/ml, SF was 138.17ng/ml, and ProGRP was 71.13pg/ml. However, due to the severe side effects of chemotherapy and obvious liver function damage, anorexia, and weight dropped to 51.10kg, chemotherapy was stopped and hepatoprotection continued for up to 8 months. During the period, the patient did not follow the doctor’s advice and returned to the hospital for review.

After the hepatoprotective treatment, the patient’s liver function gradually recovered; however, due to symptoms of fatigue, anorexia, chest pain and headache, the patient visited our department on March 17, 2021, and received another lung CT scan (Figure 4). The results indicated that there were lumps in the hilum of the left lung, which had invaded the mediastinum and pericardium, partially wrapping around the thoracic aorta. Those manifestations were consistent with the central-type lung cancer with metastasis into the hilum of the lung and mediastinal lymph nodes, left pulmonary obstructive pneumonia, and left pleural effusion. According to the expression of tumor markers for lung cancer, NSE was 121.80ng/ml,

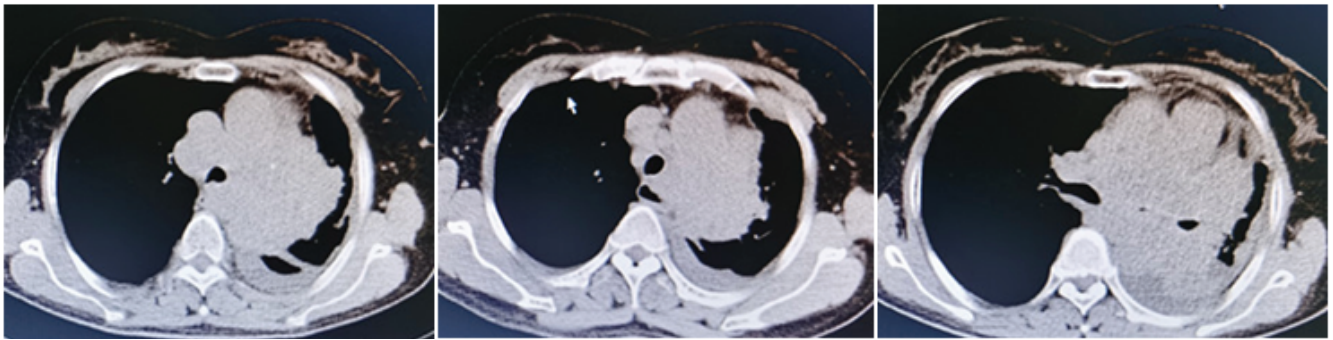


Figure 4: Mediastinal window before immunotherapy (recurrence).

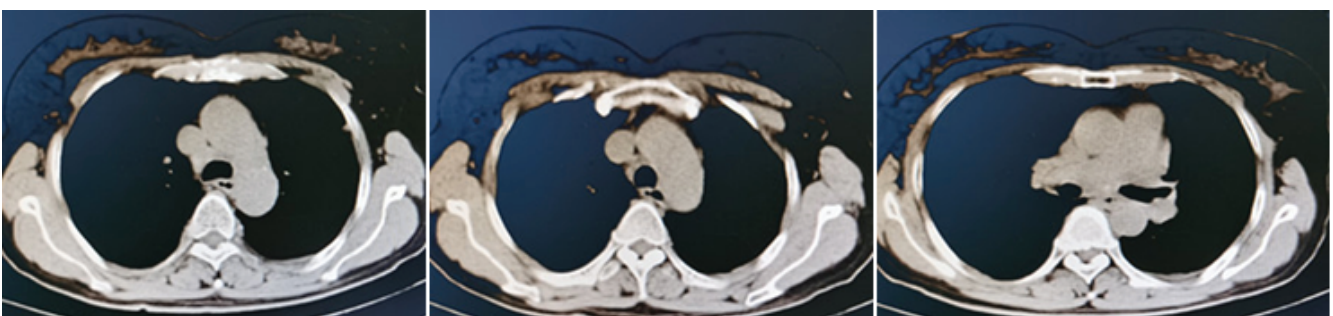


Figure 5: Mediastinal window after immunotherapy.

SF was 568.20ng/ml, and ProGRP was 9320.00pg/ml. At this time, her weight was 52.00kg. Due to the fact that this patient could not receive radiotherapy and chemotherapy, the patient's family members were informed that immunologic drugs for SCLC were in the clinical research stages and could not be employed in the clinical treatment yet, but the camrelizumab had been proven in some studies [6] to possess favorable anti-tumor activity in various malignant tumors with minor side effects, and it was relatively affordable. This drug could be used if there were no suitable treatment schemes for SCLC in the advanced stage. After being informed, this patient and her family members requested camrelizumab for immunotherapy. With a signed informed consent form and the approval by the hospital's ethics committee, immunotherapy was conducted. The first cycle of immunotherapy (200mg/time/cycle, every 21 days) was given on March 21, 2021. By June 9, 2021, three cycles of immunotherapy had been conducted, and chest pain, headaches, fatigue, and anorexia were completely relieved, and her weight returned to a healthy level (54.00kg). According to the lung CT, the tumor had disappeared (Figure 5). The expressions of tumor markers for lung cancer, NSE was 17.56ng/ml, SF was 124.30ng/ml, and ProGRP was 40.27pg/ml. Other physical examinations showed that all organs were functioning normally (Table 1). The next cycle of immunotherapy was planned, and a thorough medical follow-up would be conducted to obtain the future rehabilitation status of this patient.

Discussion and Conclusion

Over the past three decades, radiotherapy and chemotherapy have been the main treatments for patients with SCLC. Etoposide combined with cisplatin/carboplatin (EP/EC) has been the standard treatment scheme for extensive-stage SCLC. It was not until the breakthrough in immunotherapy that a new landscape of first-line treatment for SCLC

was formulated. The treatment of advanced-stage malignant tumors has moved from the era of chemotherapy and targeted therapy to the era of immune checkpoint inhibitors (ICIs) treatment. It has been revealed in the IMpower133 study [17] that the atezolizumab+EC treatment scheme could achieve favorable clinical outcomes when treating extensive-stage SCLC. Compared with EC chemotherapy alone, the death risk for patients treated with the atezolizumab+EC treatment scheme is reduced by 30%, and the survival time from immunotherapy is prolonged. 34.0% of patients survived for over 18 months, while only 21.0% of patients treated with the EC chemotherapy treatment scheme survived for over 18 months. No significant difference in the incidence of adverse reactions was observed between both treatment schemes. Therefore, China's National Medical Products Administration (NMPA) and many other countries have approved atezolizumab combined with chemotherapy to be employed as first-line treatment for advanced-stage SCLC. It has been demonstrated in the CASPIAN study [18] that durvalumab combined with chemotherapy can reduce the risk of death by 27%. The Objective Remission Rate (ORR) of the chemotherapy-alone group was 57.6%, while that of the durvalumab combined with chemotherapy group was 67.9%, with an increase of 10.3%. The 18-month survival rates of patients in the durvalumab combined with chemotherapy group and the chemotherapy alone group were 33.9% and 24.7%, respectively. Pembrolizumab and nivolumab, two other PD-1 monoclonal antibodies, have also received clinical trials in combination with chemotherapy for first-line treatment of extensive-stage SCLC. However, there have been no convincing results yet [19], and a study on immunotherapy alone for SCLC has not yet been conducted.

Although a breakthrough has been made in immunotherapy of small cell lung cancer, the focus of most clinical studies is placed on treating

Table 1: Comparison of test value before and after treatment.

Value or time	White blood cell ($1 \times 10^9/L$)	Red blood cell ($1 \times 10^{12}/L$)	Platelets ($1 \times 10^9/L$)	ALT (U/L)	AST (U/L)	Prealbumin (g/L)	Creatinine ($\mu\text{mol}/L$)	Primary tumor (cm)	Mediastinal lymph nodes size (cm)	Organ metastasis
Before chemotherapy	6.0	4.0	193	38.9	27.8	244	54.2	5.7 × 4.3	2.3 × 2.5	no
After chemotherapy	2.6	3.7	121	233.6	152.7	195	52.9	2.1 × 0.7	1.2 × 1.4	no
Before immunotherapy	5.4	4.7	171	56.9	61.6	234	62.2	7.2 × 4.4	2.6 × 3.1	no
After immunotherapy	4.5	4.3	118	57.9	44.0	256	50.4	0.6 × 0.5	1.1 × 0.9	no

SCLC with a combination of immunotherapy and chemotherapy, which is relatively expensive and not covered by medical insurance, thus imposing a heavy economic burden on patients. Meanwhile, there would be obvious adverse reactions during chemotherapy, which is still unacceptable to many patients and hence has not yet been widely adopted in clinical practice. Therefore, whether immunotherapy alone can benefit patients with SCLC, improve their quality of life, and prolong their survival time is a topic we will study in the future.

In this case, we used the PD-1 inhibitor camrelizumab to treat recurrent small cell lung cancer. After 3 cycles of immunotherapy, the patient's symptoms were completely relieved, and there was no obvious adverse reaction. Re-examination of lung CT indicated that the tumor disappeared. Therefore, we infer that some small cell lung cancer is highly sensitive to camrelizumab, and it is likely that this part of small cell lung cancer patients will be cured. Unfortunately, this patient did not agree to genetic testing. We cannot know the PD-1 expression of this patient, so we cannot assess whether the sensitivity of small cell lung cancer to camrelizumab is related to the degree of PD-1 expression, and the correlation how, further clinical research is needed to explore.

References

- Yuan Y, Wei YF, Gao WW (2018) Programmed cell death receptor 1 inhibitor nivolumab advances in the treatment of lung cancer. *J Xinxiang Med Univ* 35: 943-948.
- Zhao PY, Du XH (2019) Advances in combined immunotherapy for sepsis. *Med J Chin PLA* 44: 434-439.
- Rotte A (2019) Combination of CTLA-4 and PD-1 blockers for treatment of cancer. *J Exp Clin Cancer Res* 38: 255.
- Baraibar I, Melero I, Ponz-Sarvisé M, Castanon E (2019) Safety and tolerability of immune checkpoint inhibitors (PD-1 and PD-L1) in cancer. *Drug Saf* 42: 281-294.
- Markham A, Keam SJ (2019) Camrelizumab: first global approval. *Drugs* 79: 1355-1361.
- Mo HN, Huang J, Xu JC, Chen X, Wu D, et al. (2018) Safety, anti-tumour activity, and pharmacokinetics of fixed-dose SHR-1210, an anti-PD-1 antibody in advanced solid tumours: a dose-escalation, phase 1 study. *Br J Cancer* 119: 538-545.
- Wu X, Gu Z, Chen Y, Chen B, Chen W, et al. (2019) Application of PD-1 blockade in cancer immunotherapy. *Comput Struct Biotechnol J* 17: 661-674.
- Wu Y, Chen W, Xu ZP, Gu W (2019) PD-L1 distribution and perspective for cancer immunotherapy-blockade, knockdown, or inhibition. *Front Immunol* 10: 2022.
- Guzik K, Tomala M, Muszak D, Konieczny M, Hec A, et al. (2019) Development of the inhibitors that target the PD-1/PD-L1 interaction-A brief look at progress on small molecules, peptides and macrocycles. *Molecules* 24: E2071.
- Nowicki TS, Hu-Lieskovan S, Ribas A (2018) Mechanisms of resistance to PD-1 and PD-L1 blockade. *Cancer J* 24: 47-53.
- Alsaab HO, Sau S, Alzhrani R, Tatiparti K, Bhise K, et al. (2017) PD-1 and PD-L1 checkpoint signaling inhibition for cancer immunotherapy: mechanism, combinations, and clinical outcome. *Front Pharmacol* 8: 561.
- Luo XC, Li GF (2020) Application of PD-1 inhibitor Camrelizumab in advanced malignancies. *Med J Chin PLA* 45: 672-679.
- Fu J, Wang F, Dong LH, Zhang J, Deng CL, et al. (2017) Preclinical evaluation of the efficacy, pharmacokinetics and immunogenicity of JS001, a programmed cell death protein-1 (PD-1) monoclonal antibody. *Acta Pharmacol Sin* 38: 710-718.
- Nie J, Wang CM, Liu Y, Yang Q, Mei Q, et al. (2019) Addition of low-dose decitabine to anti-PD-1 antibody camrelizumab in relapsed/refractory classical Hodgkin lymphoma. *J Clin Oncol* 37: 1479-1489.
- Song Y, Wu J, Chen X, Lin T, Cao J, et al. (2019) A single-arm, multicenter, phase II study of camrelizumab in relapsed or refractory classical Hodgkin lymphoma. *Clin Cancer Res* 25: 7363-7369.
- Fang W, Yang Y, Ma Y, Hong S, Lin L, et al. (2018) Camrelizumab (SHR-1210) alone or in combination with gemcitabine plus cisplatin for nasopharyngeal carcinoma: results from two single-arm, phase I trials. *Lancet Oncol* 19: 1338-1350.
- Horn L, Mansfield AS, Szczesna A, Havel L, Krzakowski M, et al. (2018) First-line atezolizumab plus chemotherapy in extensive-stage small-cell lung cancer. *N Engl J Med* 379: 2220-2229.
- Paz-Ares L, Dvorkin M, Chen Y, Reinmuth N, Hotta K, et al. (2019) Durvalumab plus platinum-etoposide versus platinum-etoposide in first-line treatment of extensive-stage small-cell lung cancer (CASPIAN): a randomised, controlled, open-label, phase 3 trial. *Lancet* 394: 1929-1939.
- Rudin CM, Awad MM, Navarro A, Gottfried M, Peters S, et al. (2020) Pembrolizumab or Placebo Plus Etoposide and Platinum as First-Line Therapy for Extensive-Stage Small-Cell Lung Cancer: Randomized, Double-Blind, Phase III KEYNOTE-604 Study. *J Clin Oncol* 38: 2369-2379.