

Periorbital Rejuvenation: Ablative Full Field Er:Yagvs. Fractional Er:Yag Laser Resurfacing

Robert Bowen*

Associate Professor, West Virginia University School of Medicine, Martinsburg, West Virginia, USA

*Corresponding author: Robert Bowen, Associate Professor, West Virginia University School of Medicine, Martinsburg, West Virginia, USA, E-mail: rbowen3710@msn.com

Received date: 25 Nov 2016; Accepted date: 06 Jan 2017; Published date: 11 Jan 2017.

Citation: Bowen R (2017) Periorbital Rejuvenation: Ablative Full Field Er:Yagvs. Fractional Er:Yag Laser Resurfacing. J Clin Cosmet Dermatol 1(1): doi <http://dx.doi.org/10.16966/2576-2826.108>

Copyright: © 2017 Bowen R. This is an open-access article distributed under the terms of the Creative Commons Attribution License, which permits unrestricted use, distribution, and reproduction in any medium, provided the original author and source are credited.

Abstract

Laxity and wrinkles of the lower eyelid skin are common manifestations of photoaging. They often appear earlier on the eyelids than on adjacent facial skin. The pulsed CO₂ laser has been shown to tighten loose skin and reduce wrinkles in the periorbital region. Previous studies suggested that the improvements were due to tissue-heating effects that vaporized intracellular water and ablated upper-layer tissue, denatured underlying tissue, and induced collagen shrinkage in lower layers. Post treatment skin tightening was attributed to new collagen synthesis in the lower layers as the treated tissue healed.

Adverse effects of pulsed CO₂ laser treatment include edema, persistent erythema, burning, crusting, late or permanent hypopigmentation, hyperpigmentation, prolonged recovery time, acne flares, scars, herpes simplex virus infection, ectropion/scleral show, dermatitis, and milia development. The severity of these effects may be reduced if treatment is limited to a single pass. This investigation examines the hypothesis that fractional ErYag laser treatment of the periorbital region is safe and efficacious compared to full field treatment.

Improvements in wrinkle scores were both clinically and statistically significant by both techniques. Five of seven periorbital areas were improved by more than 1.8 Fitzpatrick grades for each of the techniques. Adverse effects were limited to edema and erythema/flaking, both of which resolved significantly more rapidly with the fractional technique. Pain scores between the two techniques did not differ significantly.

Keywords: Periorbital; Hyperpigmentation; Photoaging

Introduction

Laxity and wrinkles of the lower eyelid skin are common manifestations of photoaging. They often appear earlier on the eyelids than on adjacent facial skin. The pulsed CO₂ laser has been shown to tighten loose skin and reduce wrinkles in the periorbital region [1]. The authors of this study suggested that the improvements were due to tissue-heating effects that vaporized intracellular water and ablated upper-layer tissue, denatured underlying tissue, and induced collagen shrinkage in lower layers. Post treatment skin tightening was attributed to new collagen synthesis in the lower layers as the treated tissue healed.

Adverse effects of pulsed CO₂ laser treatment, include edema, persistent erythema, burning, crusting, late or permanent hypopigmentation, hyperpigmentation, prolonged recovery time, acne flares, scars, herpes simplex virus infection, ectropion/scleral show, dermatitis, and milia development [2-6]. The severity of these effects may be reduced if treatment is limited to a single pass [7].

This investigation examines the hypothesis that fractional ErYag laser treatment of the periorbital region is safe and efficacious compared to full field treatment.

The Erbium:YAG laser

The erbium yttrium aluminium garnet (Er:YAG) laser (Sciton, Palo Alto, CA) has been used as an alternative to the CO₂ laser [6]. Khatri and colleagues [3] showed that Er:YAG laser-induced improvement in rhytids was comparable to that achieved with CO₂ laser resurfacing, and that healing time, redness, swelling, and the incidence of late hypopigmentation were reduced but with reduced thermally induced collagen tightening after Er:YAG treatment compared to CO₂ treatment [8,9].

The reduced adverse effects associated with Er:YAG resurfacing may be understood from the following considerations. Although the Er:YAG and CO₂ lasers both target water as a skin chromophore [10], the ablative and thermal effects of the two devices are different. The difference is attributed to the 10-fold greater absorption by water of the Er:YAG laser's 2940 nm energy compared to the CO₂ laser's 10,600 nm energy (Figure 1).

Since the 2940 nm absorption efficiency is so high, nearly all the 2940 nm energy is consumed during ablation, so minimal energy is left for a necrotic effect on the underlying tissue. This is in contrast to CO₂ laser treatment in which, because absorption of the 10,600 nm energy by water is less efficient, more heat is left over after ablation. The result is a larger zone of irreversible thermal necrosis (50-100 microns) [11] underneath the ablated area [5].

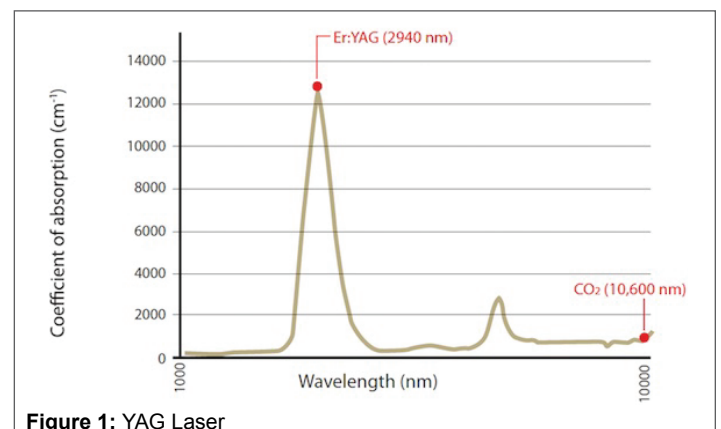


Figure 1: YAG Laser

Variable pulse: The next step was the development of variable pulse Er:YAG laser technology, which allows the physician to vary the pulse duration so that pulses ranging from purely ablative (short pulse duration) to more thermal (long pulse duration) are available [11]. The energy delivery mechanism is shown in figure 2.

Early studies [11-14] showed that variable pulse Er:YAG treatment reduces the duration of post-treatment crusting and decreases erythema compared with a CO₂ laser. Permanent hypopigmentation, hyperpigmentation, and scarring were not observed, and improvement in rhytids approached that of the CO₂ laser (48% vs. 63%).

Modulation: Modulated systems offer both ablation and coagulation capabilities. This dual mode (Sciton, Palo Alto, CA) includes two Er:YAG heads, one for short- pulse ablative applications and the other for long-pulse coagulative applications. The dual mode treatment induces controlled thermal desiccation by optical multiplexing, a process in which individual pulses are stacked together to produce short, ablative pulses of high fluence or coagulative micropulses of low fluence. The most recent version of this laser is the tunable resurfacing laser, a full-field device that offers independent control over the depth of ablation and coagulation. This capability allows the user to control the depth of ablation with or without coagulation, permitting the physician to tailor the tissue effect to the specific needs of each patient.

Fractional: The development of fractional photothermolysis addressed the preferences of patients for minimal downtime and risk. Nonablative fractional photothermolysis has been introduced by Manstein et al. [6] and reviewed by Geronemus [8]. These lasers produce arrays of tiny thermal wounds at specific depths in the skin without damaging the surrounding tissue. Downtime is reduced and healing is rapid, but multiple treatments are required. The development of ablative fractional lasers (Er:YAG and CO₂) addressed the need for increased efficacy and fewer treatments. The device employed in this study uses an Er:YAG laser, a 250 or 430 micron spot size and treatment density (the number of wounds per unit area of skin) which can be varied from 1.5% to 30%, with or without depth-selectable tissue coagulation during treatment.

Methods

The protocol was reviewed and approved by the local committee for human subjects. Eight consecutive patients presenting for facial rejuvenation were offered the option of participating in the study and receiving an additional lower eyelid rejuvenation procedure at no cost. None had been treated by other periorbital rejuvenation methods (e.g., botulinum toxin, fillers) or had undergone a pretreatment topical regimen or antibiotic prophylaxis. Patients were given antiviral medication (valacyclovir), 1 gram just before the procedure and once daily for 3 days after the procedure. Pretreatment anesthesia consisted of a mixture of lidocaine (7%), prilocaine (7%), and phenylephrine ointment applied to the periorbital areas without occlusion for 1 hour. Proparacaine

ophthalmic solution and artificial tears were added to the eyes and internal eye shields were inserted to permit treatment up to the eyelash margins. After removing anesthetic ointment, all periorbital areas were treated with a 10-micron “micro peel”, and then a thin layer of the anesthetic ointment was reapplied only to the periorbital areas for 10 minutes, to achieve a denser anesthetic effect. Limiting the “double topical” application to the periorbital area minimized the potential for lidocaine toxicity.

The anesthesia ointment was removed, and then one randomly selected periorbital area of each patient was treated with the full-field and the other with the fractional. Chilled air from a Zimmer cooler minimized patient discomfort on both sides during the treatment. Settings for the full field were the following: first pass, 50 microns ablation depth, and second pass, 50 microns ablation depth and 50 microns coagulation. For the fractional treatment, patients received three passes at 100 microns ablation depth, level 3 coagulation (the highest setting), and 11% treatment density. Settings for the fractional device were selected on the basis of clinical experience and histologic data (Figure 3) of eyelid skin treated with different combinations of ablation depth and coagulation. Post-treatment care was limited to a 48-hour application of petroleum jelly without ice or anti-inflammatory drugs.

Patients evaluated pain on a 10-point scale in which 1=no pain and 10=intolerable pain. Improvements in periorbital wrinkles were assessed independently by comparison of clinical photographs obtained before and 4 months after treatment under identical conditions of lighting and position. Evaluators used a nine-point scale and sample clinical photographs obtained from Fitzpatrick and colleagues [1] to evaluate improvements in patients of this study. Scores 1 to 3, 4 to 6, and 7 to 9 corresponded to the mild, moderate, and severe elastosis, respectively. An example of a four-part photograph sent to the blinded evaluators is shown in figure 4. Differences in pre- and post treatment wrinkle scores were tested for significance by a paired t-test using P<0.05 as the cutoff value.

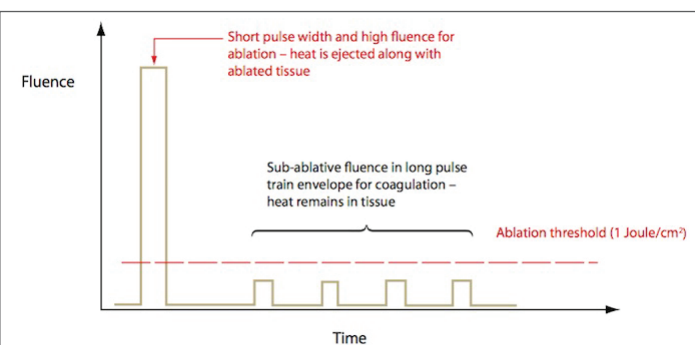


Figure 2: YAG Treatment

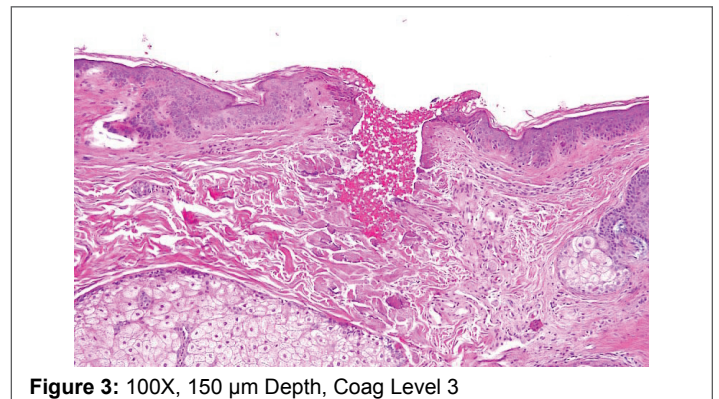


Figure 3: 100X, 150 µm Depth, Coag Level 3

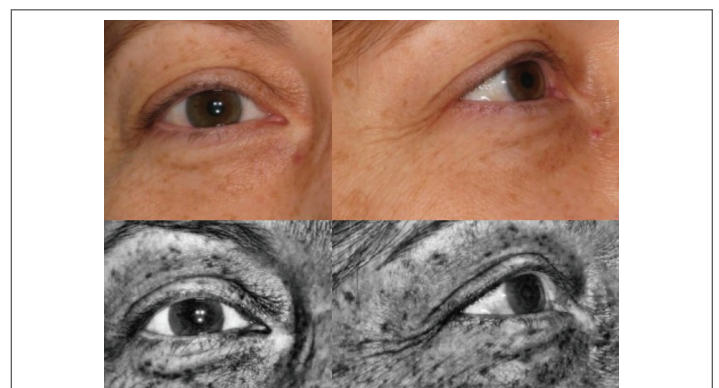

Figure 4: Example of Images Provided to Blinded Observers Including Normal and Enhanced Color

Evaluators were five experienced physicians without knowledge of when photographs were taken (before or after treatment or which technique had been used). Evaluator specialties included cosmetic dermatology (2), aesthetic medicine (1), plastic surgery (1), and obstetrics-gynecology (1).

Results

Seven patients completed the study. The eighth was lost to follow-up. Mean wrinkle scores, resolution times for post-treatment edema and erythema, and pain scores are presented in table 1.

Improvements in wrinkle scores were both clinically and statistically significant by both techniques (Table 1). Five of seven periorbital areas improved by more than 1.8 Fitzpatrick grades for each of the techniques. Adverse effects were limited to edema and erythema/flaking, both of which resolved significantly more rapidly (table 2) with the fractional technique. Pain scores between the two techniques did not differ significantly.

Discussion and Summary

The results of this study show that a single treatment with the fractional laser device significantly reduces Fitzpatrick wrinkle scores of the periorbital area, improvement is comparable to that obtained with the full-field treatment, and the times for resolution of post-treatment edema and erythema/flaking are significantly less with the fractional device. Pain scores did not differ significantly with the two techniques. For the full-field technique, the difference between the pre- and post-treatment mean wrinkle scores ($5.7-3.4=2.3$) at 4 months compares well with the corresponding difference (2.25) for the full-field pulsed CO₂ laser with a mean 74-day follow up [1]. In the study of Fitzpatrick and colleagues [1], clinical healing of the skin required “1 to 2 weeks,” and post-treatment erythema persisted an additional 2 to 16 weeks (most frequently 1 month after reepithelialization), longer than the 2 to 8 and 4 to 18 days with the dual mode erbium fractional and dual mode full field, respectively, of this study (Table 1). Kotlus [15] and Brightman and colleagues [16] treated the periorbital areas of 15 and 20 patients, respectively, with a fractional CO₂ laser. Koltus [15] reported a 21-day mean duration of post-treatment erythema and Brightman and colleagues [16] reported a 3 to 21-day resolution time for edema, erythema, and dryness.

As a result of this study, the author now selects a periorbital rejuvenation technique on the basis of the patient’s requirements for downtime. For example, if the patient has 7 to 10 days to recover, the author suggests full-field dual mode ablation because this technique provides the most predictable single-treatment results. If the patient has only 3 to 4 days to recover, the author would choose the dual mode fractional because it provides excellent results in an initial treatment and enhanced benefits with a second treatment 3 to 6 weeks later. The author’s current first-line protocol for lower eyelids (as part of a standard full-face fractional

treatment) calls for the fractional settings used in this study (3 passes at 100 microns ablation depth, level 3 coagulation, and 11% treatment density). The author has also used the fractional technique to treat patients (notably men) with thicker eyelid skin by increasing the depth by 50 to 75 microns without an increase in complications.

The encouraging results of this study justify additional investigations to more precisely establish the treatment parameters of both devices to further optimize patient outcomes.

Clinical examples

Clinical examples were shown in figures 5-7.

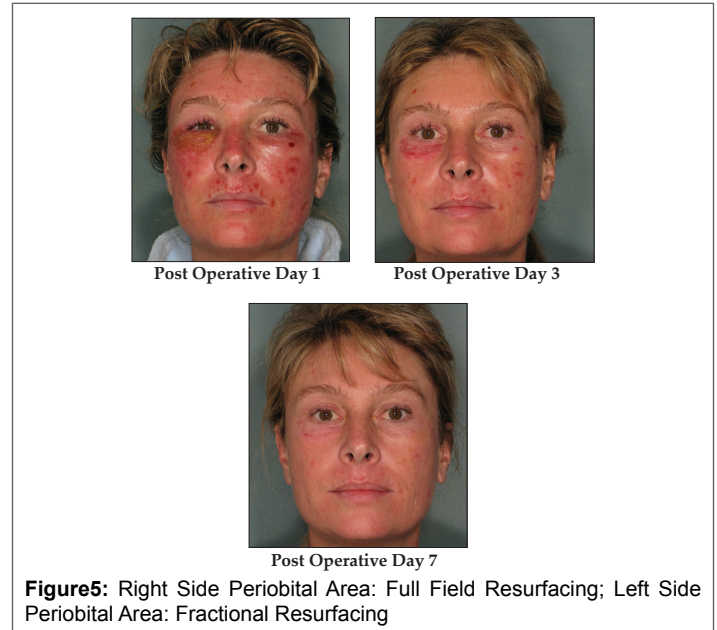

Figure 5: Right Side Periorbital Area: Full Field Resurfacing; Left Side Periorbital Area: Fractional Resurfacing

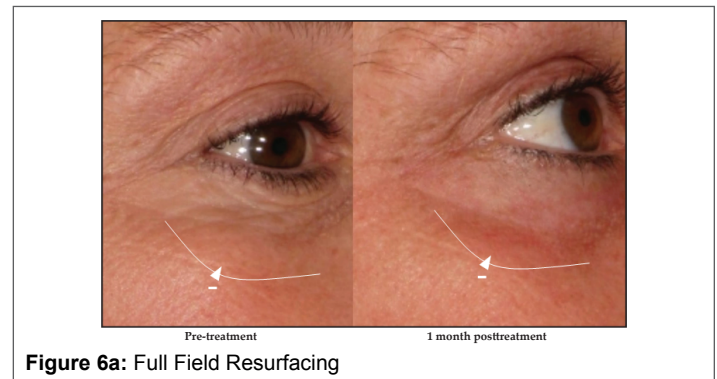


Figure 6a: Full Field Resurfacing

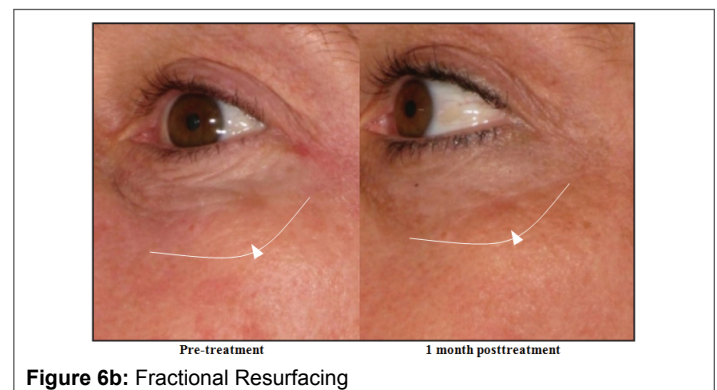


Figure 6b: Fractional Resurfacing

Treatment Device	Wrinkle Score		
	Before Treatment	After Treatment	P Value
Full Field	5.7 ± 1.5	3.4 ± 0.9	0.004 (s)
Fractional	5.8 ± 1.4	3.9 ± 1.5	0.018 (s)

Table 1: Improvements in wrinkle score before and after treatment (mean ± SD) s=significant.

Parameter	Full Field	Fractional	P Value
Edema	6.4 ± 2.9	4.4 ± 1.8	0.03 (s)
Erythema/flaking	11.2 ± 3.6	4.9 ± 1.6	0.002 (s)
Pain	4.0 ± 2.4	4.5 ± 2.8	0.35 (ns)

Table 2: Comparative resolution times (days) and pain scores (mean ± SD) s=significant; ns=not significant

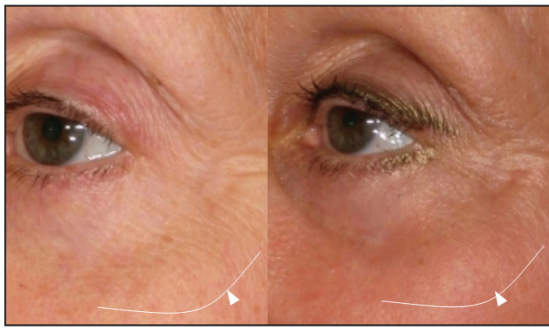


Figure 7a: Full Field Resurfacing

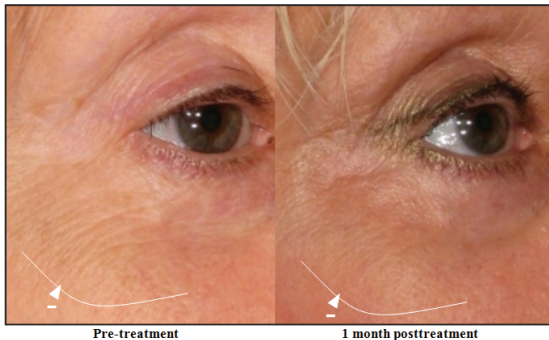

Figure 7b: Fractional Resurfacing

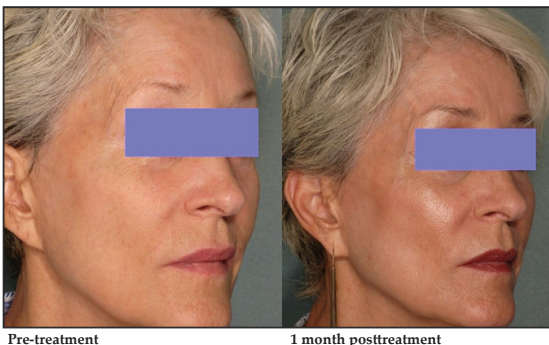

Figure 7c: Full Face

Conclusion

A single treatment with either the full-field or the fractional laser device significantly improves wrinkles of the periorbital area. Adverse effects are limited to edema and erythema/flaking. Recovery time (duration of edema and erythema) of the treatment is reduced with the fractional technique compared to full field treatment.

Acknowledgement

The author wishes to thank Deborah Davis, MD, Sydney, Australia; Donald Kress, MD, Fredrick, Maryland; Michael Lin, MD, Los Angeles,

CA, Sarah Bowen-Pasfield, MD, Morgantown, WV; Michael Grove, MD Martinsburg, WV; and Rachel Gordon, MD, Pittsburgh, PA for participating in this study.

References

1. Fitzpatrick RE, Goldman MP, Satur NM, Tope WD (1996) Pulsed carbon dioxide laser resurfacing of photoaged facial skin. *Arch Dermatol* 132: 395-402.
2. Nanni CA, Alster TS (1998) Complications of carbon dioxide laser resurfacing. An evaluation of 500 patients. *Dermatol Surg* 24: 315-320.
3. Khatri K, Sultan F, Anderson R (1998) Patients views of comparison of Erbium:YAG and CO₂ laser resurfacing. *Lasers Surg Med* 10: 76.
4. Bernstein LJ, Kauvar AN, Grossman MC, Geronemus RG (1997) The short and long term side effects of carbon dioxide laser resurfacing. *Dermatol Surg* 23: 519-525.
5. Fleming D (1999) Controversies in skin resurfacing: the role of erbium. *J Cutan Laser Surg* 1: 15-21.
6. Manstein D, Heron GS, Sink RK, Tanner H, Anderson RR (2004) Fractional photothermolysis: A new concept for cutaneous remodeling using microscopic patterns of thermal injury. *Lasers Surg Med* 34: 426-438.
7. Alster T, Hirsch R (2003) Single-pass CO₂ laser skin resurfacing if light and dark skin: extended experience with 52 patients. *J Cosmet Laser Ther* 5: 39-42.
8. Geronemus RG (2006) Fractional photothermolysis: current and future applications. *Lasers Surg Med* 38: 169-176.
9. Hughes PS (1998) Skin contraction following Erbium: YAG laser resurfacing. *Dermatol Surg* 24: 109-111.
10. Alster TS (1999) Clinical and histologic evaluation of six Erbium: YAG lasers for cutaneous resurfacing. *Laser Surg Med* 24: 87-92.
11. Newman JB, Lord JL, Ash K, McDaniel DH (2000) Variable pulse Erbium:YAG laser skin resurfacing of perioral rhytids and side-by-side comparison with carbon dioxide laser. *Lasers Surg Med* 26: 208-214.
12. Khatri KA, Ross V, Grevelink JM, Magro CM, Anderson RR (1999) Comparison of erbium:YAG and carbon dioxide lasers in resurfacing of facial rhytides. *Arch Dermatol* 135: 391- 397.
13. Zachary CB (2000) Modulating the Er: YAG laser. *Lasers Surg Med* 26: 223-226.
14. Clementoni MT, Gilardino P, Muti GF, Beretta D, Schianchi R (2007) Non-sequential fractional ultrapulsed CO₂ resurfacing of photoaged facial skin: preliminary clinical report. *J Cosmet Laser Ther* 9: 218-225.
15. Kotlus B (2009) Eyelid and periorbital rejuvenation with deep fractional CO₂ resurfacing. *Lasers Surg Med* 21: 527.
16. Brightman L, Chapas A, Hunzeker C, Weiss E, Karen J, et al. (2009) Blepharoplasty-like results with periorbital fractional CO₂ laser. *Lasers Surg Med* 21: 77.