

Chinese Medicine in the Treatment of Systemic Multiple Strawberry-like Infectious Granuloma: A Case Report

Yipeng Song^{1*}, Yan Liu^{2#}, Lei Sun³ and Zhaopu Song^{4*}

¹Shaanxi university of Chinese Medicine, Xian, China

²Institute of Basic Research in Clinical Medicine, China Academy of Chinese Medical Sciences, Beijing, China

³Department of pathology, Ditan Hospital, Capital Medical University, Beijing, China

⁴RuZhou JinGeng Hospital, Henan, China

[#]Co-first authors on this work

*Corresponding author: Prof. Zhaopu Song, RuZhou JinGeng Hospital, Henan, China, Tel: 86-375-6891888; Fax: 86-375-6866888; E-mail: zhaopsong@126.com

Received date: 21 April, 2015; Accepted date: 13 May, 2015; Published date: 19 May, 2015.

Citation: Song Y, Liu Y, Sun L, Song Z (2015) Chinese Medicine in the Treatment of Systemic Multiple Strawberry-like Infectious Granuloma: A Case Report. Clin Res Open Access 1(1): doi <http://dx.doi.org/10.16966/2469-6714.101>

Copyright: ©2015 Song Y et al. This is an open-access article distributed under the terms of the Creative Commons Attribution License, which permits unrestricted use, distribution, and reproduction in any medium, provided the original author and source are credited.

Abstract

Introduction: infectious granuloma is a form of focal inflammation which occurs around various infectious agents. For unusual or rare cause, however, exploring the etiology of disease usually take several months. The clinical practice of Chinese medicine may provide a timely and effective treatment.

Case Presentation: The case reported followed is a 46 years male who diagnosed with an unusual cause of infectious granuloma. The symptoms at this visit manifested as strawberry-like granuloma (dark red). The lesions were mainly in the lower part of the face. These lesions had been clustering fusion, no pus-spill, soft handle and no tenderness. The therapeutic principles were dispel-wind and dry dampness, heat-clearing and detoxify. The patient was treated by herbal medicine during 26 days. The subsequent follow-up of patient showed that the collapsed lesions only remained the dark brown hyperpigmentation. In addition, the criteria for the quality of the herbs we used were in accordance with the Chinese pharmacopoeia (2005 edition).

Conclusion: this case report indicated the effect of Chinese herbal medicine in treating a case of rare skin disease, and provided evidence into clinical practice of dermatitis. However, further studies involving larger patient numbers are required in order to allow a final conclusion on the effect and mechanisms of this form of treatment.

Introduction

Strawberry-like infectious granulomatous are rare in a wide variety of diseases [1]. The identification of cause or causes can be helpful for clinical diagnosis and treatment of disease. However, exploring the etiology usually took a long time, sometimes many months [2,3]. Furthermore, cause of infectious granulomatous is often unknown. In resource-limited settings, such as rural areas of China, where the laboratory capacity was often insufficient, the clinical practice of Chinese medicine may provide a timely and effective treatment. A representative case is reported as follows.

Case presentation

A 46-year shepherd man, was admitted to RuZhou JinGeng Hospital on August 25, 2012. The prominent complaints were suffering from systemic multiple strawberry-like granuloma in the last one month.

The patient was aware of the limitation of mouth opening about a month ago without obvious inducement. After two days the skin surface appeared many strawberry-like dark red granuloma on the face. The symptoms at this visit manifested as systemic multiple strawberry-like granuloma. The lesions were mainly in the lower part of the face (Figure 1A). These lesions had been clustering fusion, no pus-spill, soft handle and no tenderness. The lesions on the chest, abdomen and back had slightly smaller than on the face, some of which had ruptured and produced bright red ulcers; the lesions on the both lower extremities scattered distribution and had also ruptured.

The patient's description: a history of neurodermatitis for more than 20 years; no history of chronic disease, infectious disease and allergic disease; no history of surgery and trauma; no history of blood transfusion, blood donation and patient's father died of a skin cancer last year.

Chinese medical diagnosis was dermatitis of damp-heat accumulation pattern. The therapeutic principles were dispel-wind and dry dampness, heat-clearing and detoxify (祛风燥湿, 清热解毒). Prescription: *Campanumaea Pilosula* 30 g, *Astragalus Propinquus* 30 g, *Cortex Phellodendri* 10 g, *Scutellariae Barbatae* 30 g, *Chinese Lobelia* 30 g, *Hedyotis Diffusa* 60 g, *Rhizoma Bolbostemmae* 15 g, *Rhizoma Smilacis Glabrae* 30 g, *Schizonepeta* 15 g, *Radices Sileris* 10 g, *Glycyrrhiza* 6 g and *Dandelion* 30 g. In hospital, a trained technician prepared the decoction according to a standardized procedure (add herbs to cold water and bring the mixture to a gentle boil; keep covered and simmer for approximately 20 minutes); each unit of formula yielded 200 mL of decoction, which were then administered orally once a day.

The next visit took place on August 30, 2012. Although the lesions on the face had smaller than before, they had still been clustering fusion (Figure 1B). Prescription: modify the previous recipe by adding *Notopterygium* 10 g, *Radix Curcumae* 15 g, *Radix Ophiopogonis* 15 g and *Folium Mori* 15 g, taking one does daily for 10 days continuously.

The third visit was on September 9, 2012. Systemic lesions had shrunk peanut-sized lesions besides on the mandible (Figure 1C). Prescription: the previous recipe took one does daily for 10 days continuously.

The forth visit was on September 20, 2012. The lesions had collapsed on his face; at last, the patient had left niblet-sized lesions. The collapsed lesions changed to dark brown (Figure 1D). We suggested that the patient should continue taking the previous drugs.

Nearly 3 months after the forth visit, we conducted a follow-up interview at patient's home. The collapsed lesions remained the dark brown hyperpigmentation and no obvious tenderness (Figure 1E). No concomitant therapies were used during the follow-ups.

Discussion

The mechanism of Chinese medicine in the treatment of dermatosis is complex. In this prescription, *Schizonepeta*, *Radices Sileris*, and *Notopterygium* play an action of dispel-wind and dry dampness, *Cortex Phellodendri* is for heat-clearing and dry dampness, *Scutellariae Barbatae*, *Chinese Lobelia*, *Hedyotis Diffusa*, *Rhizoma Bolbostemmae*, *Rhizoma Smilacis Glabrae*, *Glycyrrhiza*, and *Dandelion* have a function of heat-clearing and detoxify [4]. In addition, man and colleagues found that extracts of herb including *Rhizoma Smilacis Glabrae* improves allergic contact dermatitis induced by 1-fluoro-2,4-dinitrobenzene [5]. Furthermore, Jiang and associates also showed that the aqueous extract of *Rhizoma Smilacis Glabrae* had immunomodulating effects. They found that *Rhizoma Smilacis Glabrae* significantly recovered the picryl chloride-induced delayed-type hypersensitivity to almost normal levels from the higher or lower levels induced by different treatments of cyclophosphamide with a normalization of CD4/CD8 ratio [6]. In our prescription, *Scutellaria Barbata* is a species of flowering plant in the mint family, Lamiaceae. As an herb used in Chinese medicine it is known as Ban Zhi Lian. It has been used as an herbal remedy for inflammation and traumatic injury [7]. Administration of Chinese herbs may have beneficial anti-inflammatory and immunomodulatory effects, but little is known about the potential for drug interactions in such combinations. More studies are needed to clarify the mechanisms of Chinese medicine.

On August 31, 2012, soft tissue of the skin on facial messes was taken to Beijing Ditan Hospital. Three months later, pathology result showed partial exfoliation, hyperplasia of dermal tissue and vascular endothelial cells, granulomas with numerous neutrophils (Figure 2); special stain showed periodic acid-schiff (PAS) negative, gomori's methenamine silver (GMS) negative, acid-fast stain negative, gram stain negative. The final diagnosis was infectious granulomatous.

Although not crucial to establishing the diagnosis, follow-up should include the judgment of potential pathogens [8]. We are unaware of any previous reports of a systemic multiple strawberry-like infectious granuloma. Although for our patient initially, without culture results, it would have been imprudent to ignore the possibility of a refractory infection. Following the negative culture result, we were prompted to question whether the lesion was associated with work environment.



Figure 1: Facial photos of the patient during treatment and follow-up.

A: On August 25, the patient's face showing many strawberry-like dark red granulomas. B: Five days later, the lesions on the face had smaller than before. C: On September 9, lesions had shrunk peanut-sized lesions; D: On the forth visiting, the lesions had collapsed on his face. E: On December 27, the collapsed lesions remained the dark brown hyperpigmentation.

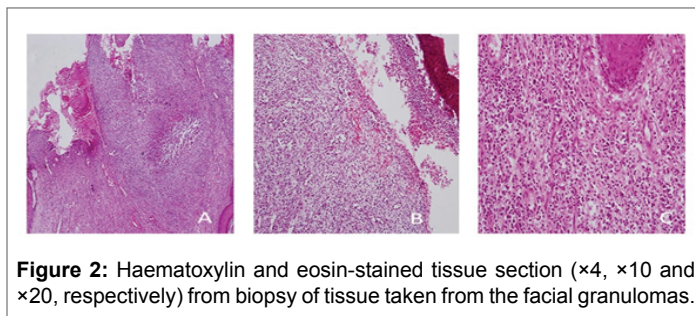


Figure 2: Haematoxylin and eosin-stained tissue section ($\times 4$, $\times 10$ and $\times 20$, respectively) from biopsy of tissue taken from the facial granulomas.

The patient has been raising 40 sheep for two years. When searching Medline using the terms sheep and granulomatous disease, we found that Actinobacillosis is a zoonotic disease caused by *Actinobacillus*. *Actinobacillus lignieresii* can cause a granulomatous disease in sheep. A few human soft tissue infections, originating from contact with sheep have been reported [9]. Based on the patient's exposure, we thought that *Actinobacillus lignieresii* may be the etiology of this disease onset. Establishing the diagnosis of infectious granulomatous was important, because the patient would have remained at risk of harm from future exposure to related cause. However, a potential limitation in our study should not be neglected. Due to the majority of lesions appeared on the patient's face, we have not the picture of lesions besides on the face before treatment.

In conclusion, Chinese medicine can be an option in treating infectious granuloma patient without common culture results. However, further studies involving larger patient numbers are required in order to allow a final conclusion on the effect and mechanisms of this form of treatment.

Acknowledgement

Supported by State Administration of Traditional Chinese Medicine, China (No. 201307001).

References

- Mukhopadhyay S, Farver CF, Vaszar LT, Dempsey OJ, Popper HH, et al. (2012) Causes of pulmonary granulomas: a retrospective study of 500 cases from seven countries. *J Clin Pathol* 65: 51-57.
- Rosenberg JD, Scheinfeld NS (2003) Cutaneous histoplasmosis in patients with acquired immunodeficiency syndrome. *Cutis* 72: 439-445.
- Florin TA, Zaoutis TE, Zaoutis LB (2008) Beyond cat scratch disease: widening spectrum of *Bartonella henselae* infection. *Pediatrics* 12: e1413-e1425.
- Commission CP (2005) Pharmacopoeia of the Peoples Republic of China (Part one). Beijing. Chemical Industry Press.
- Man W, Man M, Hupe M, Martin-Ezquerro G, Feingold KR, et al. (2011) Topical herbal extract (Huangdang mixture) exhibits both preventive and therapeutic effects in murine acute irritant contact dermatitis. *Int J Dermatol* 50: 1421-1427.
- Jiang J, Xu Q (2003) Immunomodulatory activity of the aqueous extract from rhizome of *Smilax glabra* in the later phase of adjuvant-induced arthritis in rats. *J Ethnopharmacol* 85: 53-59.
- Wikimedia Foundation (2014) Inc. *Scutellaria barbata*.
- Song E, Jaishankar GB, Saleh H, Jithpratuck W, Sahni R, et al. (2011) Chronic granulomatous disease: a review of the infectious and inflammatory complications. *Clin Mol Allergy* 9: 10.
- Public Health Agency of Canada (2015) *Actinobacillus* spp. and *Aggregatibacter* spp.