

Effects of Ethanolic Extract of *Sesamum Indicum* Seeds on the Histology and Sperm Concentration in Ketoconazole-Induced Testicular Damage in Male Wistar Rats

Yusuf MK*, Ibegbu AO, Alawa JN, Ilyas MO and Evang A

Department of Human Anatomy, Faculty of Medicine, Ahmadu Bello University, Nigeria

*Corresponding author: Yusuf MK, Ibegbu AO, Alawa JN, Ilyas MO, Evang A (2018) Effects of Ethanolic Extract of *Sesamum Indicum* Seeds on the Histology and Sperm Concentration in Ketoconazole-Induced Testicular Damage in Male Wistar Rats. Clin Res Open Access 4(4): E-mail: maylkabiru2008@yahoo.com; maylkabiru2014@gmail.com

Received: 31 Aug, 2018 | Accepted: 30 Oct, 2018 | Published: 06 Nov, 2018

Citation: Yusuf MK, Ibegbu AO, Alawa JN, Ilyas MO, Evang A (2018) Effects of Ethanolic Extract of *Sesamum Indicum* Seeds on the Histology and Sperm Concentration in Ketoconazole-Induced Testicular Damage in Male Wistar Rats. Clin Res Open Access 4(4): dx.doi.org/10.16966/2469-6714.141

Copyright: © 2018 Yusuf MK, et al. This is an open-access article distributed under the terms of the Creative Commons Attribution License, which permits unrestricted use, distribution, and reproduction in any medium, provided the original author and source are credited.

Abstract

Aim: The study was aimed at evaluating the effects of ethanolic extract of *Sesamum indicum* seeds on the histology and sperm concentration in ketoconazole induced testicular damage in Wistar rats.

Methods: Forty eight (48) adult male Wistar rats were divided into eight (8) Groups of six (6) rats each. Groups 1, 2, 3, 4, 5, 6, 7 and 8 were administered 1 ml of normal saline, 100 mg/kg body weight (bwt) of Ketoconazole only, 500 mg/kg bwt of Ethanolic Extract of *Sesamum Indicum* (EESI) seeds then 100 mg/kg bwt of Ketoconazole, 100 mg/kg bwt of Ketoconazole then 250 mg/kg body weight of EESI seeds, 100 mg/kg bwt of Ketoconazole then 500 mg/kg bwt of EESI, 100 mg/kg body weight of Ketoconazole then 0.36 mg/kg body weight of Mesterolone, 0.36 mg/kg body weight of Mesterolone, 500 mg/kg body weight of EESI respectively. All administrations were carried out orally once per day. The testes were processed for histopathological and semen analyses.

Result: Significant increase in the sperm concentration of rats administered EESI before the administration of ketoconazole and enhancement of the histo-architecture of testicular cells were noted when compared with rats in the control Group and those administered ketoconazole only ($p \leq 0.05$).

Conclusions: Ethanolic extract of *sesamum indicum* seeds enhances sperm cell concentration and ameliorates the toxic effects of ketoconazole on the testes by improving the cyto-architecture of the treatment group.

Keywords: Evaluation; *Sesamum*; Ketoconazole; Testes; Rats

Introduction

Toxins such as drugs, chemicals, endocrine disruptors, biogenetically engineered western diets and life style among other factors are known to affect normal body functions and most especially reproductive health [1]. One of such toxins (Drugs) which possess adverse health hazard despite its advantages is Ketoconazole, an antifungal drug used in the treatment of fungal infections such as blastomycosis, histoplasmosis, coccidioidomycosis and paracoccidioidomycosis [2].

Ketoconazole is packaged pharmaceutically in the form of tablets, creams and injections and has been reported to inhibit the stimulation of testicular testosterone production by Human Chorionic Gonadotropine in a dose dependent manner [3]. Steroids such as dihydrotestosterone and estradiol are equally, selectively displaced from serum-binding globulin by ketoconazole [4]. The suppression of testicular testosterone synthesis and the displacement of oestrogen from sex hormone binding globulin may decrease the androgen/

oestrogen ratio of the blood and contributes to the development of gynaecomastia that has been reported in some ketoconazole treated patients [4]. Administration of ketoconazole alters sperm indices and causes severe histopathological lesions such as depletion of germ cells, degeneration of the seminiferous tubules, marked oxidative damage to testicular lipids and alteration of natural anti-oxidants [2].

Over the years, there has been increased scientific research to minimize the health hazards potentiated by some toxins and this was done on phytochemicals extracted from plant species [5]. In an effort to stem the contraindications of some of these synthesized drugs, plant medicine (phyto-medicine) has been used as alternatives in many parts of Africa and the rest of the world [6].

Effective health cannot be achieved in Africa, unless orthodox medicine is complemented with traditional medicine [6]. At least 80% of Africans depends on plant medicine for their health care [7]. Fruits and vegetables have been recognized as natural sources of various bioactive compounds [8]. The bioactive properties of fruits

and vegetables could be attributed to their phyto chemical constituents such as flavanoids, anthocyanins, Vitamins C and E, phenolic compounds, dietary fibers and carotinoids [9]. One of such vegetable plants is *Sesame indicum* whos taxonomic order is lamiales, Family is pedaliaceae, Genus is *Sesamum* and Specie is *indicum*. Sesame seeds exist in brown, black and yellow forms and are called ridi in Hausa, Ekuku in Yoruba, Isasa in Ibo and go-ri-go in Ebira languages that are ethnic groups in Nigeria.

Sesame seeds oil has been used as healing oil for thousands of years, it naturally possess antibacterial properties for common skin pathogens such as *staphylococcus* and *streptococcus species*. It also possesses anti-fungal, antiviral and anti-inflammatory effects [2]. The entire sesame plant is very valuable and serves as staple food in most ethnic groups in North-Central and South-Western part of Nigeria and this could be attributed to the high level of fecundity among adult males in these regions [10].

Materials and Method

Seed procurement and identification

470 g of *Sesamum indicum* seeds were obtained from Samaru market-Zaria, Kaduna State, Nigeria and authenticated in the herbarium of the Department of Biological Sciences, Ahmadu Bello University Zaria and assigned voucher no. 4. The seeds were macerated using 95% ethanol to obtain the extract with a yield weight of 46.42 g in solvent form.

Drugs and reagents

Two hundred (200) mg of ketoconazole tablets and 25 mg of Tablet Provirone (Mesterolone) manufactured by Divine New Favour Pharmaceuticals (Anambra State) and Bayers Pharmaceuticals (United Kingdom) with batch Nos. 82339737 and 400 8500 060056 and NAFDAC Nos. A4-2186 and 04-1300, respectively, were

purchased from Micro novo Pharmaceutical Company Plc. Kano, Kano State, Nigeria.

Methods

Extraction of sesame seed: Four hundred and seventy (470) g of *sesame* seed was macerated in a maceration apparatus. The sesame seeds were poured into 2 ml maceration apparatus (Pyrex) and the seeds coats were manually removed. The macerated seeds were later transferred into a three and half (3.5) L beaker containing 95%v/v of ethanol to cause the removal of flavanoids and lignans. It was stirred and left for six hours to allow the extraction of polar substances. The supernatant was sieved off using a metallic sieve and the filtrate was collected into a separate beaker. The filtrate was collected into an evaporating dish with the use of a spatula and placed on a water bath, heated to a temperature of 60°C to completely remove the ethanol. The extract was kept for eighteen hours to allow for evaporation to take place. The yield weight of the extract was 46.42g in solvent form. (Figure 1)

Experimental procedure

The weight of the animals was recorded weekly throughout the experimental period and the mean weight of each group was calculated. LD₅₀ the ethanolic extract of *sesamum indicum* seeds in wistar rats was done and was found to be above 5000 mg/kg bwt [11].

Group 1 was administered 1 ml of normal saline throughout the experimental period to keep the rats in normal physiologic state while Group 2 was administered 100 mg/kg bwt of ketoconazole in accordance with the method of Amin [2]; Group 3 was the Prophylactic group and was administered 500 mg/kg body weight of ethanolic extract of *Sesamum indicum* seeds and 100 mg/kg bwt of ketoconazole while Groups 4 and 5 which were the therapeutic low and high dose. These groups were administered 100 mg/kg bwt of Tablet ketoconazole each, and (250/500) mg/kg body weight of

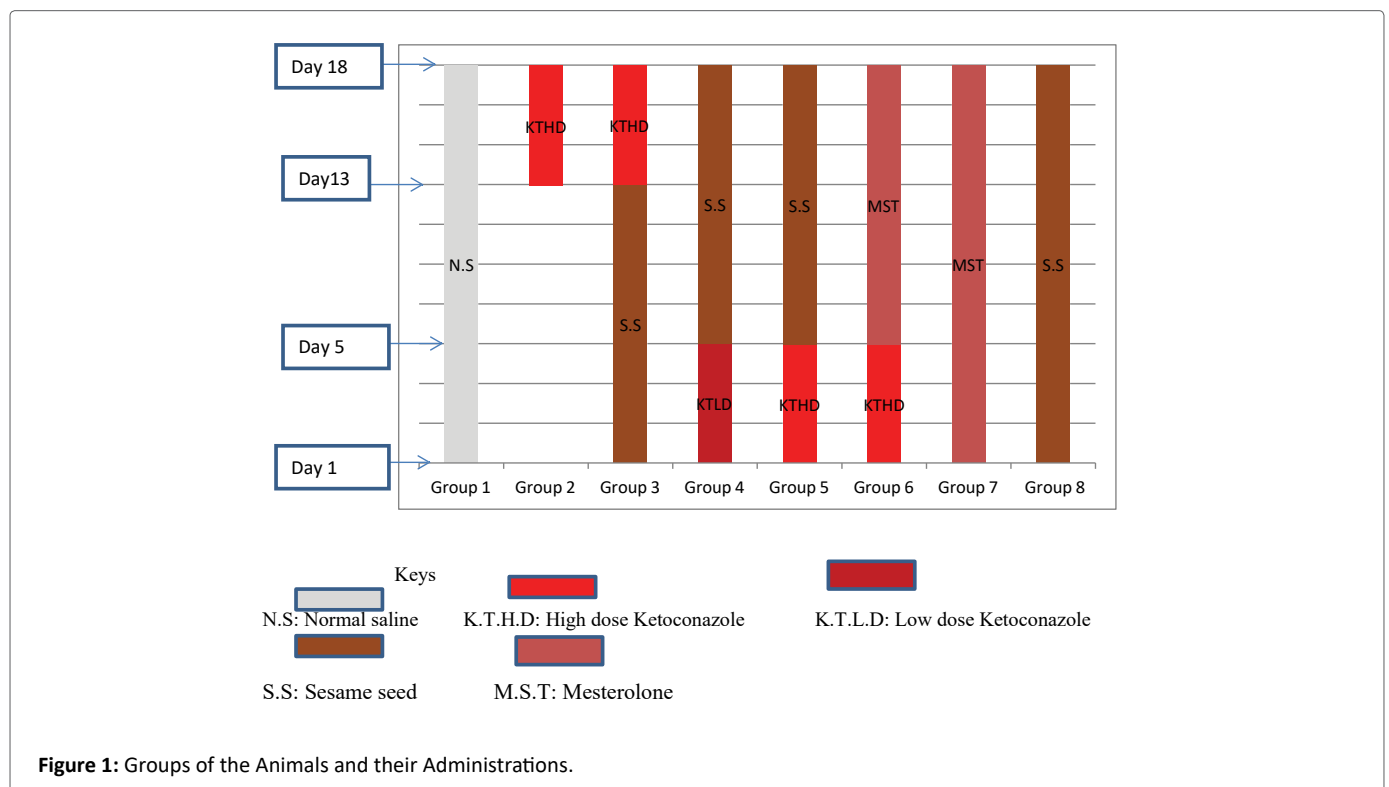


Figure 1: Groups of the Animals and their Administrations.

ethanolic extract of *Sesamum indicum* seeds, respectively. Group 6 was administered 100 mg/kg bwt of ketoconazole and 0.36 mg/kg bwt of Mesterolone (testosterone) which was used as a standard drug. Group 7 was administered with 0.36 mg/kg bwt of mesterolone to study effect of mesterolone in the testes of Wistar rats and for comparison. Group 8 was administered with 500 mg/kg body weight of ethanolic extract of *sesame* seeds (Table 1).

The equivalent dose of the drugs and the sesame seed extract; in ml (milliliters) were derived using the formulae:

$$Volume(ml) = \frac{Dose \times weight(kg)}{Stock\ concentration}$$

The equivalent dose in ml of ethanolic extract of *Sesamum indicum* seeds was calculated as follows: 500 mg/kg bwt=500 mg=1000 g, the average weights of the rats at the time of commencement of the experiment was 180 g; therefore, the administrable dose (x) for a rat that weighed 180 g was calculated as:

$$Volume = \frac{500\ mg / kg \times 0.180\ kg}{128.3\ mg / ml}$$

0.70 ml was obtained as the volume for a dose of 500 mg/kg bwt which was the high dose group. Similar method was used to calculate the volume of the low dose group (250 mg/kg bwt) and the value 0.35 ml was obtained. Tablet mesterolone was prepared as 25 mg and it was the recommended dose for an adult person (Average weight=70 kg).

From above, the administrable dose per 1 kg was calculated as shown below.

25 mg (mesterolone) =70; kg=70000 g; therefore, the dose (x) for every 1 kg=1000 g is calculated as follows:

$$x = \frac{25\ mg \times 1,000}{70,000} = 0.36\ mg / kg\ bwt$$

From above, the administered dose for a rat that weighed 180 g was calculated as:

$$\frac{0.36\ mg \times 180\ g}{1000\ g} = 0.065\ mg$$

Earlier, it was stated that the packaged form of Mesterolone is 25 mg per tablet.

The tablet was dissolved in 10 ml of distilled water to obtain a concentration of 2.5 mg/ml. from above, 2.5 mg is contained in 1 ml, x ml will contain 0.065 mg. By calculation,

X =0.065/2.5=0.026 ml, therefore, 0.026 ml which contains 0.065 mg of Mesterolone tablet was measured using a micro pipette and was administered to the rats.

Animal sacrifice

The animals were humanely sacrificed through perfusion technique; the left testis was fixed in Bouin's fluid for routine histological analysis and stained with haematoxylin and eosin (H&E). Periodic Acid Schiff (PAS) and Masson Trichrome (MT) stains. The epididymis of the left testis was removed and immersed in 5 ml of formal saline for the determination of the sperm parameters. Semen analysis was done in accordance with [12] with aid of improved Neubauer haemocytometer counting chamber.

Statistical analysis

All data obtained were expressed as mean ± Standard Error of Mean, (SEM). One Way Analysis of Variance (ANOVA) was used to compare the mean difference between and within the groups and a P-value of ≤ 0.05 was considered statistically significant, a post-Hoc was carried out to indicate were significant difference lie. Statistical analysis was carried out using Statistical Package for Service Solution (SPSS) Version 20.

Results

Histological Observation (Plate I-VIII)

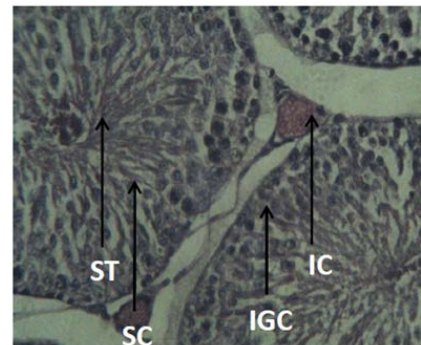


Plate I: A Section of the Testis in Group 1 (0.9 ml of Normal saline, orally, for 18 days) showing normal histology of the testis. SC: Sperm Cells; IC: Interstitial cells; IGC: Immature Germ Cells and ST: Seminiferous Tubules. Heamatoxylin and Eousin at × 400.

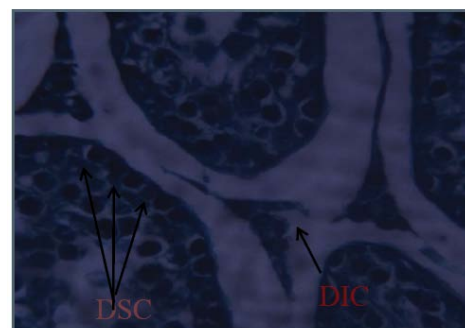


Plate II: A Section of the histology of testis in Group 2 (100 mg/kg bwt of Tab. Ketoconazole, orally for 5 days) Showing Degenerated Sperm Cells and Degenerated Interstitial Cell/Membrane, (Masson Trichrome × 400).

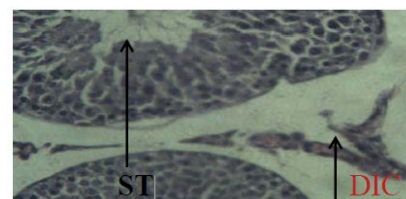


Plate III: A Section of the Testis from Group 3 (500 mg/kg bwt of Ethanolic extract of *Sesamum indicum* seed; orally, for 13 Days and 100 mg/kg bwt of Tab. Ketoconazole) showing intact histo architecture of the testis with mildly degenerated interstitial cells (H & E × 400). ST: Seminiferous Tubules.

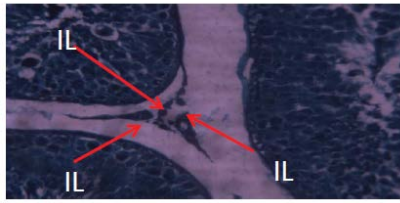


Plate IV: A Section of the Testis from Group 4 (100 mg /kg bwt of ketoconazole; orally for 5 Days and 250 mg/kbw of *Sesamum indicum* seeds for 13 Days). Showing gradual restoration of the interstitial lining (Masson Trichrome stain $\times 400$). ST: Seminiferous Tubules; IC: Interstitium; IL: Interstitial Lining.

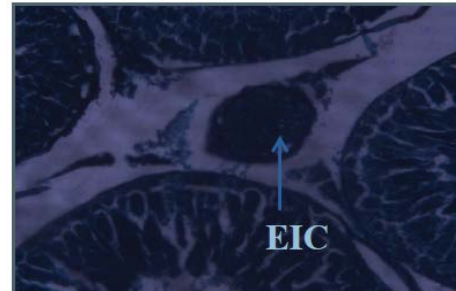


Plate VIII: A Section of the testis in Group 8 (500 mg/kg bwt of *Sesamum indicum* seeds, orally for 13 Days) Showing Enlarged Interstitial Cells (Masson Trichrome $\times 400$).

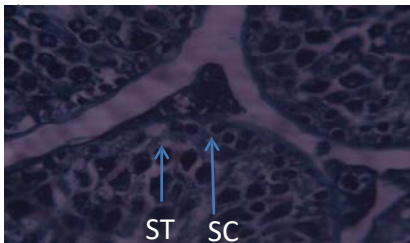


Plate V: A Section of the Testis from Group 5 (100 mg/kg of Ketoconazole; orally for 5 Days and 500 mg/kg bwt of *Sesamum indicum* seeds for 13 Days) Showing normal sperm cells and normal sertolicells (Masson Trichrome stain $\times 400$). STC: Sertoli Cells; SC: Sperm Cells.

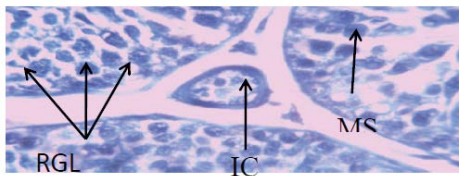


Plate VI: A Section of the testis from Group 6 (100 mg/kg bwt of Tab. ketoconazole and 0.06 mg of Tab. Mesterolone: Orally for 5 Days and 13 Days respectively) Showing RGL (Restored Germinal Layer) proliferated spermatocytes. Enlarged interstitial cell and matured spermatocytes. (PAS stain $\times 400$) IC: Interstitial cell; MS: Matured Spermatocyte.

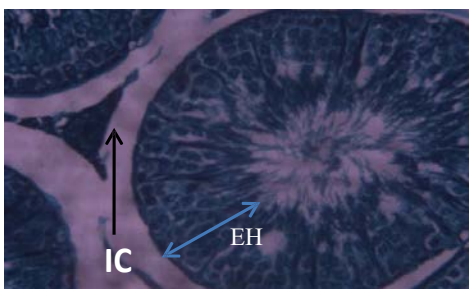


Plate VII: A Section of the testis from Group 7 (0.06 mg of Tab. Mesterolone orally for 14 Days). Showing increased sperm cells proliferation, increased epithelial height and enlarged interstitial cell. (Masson Trichrome stain $\times 400$). EIC: Enlarged Interstitial Cell, SC: Sperm Cells; EH: Epithelial Height.

Sperm concentration

The results from table 2 showed that the amount of sperm concentration in Groups 3, 4, 5, 6, 7 and 8 significantly increases when compared with group 2 ($P \leq 0.05$). Similarly, the amount of sperm concentration in Group 1 significantly increases when compared with that in group 2 ($P \leq 0.05$). i.e. the amount of sperm concentration in Group 2 significantly decreases when compared with that in Groups 1, 3,4,5,6,7 & 8 ($P \leq 0.05$).

Discussion

From the present study, it was observed that ketoconazole induced testicular damage such as reduction of sperm concentration and severe histopathological lesions. The reduction of sperm concentration was characterized by decrease in the number and concentration of sperm cells in the group administered ketoconazole alone which resulted in decreased sperm concentration. This observation was in line with the findings of Amin [2], who observed that ketoconazole induced testicular damages in male Wistar rats by reducing the sperm indices and serum testosterone level.

The administration of ethanolic extract of *Sesamum indicum* appeared to have minimized the damages caused by ketoconazole in testes which may be due to its chelating and anti-oxidant properties.

Follicle Stimulating Hormone (FSH) has been shown to have a synergistic effect with testosterone hormone and stimulating synthesis of the androgen receptor at the receptor level [13]. It may then be assumed that the extract of sesame seeds may have caused the FSH to instigate increase in testosterone level which led to the observed increase in the sperm concentration as indicated in the present study.

It has been reported that endocrine disruptors are wide spectrum ion blockers [14]. This also suggests that ketoconazole disrupted the ion channel leading to the disturbance in ionic equilibrium across membrane and ultimately to a disruption or distortion in the cellular morphology. From the present study, it was observed that disruption of the tubular morphology was also accompanied by general destruction of testicular interstitium and spermatogenesis.

Conclusion

The ethanolic extract of *sesamum indicum* seeds has enhanced sperm cell concentration and ameliorated the toxic effect of ketoconazole on the testes by improving the cyto-architecture of the histology of the treatment groups and the ameliorative effect was most prominent on the prophylactic administration of the extract to the experimental animals.

Table 1: Groups of the Animals and their Administrations.

S/N	Groups	Dosage/Duration of Administration
1	Normal Control	1 ml of Normal Saline daily for the experimental period (1 st -18 th day of the experiment)
2	Abnormal Control	Ketoconazole (100 mg/ kg bwt) once daily for five (5) days (14 th -18 th day of experiment)
3	Prophylactic Group	500 mg/kg bwt of ethanolic extract of <i>sesame indicum</i> seeds for 13 days (1 st -13 th day of the experiment)+100 mg/kg bwt of ketoconazole for (5) five days. (14 th -18 th day of the experiment)
4	Therapeutic Low Dose Group	100 mg/kg bwt of Ketoconazole for (5) five days (1 st -5 th day of the experiment) + 250 mg/kg bwt of ethanolic extract of <i>sesame indicum</i> seeds once daily for 13 days (6 th - 18 th day of the experiment) respectively
5	Therapeutic High Dose Group	100 mg/kg bwt of Ketoconazole for (5) five days (1 st -5 th day of the experiment) + 500 mg/kg bwt of ethanolic extract of <i>sesame indicum</i> seeds for thirteen days (6 th -18 th day of the experiment)
6	Ketoconazole and Mesterolone	Ketoconazole 100 mg/ kg bwt for five days (1 st 5 th day of the experiment) + 0.36 mg/kg bwt of Mesterolone once daily for thirteen days (6 th -13 th day of the experiment)
7	Mesterolone	0.36 mg/kg bwt of Mesterolone once daily for thirteen days (6 th -18 th day of the experiment)
8	<i>Sesame</i> seeds extract only	500 mg/kg bwt of ethanolic extract of <i>Sesamum indicum</i> seeds only for thirteen days (6 th -13 th day of the experiment)

All administrations were carried out orogastrically and all the animals were sacrificed on the same day.

Table 2: Sperm Concentration of Experimental Animals.

Group	N	Conc.(n×10 ⁶ /ml)/Mean ± SEM
1	6	51.33 ± 0.95
2	6	33.17 ± 0.60 ^{abcdefg}
3	6	73.33 ± 2.78
4	6	69.50 ± 2.93
5	6	86.50 ± 0.76
6	6	86.50 ± 0.43
7	6	87.00 ± 2.18
8	6	75.33 ± 2.26

abcdefg =Groups 1, 3, 4, 5, 6, 7 and 8 respectively indicates significant differences with group 2.

References

- Izegbu MC, Ojo MO, Shittu LA (2005) Clinico-pathological patterns of Testicular Malignancies in Ilorin, Nigeria--a report of 8 cases. *J Cancer Res Ther* 1: 229-231.
- Amin A (2008) Ketoconazole induced testicular Damage in rats reduced by *Gentiana* extract. *Exp Toxicol Pathol* 59: 377-384.
- Richard S (2015) Male Infertility Human Sperm Morphology Fixed and stained human sperm Advanced fertility Centre of Chicago sperm pictures-Male infertility, Human sperm morphology fixed and stained human sperm pictures from the IVF lab.
- Grosso DS, Boyden TW, Pamerter RW, Johnson DG, Stevens DA, et al. (1983) Ketoconazole inhibition of testicular secretion of testosterone and displacement of steroid hormones from serum transport proteins. *Antimicrob Agents Chemother* 23: 207-212.
- Bankole MA, Shittu LAJ, Ahmed TA, Bankole MN, Shittu RK, et al. (2007) Synergistic Antimicrobial Activities of phytoestrogen in crude extract of two sesame species against some common Pathogenic Micro-organisms. *Afr J Tradit Complement Altern Med* 4: 427-433.
- Okigbo RN, Emeka EC (2008) Antimicrobial effect of three tropical plant extracts on *Staphylococcus aureus*, *Escherichia coli* and *Candida albicans*. *Afr J Tradit Complement Altern Med* 5: 226-229.
- Sofowora A, Eyioppe O, Adedeji O (2013) The role and place of medicinal plants in the strategies for disease prevention. *Afr J Tradit Complement Altern Med* 10: 210-229.
- Penington RT, Lavin M, Oliveira-Filho A (2009) Woody plant diversity, evolution and ecology in the tropics: perspective of seasonally dry tropical forest. *Annual review of ecology, evolution and systemic* 40: 437-457.
- Amado JA, Pesquera C, Gonzalez EM, Otero M, Freijanes J, et al. (1990) Advances in agronomy. *Postgraduate Medical Journal* 66: 221-223.
- Akpan IG, Idowu AA, Misani SM (2006) Collection and Evaluation of *Sesame* (*Sesamum Spp*) germplasm in Nigeria 142: 59-62.
- Yusuf MK, Ibegbu AO, Agbon AN, Evang A (2017) Determination of median lethal dose of ethanolic extract of *Sesamum Indicum* seeds in adult wistar rats. *Afr J Cell Pathol* 9: 73-76.
- World health organization (2010) WHO manual for semen analysis. 540-577.
- Mahabadi (2013) Glutamine in Clinical. *Nutrition* 17: 766-829.
- Sung DJ, Kim JG, Won KJ, Kim B, Shin HC, et al. (2012) Blockage of K⁺ and Ca²⁺ channels by azole antifungal agents in neonatal rats ventricular myocytes. *Biol Pharm Bull* 35: 1469-1475.