

Photobiomodulation used in the Post Operative in Diabetic Feet Injuries

Milena Claudia Fagundes dos Santos¹, Clarissa Niero Moraes^{1*} and Reginaldo Boppre²

¹Department of Physiotherapy, University of South Santa Catarina, Brazil

²Department of Medicine, University of South Santa Catarina, Brazil

*Corresponding author: Clarissa Niero Moraes, Department of Physiotherapy, University of South Santa Catarina, Brazil, Tel: 4836223410; E-mail: clarifisio@hotmail.com

Received: 05 Mar, 2018 | Accepted: 06 Aug, 2018 | Published: 13 Aug, 2018

Citation: Dos Santos MCF, Moraes CN, Boppre R (2018) Photobiomodulation used in the Post Operative in Diabetic Feet Injuries. *J Diab Res Ther* 4(1): dx.doi.org/10.16966/2380-5544.137

Copyright: © 2018 Dos Santos MCF, et al. This is an open-access article distributed under the terms of the Creative Commons Attribution License, which permits unrestricted use, distribution, and reproduction in any medium, provided the original author and source are credited.

Abstract

Introduction: Diabetes Mellitus (DM) is a disease of high glucose level known for several complications. Unstable degrees of resistance and difficulty of insulin flow, deficiency of hormone response in peripheral tissues, difficult scarring and bacterial control are common complications in the diabetic foot. One of the treatments that have scientific evidence to aid in the healing process and the antibacterial effect is biophotomodulation through a LASER (Light Amplification by Stimulated Emission of Radiation) 660 nm and LED (Light Emitting Diode) 470 nm.

Materials and methods: This was a quasi-experimental study in which the sample consisted of 9 patients, totaling 11 diabetic feet with ulcerations and/or amputations, mean age of 64.2 years and divided into three groups: Group 1 (LASER/LED), Group 2 (LASER) and Group 3 (LED), evaluated through Visual Analogue Scale (VAS) for pain, circumference for edema evaluation, contracture evaluation of the treated area through photo before and last session, with an average of seven sessions three times a week.

Results: Group 1 showed increased granulation tissue, epithelial tissue, greater retraction of the ulceration area, hydrated borders without hyperkeratosis, being superior to isolated therapies.

Final considerations: The application of LASER reconciled with the LED was promising and presented superior results to the isolated applications of LASER and LED. It is necessary to continue the study in a larger number of patients to obtain greater conclusive results. It is hoped that this treatment will be added to conventional treatment, providing a better quality of life for individuals suffering from diabetic feet, thus avoiding further amputations.

Keywords: Diabetes Mellitus; Low-intensity light therapy; Amputation

Introduction

Diabetes Mellitus (DM) is a disease of high glucose level known for several complications [1]. About 90 to 95% of cases of diabetes are type 2 has no definite age and is usually diagnosed after 40 year's [2]. That comprises a group of metabolic diseases that result from changes in the secretion and/or action of insulin produced by the Pancreas [3]. Its main property is hyperglycemia linked to dysfunction of various systems such as kidney, nervous and cardiovascular [3]. With unstable degrees resistance and difficulty of flow of insulin, the hormone response and in peripheral tissues, one of the most common complications is the diabetic foot [4].

Complications related to the feet are characterized by an injury resulting from Diabetic Neuropathy (DN) and peripheral vascular problems [2,5,6]. DN affects different parts of the nervous system, including the peripheral nerves (sensorimotor), autonomic and spinal nerves complications including peripheral vascular disease, which is characterized by impaired blood supply, especially in the lower limbs

[1,6]. Neuropathy is one of the most common forms of a complication of the disease, observed in 8 to 12% of diabetics when the diagnosed carrier of the disease and after long periods of onset (20 to 25) 50 to 60% of the cases [7]. In conjunction with neuropathy and peripheral arterial disease, DM affect wound healing enhances infection and consequently leads to a possible amputation [1]. Amputated patients suffer from significant alterations in the arterial pulse and deficiency in healing resulting in postoperative complications surgical procedures such as poorly healing, edema, contractures, ulcerations stump, infection, inflammation, scar retraction, neuromas, Deep Vein Thrombosis (DVT), bone spicules, necrosis, ischemia, deformity and stump pain, which can lead to re-amputation [3,8].

The neuropathy, ischemia associated with immunodeficiency and favors the development of infections in the lower limbs [2]. Lighter infections have the preeminence of Gram-positive cocci, such as *Staphylococcus aureus*, *Streptococcus* β -hemolytic group B, A, C, G of Lancefield [9]. Moderate severity (end-threatening) infections may have more than one infecting germs, such as Gram-positive cocci and

Gram-negative bacilli (*Proteus mirabilis*, *Escherichia coli*, *Klebsiella pneumoniae*, *Pseudomonas aeruginosa*) [9]. Severe infections (life-threatening) are polymicrobial (Gram-positive cocci and negative, aerobic and anaerobic) and are characterized by the presence of resistant to many antibiotics germs (*Staphylococcus meticilino-resistant*, *Pseudomonas*, *Enterococcus*) [9].

One of the treatments that have scientific evidence to aid in the healing process and the antibacterial effect is the photobiomodulation that changes the biological activity with the use of photons in non-thermal irradiation through a LASER (Light Amplification by Stimulated Emission of Radiation) and LED (Light Emitting Diode) [3,4,10-13].

The biophotomodulation through He-Ne laser light (Helium and Neon), the semiconductor light emitting comes into contact with the cells by stimulating the synthesis of collagen, elastin, angiogenesis, and promote the effect analgesia [12-14]. The angiogenesis leads to improved infusion, demonstrating a histological increase in neovascularization [15]. The light LASER He-Ne 660 nm (nanometers) the 3 J/cm² significantly stimulates collagenogenesis, reduced inflammatory infiltrates and early inflammatory phase solution of wounds, distinguished as to complete re-epithelialization process [15].

The LED exerts an antibacterial effect, stimulating the bacterial membrane releasing chromophores and of the Oxygen-Reactive Species (ERO), and this process causes a photochemical reaction and forms free radicals and Singlet oxygen reactive species, which in turn lead to bacterial destruction [10,11,16]. The photosensitizer fluorescence spectroscopy (specific blue light) aids in diagnosis, suggesting endogenous porphyrin in cells, significantly reducing the bacterial load irradiated with blue light [16,17]. The positive effects with the LED blue spectrum (704 nm) have been proven in the hospital environment, has a strong bactericidal action, combating the contamination by *Staphylococcus aureus* resistant to the antibiotic methicillin [10,11,16,18-20].

The general objective of this study was to compare the results of the individual and joint application of LASER He-Ne 660 nm and the LED 470 nm on distal lower limb injuries in diabetic patients. The specific objectives were: to measure the area and perimeter of the wound after LASER and/or LED application, to verify the level of pain after the application of the therapies, and to analyze the edema of the distal region of the lower members before and after treatment.

Our hypothesis is that the therapy through Photobiomodulation using light LASER He-Ne and LED light at different wavelengths has better effects when applied together in the treatment of distal ulcerations and amputations of diabetic lower limbs.

Materials and Methods

It is characterized as a study of nearly-experimental design, in which qualitatively and quantitatively analysis data is obtained. The research was developed in Hospital Nossa Senhora da Conceição (HNSC) of the city of Tubarão/SC, during April to October of 2017. The sample consisted of 10 patients who entered the HNSC totaling 11 diabetic feet with ulcerations and/or amputees for the same reason.

Patients with diabetic injury (ulcer and necrosis) and with any level of diabetic foot amputation admitted to the HNSC. Exclusion criteria were non-diabetic patients with standing amputations or who presented contraindications to low-intensity laser or LED treatment with tumors, epilepsy, photophobia, pregnant women, and amputations with epiphyseal plaques.

The research was approved by the Ethics Committee of the University of Southern Santa Catarina (UNISUL-opinion: 2,045,898). Throughout the study, confidentiality and anonymity of the information were maintained, according to the Resolution 466/2012 of the National Health Council. All participants in the study previously signed the Informed Consent Form (TCLE) and Consent for photographs, after being elucidated regarding the procedures performed in the study.

The patients were evaluated in the first and last session with 7 applications on average, through the adapted evaluation form, composed of personal data, general information about their health; Visual Analogue Scale (VAS) for pain, cirtometry for evaluation of edema, evaluation of the contraction of the treated area through photo and it was included with the level of glucose employees of the hospital.

The photos were taken with a photographic device of the manufacturer SONY®, model NEX-F3, 16.1 MP, SEL1855 lens, before the first and last session. TNT of blue color was used for the background, discarded at each procedure. The distance of the photo was 25 cm with ambient light. The photos of the first and last sessions were performed using a disposable printed ruler and were analyzed with AutoCad® software of Autodesk®.

The cirtometry was performed in the first and last session, using a disposable printed ruler, with three measuring points on the tibia: 5 cm, 10 cm and 15 cm above the medial malleolus. After the evaluation, the procedures were started in amputated patients with diabetic foot who were admitted to the HNSC with the help of Laser Elite equipment from DMC Equipamentos Ltd.

Subjects were selected by convenience sampling, with the first participant for Group 1 (LASER/LED), the second patient for Group 2 (LASER), and the third patient for Group 3 (LED), respectively. The session environment was prepared and sanitized before and after sessions according to biosafety standards. During the sessions were used procedure gloves, physiological saline at room temperature for cleaning the stump, sterile gauzes, goggles to the patient and the investigator, the plastic ISO film to wrap the apparatus head, being discarded after each session.

The groups were submitted to the following procedures:

i) Group 1 (LASER and LED): This group was subjected to three weekly sessions, first the application of blue spectrum LED light with wavelength at 470 nm with a 30 second exposure per cm² around the stump and outer edges of the severed area and then the application of laser red spectrum with wavelength at 660 nm with the act of 3 J/cm² in the continuous mode, the perpendicular, with a distance of 1 cm throughout the dorsal region of the foot and to the top line of the medial and lateral malleolus, for the same period quadrant.

ii) Group 2 (LASER): This group was submitted to three weekly sessions, the red spectrum LASER radiation with wavelength at 660 nm with dose 3 J/cm² for a time of 30 seconds in continuous order, perpendicular with distance of 1 cm, throughout the dorsal and plantar region of the foot to the superior line to the medial and lateral malleolus, for the same period per quadrant.

iii) Group 3 (LED): This group was subjected to three weekly sessions, the application spectrum of the blue LED light at wavelength 470 nm with exposure of 30 seconds per cm², in continuous mode, perpendicular, with a distance of 1 cm, throughout the stump and external edges, for the same period per quadrant.

All groups continued medical supervision according to clinical behavior, with submission to a broad-spectrum antibiotic, and after

laser/LED therapy, application of collagenase in tissue necrosis slough and fibrin and gauze moistened with Essential Fatty Acids (EFA's).

The Results were entered into an electronic database to aid Microsoft Excel software and transported to the GraphPad Prism software 7.03 for statistical analysis. For comparison of means, Kruskal-Wallis, Dunn's test, was used to compare the difference between the three groups, with paired nonparametric samples. A significance level of 5% was adopted. To analyze the photos, the AutoCad program was used to measure the area and perimeter of the photos before and after treatment.

Results

Data were collected in the period from April to October 2017, where the sample consisted of 12 patients, but two patients entered the exclusion criteria of the study because they had contraindications to LASER and LED, remaining 10 patients (eight men and two women). Of these, 11 feet were treated, in a total of nine amputations, an ulcer and a necrosis with a diagnosis of amputation. The overall mean age of the patients was 64.2 years.

The sample characterization was composed of three groups. Three male patients participated in Group 1 (LASER/LED); one patient presented compensated glucose and two patient's hyperglycemia during treatment. In group 2 (LASER), four patients participated, three female and one male, two of whom presented compensated glucose, one patient presented hyperglycemia and one patient hyperglycemia above 600 mg/dl. In Group 3 (LED) four patients participated in the treatment, two of them were female and two were male, all of whom presented hyperglycemia during treatment.

The post 7 held on average applications, there is a statistically significant result was observed in relation to the decrease in the mean area and perimeter in group 1 (LASER / LED) ($p=0.12$), and in group 2 (LASER) ($p=0,06$), in proportions close to group 1. The same proportion did not occur in group 3 (LED), with no significant result ($p=0.3125$ for area and $p=0.5$ for perimeter) and increased PD after the applications, due to the increase in the perimeter of the lesion presented by one of the patients in the sample.

In relation to the 5, 10 and 15 cm cirtometry above the medial malleolus for the control of ankle edema, after the applications, a reduction corresponding to Area and Perimeter in Groups 1, 2 and 3 was observed.

Local examinations of the feet were performed on the following alterations: interdigital mycoses, hyperpigmentation, lameness, lack of hair, bony prominence, lipodermatosclerosis, fissures, cracks, cyanosis, lymphedema, edema, hyperkeratosis, hypothermia, callosities, dermatitis and dry skin. Among the factors mentioned above, changes observed are compared to dry skin, which now has better hydration in Group 1 (LASER/LED), an increase of hyperkeratosis in Group 2 (LASER) and higher swelling in Group 3 (LED).

The degree of pain of the groups before and after completing the treatments was verified through six options: zero pain, 1-mild pain, 2-uncomfortable pain, 3-distressing pain, 4-horrible pain and 5-excruciating pain. In group 1 (LASER/LED) there was an improvement in the pain scale in two patients (P1 and P2) who started treatment with 3 (distressing pain) and at the end, they had 1 (mild pain). One patient (P3) reported no pain at the beginning and at the end. In group 2 (LASER), three patients (P4, P5 and P6) started with 3 (agonizing pain), finalize Walk 1 (mild pain), a patient (P7) began 1 (mild pain) and scored zero (without pain). In group 3 (LED) four patients are presented different values, where a patient (P8) evolved

2 (uncomfortable pain) to 1 (mild pain), two patients (P9 and P10) evolved from 4 (horrible pain) to zero (no pain) and the third (P11) showed no changes, remaining on scale 3 (distressing pain).

In Group 1 (LASER/LED), after treatment, the presence of abundant granulation tissue, epithelization and a moderate presence of fibrin in the feet of the three patients was observed. The borders did not present hyperkeratosis and remained hydrated (Figure 1).

In group 2 (LASER), the reduction of granulation tissue in one patient (P4) and moderate growth of granulation tissue and epithelialization occurred in three patients (P4, P5, and P6). Three patients presented a moderate presence of fibrin (P4, P5, and P7). The borders showed increased hyperkeratosis in patient 6 and did not remain hydrated (Figure 2).

In Group 3 (LED), after treatment, the presence of abundant fibrin was observed in the four patients (P8 to P11) and poor granulation production in the feet of two patients (P8 and P11). The borders did not present hyperkeratosis and remained hydrated (Figure 3).

Discussion

Diabetic foot is characterized by the presence of at least one of these alterations: neurological, orthopedic, vascular and infectious, which are subject to occur in the foot of diabetic patients and that will probably lead to amputation [21].

Peripheral neuropathy, ulceration, infection and peripheral vascular disease comprising the main reasons which compose the complications of ulcer and lower limb amputations in diabetic patients [21]. Important factors such as low socioeconomic status, smoking, gender, renal insufficiency, ischemia, diabetic neuropathy, high glucose level and triglycerides may also be associated with the risk of amputation of the foot [6,21]. Prevention through organized health and patient behavior are the most effective events in reducing the indicators of amputation of the diabetic foot and they can be reduced by 22 to 75%. In this present study, we tried to point out the risk of neuropathy to diabetic patients and salient or that the knowledge of these factors is essential for the development and applicability of therapy through the LASER photobiomodulation and low intensity LED and the search for positive results, thus avoiding the need for amputation as well as diabetic foot Reamputation [6,21].

Chaves M et al. [12] and Hamblin MR et al. [22], showed that LED light can be as effective as a LASER, since both have similar biological effects, with no significant difference between them when working at the same wavelength. The cellular response to photostimulation is not associated with specific properties of LASER light, such as coherence. The property of coherence is lost during the interaction of light with biological tissue and is therefore not a prerequisite for the process of photostimulation or photoinhibition [12]. The biological effects depend on the reasonable wavelength, the dose and the exposure time in determining the appropriate treatment protocol [12]. As a result, the 3 groups were adopted in this study, and the combination of the two therapies was shown to be more effective in improving wound healing.

The LED has become an alternative to laser systems for several reasons: low cost, the range of wavelengths and working in the ultraviolet range (<400 nm) to infrared (>700 nm) [23].

This study considered the use of phototherapy with LED 470 nm blue spectrum, a wave whose depth does not exceed the epidermis, the antibacterial ability and moisturizing characteristic and typical of that spectrum of the light wave at that depth. The blue light has a bactericidal effect on the surface of the tissue [24]. Guffey JS et al. [23] shows the

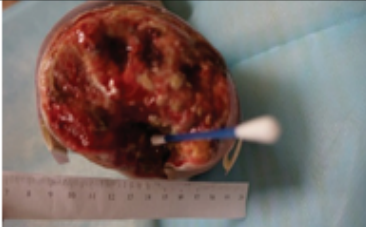
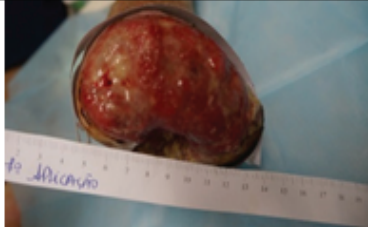










Group 1-Laser/LED			
	Before		After
1 (P1)			
		A= 65,95 cm ² P= 30,59 cm	
2 (P2)			
		A= 20,34 cm ² P= 19,71 cm	
3 (P3)			
		A= 40,02 cm ² P= 29,80 cm	

Figure 1: Area/Perimeter Group 1 (LASER/LED)

bactericidal effect of the radiation between 425 and 525 nm with blue spectrum LED's where Pathogens such as *Porphyromonas gingivalis* and *Escherichia coli* DH5α were killed by wave depth at 425 nm. The wavelength of 625 nm, characteristic of red spectrum LASER light, is not bactericidal for *Porphyromonas gingivalis*, *Escherichia coli* DH5α or *Staphylococcus aureus*. It is being concluded that irradiation above 525 nm light is not bactericidal for *Staphylococcus aureus*, *Escherichia coli* and *Porphyromonas gingivalis*, while the wavelengths from 425 to 525 nm had bactericidal effects [23]. In this study, the culture collection was only presented in four patients and the antibiotic therapy was still in use. The bacteria *Staphylococcus aureus*, and *Enterobacter* species and *Klebsiella oxytoca* (ESBL-producing strains) disappeared at the end of treatment (patients 2,3,9 and 10).

It was also considered for this study, the use of phototherapy using red laser light spectrum with wavelength at 660 nm. Low-intensity LASER with pulsed or continuous output has a wavelength ranging from 630 nm to 1300 nm, with visible and non-visible (infrared) red light spectra [25]. Immunological and vascular systems normalize after the application of low-intensity laser, the metabolic and proliferative processes are activated and produce the same analgesic effect [12]. There are also alterations in fibroblasts (proliferation and increase in Ca²⁺ concentration), keratinocytes (increased IL-1α and IL-8 production and mRNA expression) and proliferation of macrophages [12]. We found in our study similar pain relief in all groups of patients. De Sousa RG et al. [3] reported that the most satisfactory results in wound healing of diabetic patients were those where the He-Ne laser

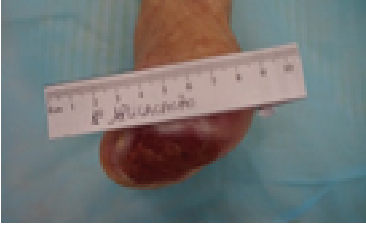















Group 2-Laser			
Before		After	
4 (P4)			
		A= 5,79 cm ² P= 10,01 cm	
5 (P5)			
		A= 53,13 cm ² P= 31,01 cm	
6 (P6)			
		A= 1,66 cm ² P= 4,76 cm	
7 (P7)			
		A= 9,95 cm ² P= 17,01 cm	

Figure 2: Area/Perimeter Group 2 (LASER)










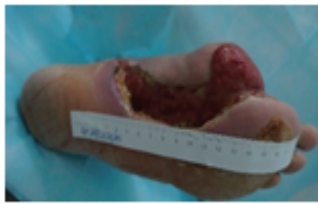






Group 3-LED			
	Before		After
8 (P8)			
		A= 7,18 cm ² P= 9,71 cm	
9 (P9)			
		A= 18,41 cm ² P= 19,39 cm	
10(P10)			
		A= 55,02 cm ² P= 44,77 cm	
11(P11)			
		A= 9,42 cm ² P= 12,74 cm	

Figure 3: Area/Perimeter Group 3 (LED)

with a wavelength of 632.8 nm with energy density in the range of 3-5 J/cm². The most significant biological effects were observed at prevailing dose values, that is, up to 5 J/cm², which are within the Arndt-Schultz curve [12]. Very low doses do not promote biological effects, while higher doses result in inhibition of cellular functions [12]. The energetic state of the cell, the physiological condition of the tissue being treated, is therefore fundamental to determine the dose to be used [12].

In Group 1 (LASER/LED) the light application therapy of LASER 660 nm in the red spectrum followed by the application therapy of LED 470 nm in the blue spectrum, both of low intensity, as proposed in this study, has shown to be promising and presented superior results to the isolated applications of LASER and LED as verified in the data obtained, both in relation to pain as well as area and perimeter and finally edema.

There was a reduction of an area less around 48.93%, result superior to isolated laser therapy (Group 2) and in relation to LED (Group 3) on average seven applications, 3 times a week, and making up the total of 17 days of treatment. Caiafa JS et al. [9] states that the mean time required for the 30% decrease in the lesions in diabetic patients reaches 20 weeks, totaling 140 days. The other studies do not mention the time to reduce the lesion, only the comparison of the results obtained with LED and LASER therapies [14,16,19,26,27].

Regarding the perimeter of lesions, changes were also observed and Group 1 (laser/LED) improved by 22.43% and Group 2 (LASER) 21.15%, while the Group 3 (LED) did not show relevant evolution. Groups 1 and 2 were obtained similar numbers in the evolution of the perimeter, but Group 2 (laser) showed increased hyperkeratosis (callus around the edges) and decreased hydration. In relation to epidermal injury, wound contraction and re-epithelialization from the wound edge, which is important in wound closure, is the proliferation of keratinocyte proliferation [28]. The study by Adamskaya N et al. [28] demonstrates that the laser therapy showed increased keratin tissue at the edges of the tissue and healing was still ongoing. The diabetic foot already suffered from increased keratin, leading the local hyperkeratosis (callus) that progresses to ulceration (perforating plantar disease), and required surgical removal procedure to pair definitive healing, allowing the use of adequate prostheses [4,9]. Caiafa JS et al. [9] corroborated within the proposed study which found an increase in the accentuated hyperkeratosis of the application isolated laser (Group 2) that in the need for a new debridement, the perimeter measurement will increase.

Even if realized in Group 1 (laser/LED) there was a good red granulation tissue compared to groups 2 (LASER) and 3 (LED). Chaves ME et al. [12] reported that in studies with LASER, in the spectral range of 627 to 670 nm with predominant doses 2 to 4 J/cm², a number of important biological effects were observed, such as reduction of inflammatory cells, increase fibroblast growth, collagen synthesis, stimulation of angiogenesis and formation of granulation tissue. However, in the proposed study, the group that presented the most granulation tissue formation was Group 1 (LASER/LED).

Group 1 (LASER/LED) had a lower fibrin content compared to the other groups. In Group 3 (LED) the presence of fibrin after treatment became more pronounced, which made it difficult to close and heal the wound. Brechow A et al. [29] diagnosed the infection if two or more of the following signs have been present: candid purulence; local heat; erythema; lymphangitis; edema; ache; fever; and foul smell. In this study, at the end of treatment, patient 11 with the exception of Group 3 (LED) which increased pain and edema groups showed no signs of infection.

All patients are evolved in pain levels in Group 1 (laser/LED) and 2 (LASER). Group 3 (LED) only patient 11 did not present changes in the pain scale. The low-level photobiomodulation stimulates healing, relieve pain and reduces inflammation [22].

Final Considerations

The application of LASER reconciled with the LED has shown to be promising and presented superior results to the isolated applications of LASER and LED. They were observed increases tissue of granulation tissue epithelialization, greater retraction of ulceration area and the edges had hydrate station without hyperkeratosis the upper isolated therapies.

The use of different wavelengths in the treatment of diabetic foot injury achieves either the desired effect and, at the same time, relieves or adverse reactions and secondary complications.

It is necessary to continue the study in a larger number of patients to obtain greater conclusive results. However, it is expected that through this study, this effect is added to the treatments at the HAT, providing a better quality of life for individuals suffering from diabetic foot, thus avoiding new amputations.

Acknowledgments

I thank God first for being paramount in my life. To my parents Moisés Fagundes (in memoriam) and Maria Conceição dos Santos Fagundes and my family for believing in and investing in my searches. I thank my husband George who gave me strength and courage by supporting me in times of difficulty. My daughter Ana Maria, who has especially enlightened my thoughts, leading me in search of knowledge. My friend Michele Toreti and my niece Ane Isabelle Fagundes Cardoso, for the constant encouragement and support and for sharing their joy in this journey. The teacher Clarissa Niero Moraes for her teachings, patience, and confidence throughout the supervision and guidance and her great detachment. To the employees of Hospital Nossa Senhora da Conceição, Tubarão, Santa Catarina, for welcoming us during our data collection, and especially to vascular doctors, in particular to Dr. Reginaldo Boppre for his collaboration in assisting patients, dedication, and teaching that enabled the accomplishment of this work.

References

- Boell JEW, Ribeiro RM, da Silva DMGV (2014) Fatores de risco para o desencadeamento do pé diabético. *Rev Eletr Enf* 16: 386-393.
- Lucas LPP, Barichello E, Zuffi FB, Barbosa MH (2010) A percepção dos portadores de Diabetes Mellitus tipo 2 em relação à amputação. *Rev Eletr Enf* 12: 535-538.
- de Sousa RG, de Nazaré Madureira Batista K (2016) Laser therapy in wound healing associated with diabetes mellitus-Review. *An Bras Dermatol* 91: 489-493.
- Santos ICRV, Sobreira CMM, dos Santos Nunes EN, de Andrade Morais MC (2013) Prevalência e fatores associados a amputações por pé diabético. *Ciências e saúde coletiva* 18: 3007-3014.
- Meyer PF, de Araújo HG, Carvalho MGF, Tatum BIS, de Andrade Gomes Fernandes IC, et al. (2010) Avaliação dos efeitos do LED na cicatrização de feridas cutâneas em ratos Wistar. *Fisioter Bras* 11: 428-432.
- Al-Rubeaan K, Al Derwish M, Ouizi S, Youssef AM, Subhani SN, et al. (2015) Diabetic foot complications and their risk factors from a large retrospective cohort study. *PLoS One* 10: e0124446.
- Melo EM, Teles MS, Teles RS, Barbosa IV, Studart RMB, et al. (2011) Avaliação dos fatores interferentes na adesão ao tratamento do cliente portador de pé diabético. *Rev Enf Ref* 3: 37-44.
- da Costa Santos ACB, Lee DLHM (2014) Complicações pós-operatórias em amputados de membros inferiores. *InterScientia* 2: 190-198.
- Caiafa JS, Castro AA, Fidelis C, Santos VP, da Silva ES, et al. (2011) Atenção integral ao portador de pé diabético. *J vasc bras* 10: 1-32.
- Agnol M (2008) Estudo comparativo entre os efeitos biomoduladores do LED e do Laser em feridas cutâneas de ratos portadores de diabetes induzido. Universidade do Vale do Paraíba.
- dos Santos JMA, Barbosa ALP, Jean Nunes dos S (2016) Avaliação da Fotobiomodulação Laser/LED em defeito ósseo no fêmur de ratas osteoporóticas: estudo histológico, histomorfométrico e por espectroscopia Raman em modelo animal.

12. Chaves ME, Araújo AR, Piancastelli AC, Pinotti M (2014) Effects of low-power light therapy on wound healing: LASER × LED. *An bras dermatol* 89: 616-623.
13. Juliana Santos G, Ransmiller da Silva RC, Dantas LMR (2016) Effects of Led and Laser in Venous Ulcers: Narrative Literature Review. *Interbio* 10: 34-40.
14. Bonatti S, Hochman B, Tucci-Viegas VM, Furtado F, Pinfildi CE, et al. (2011) *In vitro* effect of 470 nm LED (Light Emitting Diode) in keloid fibroblasts. *Acta Cir Bras* 26: 25-30.
15. Rodrigues PF, Ferreira JB, Carvalho CM, de Jesus Pinto W (2017) Efeito do laser HeNe na cicatrização de feridas diabéticas em ratos. *Revista Eletrônica Acervo Saúde* 9: 1167-1173.
16. Avci P, Gupta A, Sadasivam M, Vecchio D, Pam Z, et al. (2013) Low-level laser (light) therapy (LLLT) in skin: stimulating, healing, restoring. *Semin Cutan Med Surg* 32: 41-52.
17. Zhang Y, Zhu Y, Gupta A, Huang Y, Murray CK, et al. (2014) Antimicrobial Blue Light Therapy for Multidrug-Resistant *Acinetobacter baumannii* Infection in a Mouse Burn Model: Implications for Prophylaxis and Treatment of Combat-related Wound Infections. *J Infect Dis* 209: 1963-1971.
18. Dourado KBV, Carnevali Junior LC, de Paulo RJF, Gomes AC (2011) LEDTERAPIA: Uma nova perspectiva terapêutica ao tratamento de doenças da pele, cicatrização de feridas e reparação tecidual. *Ensaio e Ciência* 15: 231-248.
19. Dai T, Gupta A, Huang YY, Yin R, Murray CK, et al. (2013) Blue light rescues mice from potentially fatal *Pseudomonas aeruginosa* burn infection: efficacy, safety, and mechanism of action. *Antimicrob Agents Chemother* 57: 1238-1245.
20. Enwemeka CS, Williams D, Hollosi S, Yens D, Enwemeka SK (2008) Visible 405 nm SLD light photo-destroys methicillin-resistant *Staphylococcus aureus* (MRSA) in vitro. *Lasers Surg Med* 40: 734-737.
21. Quilici MTV, de Sa Del Fiol F, Vieira AEF, Toledo MI (2016) Risk Factors for Foot Amputation in Patients Hospitalized for Diabetic Foot Infection. *J Diabetes Res* 2016: 1-8.
22. Hamblin MR (2017) Mechanisms and applications of the anti-inflammatory effects of photobiomodulation. *AIMS Biophys* 4: 337-361.
23. Guffey JS, Wilborn J (2006) *In Vitro* Bactericidal Effects of 405-nm and 470-nm Blue Light. *Photomed Laser Surg* 24: 684-688.
24. Beckmann KH, Meyer-Hamme G, Schröder S (2014) Low Level Laser Therapy for the Treatment of Diabetic Foot Ulcers: A Critical Survey. *Evid Based Complement Altern Med* 2014: 626127.
25. Fukuda TY, Malfatti CA (2008) Analysis of low-level laser therapy doses in Brazilian equipment. *Rev Bras Fisioter* 12: 70-74.
26. Moskvina SV (2017) Low-Level Laser Therapy in Russia: History, Science and Practice. *J lasers med sci* 8: 56-65.
27. Bertolini GRF, Da Silva TS, Ciena AP, Da Trindade DL (2008) Effects of the Low Level Laser Over Pain and Edema in Tendon Trauma of Rats. *Rev Bras Med do Esporte* 14: 362-366.
28. Adamskaya N, Dungal P, Mittermayr R, Hartinger J, Feichtinger G, et al. (2011) Light therapy by blue LED improves wound healing in an excision model in rats. *Injury* 42: 917-921.
29. Brechow A, Slesaczek T, Münch D, Nanning T, Paetzold H, et al. (2013) Improving major amputation rates in the multicomplex diabetic foot patient: focus on the severity of peripheral arterial disease. *Ther adv endocrinol metab* 4: 83-94.