

# Pattern of Pubertal Changes in Congenital Adrenal Hyperplasia Patients, with Idiopathic Central Precocious Puberty; Case Report

Naglaa Fathy Barseem<sup>1\*</sup> and Mona F El-Samalehy<sup>2</sup>

<sup>1</sup>*Pediatric Department, Faculty of Medicine, Menoufia University, Egypt*

<sup>2</sup>*Department of pediatric, Faculty of Medicine, Menoufia University, Egypt*

\*Corresponding author: Naglaa Fathy Barseem, Department of Pediatric, Faculty of Medicine, Menoufia University, Egypt, E-mail: [Naglaa\\_b2000@yahoo.com](mailto:Naglaa_b2000@yahoo.com)

Received date: 26 Nov 2015; Accepted date: 26 Jan 2016; Published date: 01 Feb 2016.

Citation: Barseem NF, El-Samalehy MF (2016) Pattern of Pubertal Changes in Congenital Adrenal Hyperplasia Patients, with Idiopathic Central Precocious Puberty; Case Report. *Int J Endocrinol Metab Disord* 2(1): doi <http://dx.doi.org/10.16966/2380-548X.121>

Copyright: © 2016 Barseem NF, et al. This is an open-access article distributed under the terms of the Creative Commons Attribution License, which permits unrestricted use, distribution, and reproduction in any medium, provided the original author and source are credited.

## Abstract

**Background:** Understanding the variation in progression from normal to precocious puberty is a matter of concern. Beside idiopathic central precocious puberty, CAH is an important cause of gonadotropin independent precocious puberty that requires a comprehensive treatment regimen to achieve normal growth and pubertal development.

**Aim of the work:** This study aimed to evaluate growth and pubertal changes in children with CAH. Also, to consider the idiopathic central precocious puberty.

**Patients and Methods:** Thirty three patients with classic 21 hydroxylase deficiency (14 SW and 19 SV CAH) enrolled in the study. They were assessed and followed up for growth and developmental characteristics. All patients were karyotyped and sex was determined, with recording of their hormonal profile and molecular genetic data, also treatment regimen was included.

**Results:** Mean age of pubertal onset was earlier in CAH patients; it was more evident in male patients. Sixteen of thirty three CAH patients showed signs of gonadotrophin independent Precocious puberty. At pubertal onset, mean Ht (SDS) appeared to be higher in boys especially with SV form ( $2.1 \pm 0.2$ ), than in girls ( $0.9 \pm 0.1$  in SW,  $0.9 \pm 0.03$  in SV). All those children had advanced bone age at onset of puberty and within average BMI (SDS) scores. None of CAH patients had 2ry central PP except for our case report of idiopathic central precocity who required GnRH treatment. Molecular genetic study for cyp21 revealed variable sized deletions in the structure of the gene in cases with CAH, where elevated levels of 17 OH P and testosterone were additionally observed.

**Conclusion:** Our results demonstrated that management of CAH is challenging. Genetic studies as well as clinical, hormonal and radiological evaluation will eventually help in treatment of cases and counseling of families.

**Keywords:** Growth; Precocious Puberty; Congenital Adrenal Hyperplasia; Cyp21; Gonadotrophin Releasing hormone

**List of Abbreviations:** 17 OHP: 17 hydroxy progesterone; ACTH: adrenocorticotrophic hormone; BMI: Body mass index; Bp: Base pair; CAH: Congenital adrenal hyperplasia; CT: Computerized tomography; cyp21: congenital adrenal hyperplasia results from steroid 21-hydroxylase cytochrome P-21; DHEA: dehydroepiandrosterone; DHT: Dihydrotestosterone; DNA: Deoxyribonucleic acid; dNTPs: Deoxynucleotide Triphosphates; F: Female; FSH: Follicular stimulating hormone; GnRH: Gonadotropin releasing hormone; Ht: Height; K: potassium; Kb: Kilo base; LH: Leutanizing hormone; M: Male; MRI: Magnetic resonance imaging; NA: Sodium; PCR: Polymerase chain reaction; PP: Precocious puberty; SV: Simple virilizing; SW: Salt wasting; Wt: Weight

## Introduction

Precocious puberty comprises a group of disorders that range from variants of normal development to conditions in which prompt diagnosis and therapy may be lifesaving. The line separating normal from abnormal onset of puberty represents children entering puberty more than 2.5 standard deviation earlier than average [1-3]. Precocious puberty can be classified as whether it is true or central; that is due to early but otherwise normal activation of hypothalamic pituitary gonadal axis, or pseudo precocious puberty i.e. for other causes due to production of gonadal steroids and if it is of the same or contra lateral sex [4]. An important cause of precocity in boys and girls is congenital adrenal hyperplasia (CAH) that refers to an autosomal recessive condition caused by enzymatic deficiency involving the steroidogenesis pathway [5]. The most common form of which is 21 hydroxylase deficiency; caused by mutations in cyp21 gene [6], this gene encoding human 21 (OH) (cyp21) is located at 6 p 21.3 within the HLA class III, of ten exons, approximately 30 Kb apart from its inactive pseudogene; (cyp21 p) with different mutations

within its structure and then malfunction [7]. The clinical phenotype is determined by the degree of enzymatic activity that includes the more severe salt wasting (SW) form, the less severe simple virilizing (SV) and the mild non- classic one [6]. Pubertal development seems to occur along a continuum from normal to precocious which implies the importance of etiological evaluation, together with close monitoring and follow-up of these children with either true or pseudo precocity and great direction towards counseling with their families [8].

## Aim of the Work

The aim of this work was to evaluate the pubertal changes in children with classical congenital adrenal hyperplasia, also, to take in consideration the importance of idiopathic central precocity.

## Patients and Methods

The present study was conducted on thirty three patients with CAH. They were selected from Genetics and Endocrinology unit, pediatric department, Menoufia university hospitals and Menoufia medical

Insurance hospital, Egypt. They were fifteen males and eighteen females (14 SW and 19 SV). Their ages ranged from one week to eleven years. All patients with classic 21 OH deficiency were being followed in our unit during the period from 2008 till near the beginning of 2016. Patients' demographic data, family pedigree construction, evaluation of growth and pubertal characteristics together with hormonal and biochemical profile were done, also included regimen of treatment, after obtaining a written consent from patients' families. Data were documented using report sheets. The studied patients were subjected to the following:

- **Full history taking** i.e, maternal medicational history, virilization symptoms, use of drugs, consanguinity, history of recurrent abortions, neonatal deaths or failure to thrive, vomiting, skin pigmentation or presence of similar conditions in the family [9].
- **A thorough clinical examination** including vital signs, skin examination for body hair distribution (hirsutism), abnormal pigmentation or signs of dehydration.
 

For anthropometric measurements, weight and height were individually measured at different ages. Body mass index (BMI SDS) was calculated from weight (kg) divided by height (m<sup>2</sup>) (Kg/m<sup>2</sup>) and expressed as SDS [10].
- **External genitalia examination** included:
  - Phallus: size, length, degree of differentiation, and location of the urethral meatus.
  - The scrotum or labia for: fusion or not of two halves of labioscrotal tissue or pigmentation.
  - Gonadal exam: with stress on their site; within or outside the labioscrotal tissue, their size and texture in apparent male cases.
  - Prader score application for degree of virilization in apparent female cases [11].
- **Pubertal assessment** by tanner staging and included exam. Of breasts in females, the external genitalia in males and pubic hair in both sexes. Breast Tanner stage 2 in girls and genital growth in boys, plus pubic hair Tanner stage 2 (PH2) were used as criteria for defining age at puberty. Abnormalities in pubertal development i.e precocious puberty were evaluated [12].
- **Bone age** was calculated from x- ray on Lt Wrist using the method described by Greulich and Pyle [13].
- **Preliminary routine investigations** i.e complete blood picture, serum electrolytes with stress on NA and K and blood glucose level were done for SW cases of CAH. [14].
- **Hormonal studies:** included serum 17 hydroxy progesterone (17 OH P), cortisol, adrenocorticotrophic hormone (ACTH), testosterone, Leutanizing hormone (LH), Follicular stimulating hormone (FSH). Dihydrotestosterone (DHT), dehydroepiandrosterone (DHEA) and rostandione were additionally done. All these hormones were correlated to normal reference ranges [15].
- **Imaging studies:** involved abdomino pelvic ultrasound, CT and/or MRI. Also, MRI brain was greatly helpful especially in the case of central precocity.
- **Molecular genetic studies:** for analysis of CYP 21 gene mutations in recent cases of patients with symptoms of classic 21 (OH) deficiency, with the following steps applied:
  - DNA extraction: genomic DNA was extracted from peripheral whole blood by DNA purification kit that uses a convenient spin column technology according to manufacture protocol (thermo scientific GeneJET Tm kit, # k0721 made in EU. Lithuania).

- Polymerase chain reaction: selective PCR amplification of the CYP 21 gene in two segments; where segment 1 represents a 1339-bp extended from exon 1 to exon 6 and segment 2 is a 2220-bp extended from 8-bp deletion in exon 3 to exon 10 according to Oriole et al. [16].

Each PCR reaction was performed with mixtures of 0,2 mg of genomic DNA, 2.5 μ of Taq DNA polymerase, 0.5 mmol/l of each forward and reverse primer, 100 mmol/l dNTPs, 3.0 mmol/l MgCl<sub>2</sub> and 1x PCR buffer to a final volume of 50 ml reaction volume. PCR cycling conditions were 5 min at 94.c for initial denaturation, followed by 35 cycles at 94.c for 1 min, 65.c for 1 min, and 72.c for 6 min, plus cycle elongation of 2 s for each cycle, and 72.c for 15 min for final extension. PCR was performed using an automated thermal cycler (Bio- Rad MJ Research PTC-200 DNA Engine thermal cycler).

- Primer sequence used for amplification of the two segments of the studied gene were [16]:

For segment (1):

p1 (5' TCGGTGGGAGGGTACCTGAAGGT'3)  
 p2 (5' GCATCTCCACGATGTGAT'3).

For segment (2):

p3 (5' CCGGACCTGTCCTTGGGAGACTACT'3)  
 P4 (5' CTGAGCGGCTGGGTGAAATGGAAC'3)

- The PCR reaction products were electrophoresed in an automated ABI prism sequencer (applied biosystems). For amplification of a corresponding exon, allele specific primers were used as previously described [17]. Results were analyzed with free software gene marker 1.6 (Soft Genetics, State College, PA, USA).

## Results

### Results of this study were illustrated in tables and figures

Patients with classic 21 OH Deficiency were enrolled and followed up. They included (15 boys, 18 girls). Fourteen patients had SW-CAH, and nineteen patients had SV-CAH. Sixteen patients had entered puberty, two cases reached final height. The age at presentation ranged from weeks up to eleven years. Consanguinity was evident in eleven cases, while FH of CAH was observed in nine cases. Three cases had other siblings affected with CAH. These baseline characteristics were shown in table 1. Tables 2 and 3 showed clinical and anthropometric parameters of patients with classic 21 OH deficiency, in addition to changes regarding age at puberty, bone age advancement and need for GnRH treatment for cases who entered puberty, while, biochemical hormonal profile, imaging and results of molecular genetic studies were shown in table 4. External genital manifestations in female patients showed variable degrees of virilization (prader score 1-3) was mainly clitoromegaly with fused labia and no palpable gonads. For male patients, external genitalia showed skin pigmentation, normal male external genitalia with variable length of penis and palpable gonads. All patients had elevated levels of 17 OH P and testosterone during their pubertal period. Results of genetic study were shown in table 3. Pelvi-abdominal imaging studies revealed internal female genitalia in all genetic females; on the other hand, all genetic males had no internal female genital organs. Normal MRI findings were present in the case report of idiopathic central precocity. For growth at onset of puberty, mean Ht (SDS) was higher in SV boys (SV 2.1 ± 0.2, SW 1.1 ± 0.04) than girls (SV 0.9 ± 0.03, SW 0.9 ± 0.1). BMI (SDS) was within average in both sexes of CAH. Tanner stage (PH2) occurred at mean age of; (in boys SV 5.8 ± 0.1, SW 6.8 ± 0.1), and (SV 7.1 ± 0.3, SW 8.6 ± -0.02 in girls) respectively, and earlier age of onset of puberty.

Pattern	Gender by karyotype	No.	Age at diagnosis (m) median (range)	Age at examination (y) median (range)	Puberty (No.)
Salt wasting	M	8	0.6 (0.3 - 5)	6.8 (0.8 - 11)	3
	F	6	0.4 (0.4 - 3)	9 (4.2 - 10)	5
Simple virilizing	M	7	32 (48 - 55)	7.8 (6.2 - 9)	2
	F	12	11 (0.2 - 42)	8.0 (7.3 - 11)	6

Table 1: Baseline characteristics of patients with classic 21 OH deficiency

Pattern	Sex	No.	Ht (SDS)		Wt (SDS)		BMI (SDS)	
			2 y (No.)	2 y (No.)	Pub. (No.)	2 y (No.)	Pub. (No.)	
SW	M	8	0.70 ± 1.02 (2)	1.02 ± 0.5 (2)	1.26 ± 1.2 (3)	1.34 ± 1.02 (2)	1.4 ± 0.7 (3)	
	F	6	0.4 ± 1.2 (2)	-0.3 ± 0.8 (2)	0.8 ± 0.3 (5)	0.8 ± 1.2 (2)	0.9 ± 1.01 (5)	
SV	M	7	1.4 (1)	0.72 (1)	1.7 (2)	2.03 (1)	1.85 (2)	
	F	12	1.35 ± 0.4 (5)	0.6 ± 0.4 (5)	1.6 ± 0.03 (6)	0.8 ± 0.04 (5)	1.08 ± 0.4 (6)	

Table 2: Clinical data of patients with classic 21 OH deficiency

Case pattern	Sex	No.	Age of onset of puberty	Age of PH2	Ht (SDS) (mean ± SD)	BA-CA at puberty	Need for GnRH treatment
CAH	M	3	6.4 y ± 0.1	6.8 y ± 0.1	1.1 ± 0.04	2.4 ± 1.1	-
SW	F	5	8.3 y ± 0.2	8.6 y ± 0.02	0.9 ± 0.1	2.3 ± 0.4	-
CAH	M	2	7.1 + -0.4 y	5.8 y ± 0.1	2.1 ± 0.2	3.2 ± 0.2	-
SV	F	6	6.9 + -0.2 y	7.1 y ± 0.3	0.9 ± 0.03	2.6 ± 0.4	-
GDPP	M	1	2.5 y	2.8 y	1.3	2.3	+ ve
	F	1	9 months	10 ms	0.9	2	+ ve

Table 3: Pubertal changes in patients with precocious puberty

BA-CA: Bone age–Chronological age.

GnRH: Gonadotrophin releasing hormone

No.	Phenotypic presentation	Tanner stage	Serum k level	Hormonal findings						Imaging studies	Genetic studies	Diagnosis
				ACTH pg/ml		Cortisol µg/dl		17 OH P ng/ml	Others			
				AM	PM	A.M	P.M					
1.	Precocious puberty, clitoromegaly and deepening of voice	B1 P3 A1	5.4	64	78	1.7	1.3	16.2	-	Internal female genital organs	V281L mutation	CAH-SV with GI PP
2.	Clitoromegaly	B1 P1 A1	5.2	112	81	1.1	0.9	13.8	-	Internal female genital organs	Deletion mutation in exon 10	CAH-SV
3.	Clitoromegaly	B1 P1 A1	4.3	53	62	2.0	0.8	14.6	-	Internal female genital organs	Deletion mutation in exon 10	CAH-SV
4.	Abnormal hair growth and distribution	B1 P3 A1	5.2	138	62	2.1	1.6	15.8	-	Internal female genital organs	V281L mutation	CAH-SV
5.	Recurrent attacks of vomiting, abnormal skin pigmentation	B1 P1 A1	4.6	117	82	1.9	2.1	25.1	DHEA 152 ng/dl	Internal female genitalia	Large deletion mutation	CAH-SW
6.	Ambiguous genitalia, abnormal hair growth	B1 P1 A1	5.2	168	94	1.6	2.2	31.2	DHEA 82 ng/dl, androstendione 52 ng/dl	Female internal genitalia	Deletion mutation in exon 8	CAH-SV

7.	Recurrent attacks of vomiting	B1 P1 A1	5.4	218	74	1.5	1.8	18.9	DHEA 86.3 ng/dl	Internal female genital organs	Deletion mutation in exon 8	CAH-SW
8.	Precocious puberty(advanced external genital appearance with growth spurt)	P3 P2 A1	5.1	214	79	1.1	0.8	20.8	Testosterone 10.1 ng/ml, LH 0.21 U/L	No internal female genital organs	Large deletion mutation	CAH-SW presented with GIPP
9.	Dehydration attacks	P1 P1 A1	4.6	183	53	1.3	0.7	16.8		No internal female genitalia, bilateral labio-scrotal gonads	V281L mutation	CAH-SW
10.	Ambiguous genitalia	B1 P1 A1	5.2	58	51	1.1	0.6	14.2		Internal female genital organs	Deletion mutation involving part of exon 9 a.a 424 to exon 10	CAH-SV
11.	Ambiguous genitalia	B1P1A1	4.9	132	87	1.4	1.1	18.6		Normal female genitalia	Normal genotype	CAH-SV
12.	Dehydration attacks skin pigmentation	P1 P1 A1	4.6	216	74	1.6	0.8	10.8	Androstendione 46.8 ng/dl, testosterone 0.4 ng/ml	No internal genitalia of females, bilateral labio-scrotal gonads	Deletion mutation involving part of exon 9 a.a 424 to exon 10	CAH-SW
13.	Clitoromegaly with recurrent attacks of vomiting	B1 P1 A1	4.3	58	46	1.2	0.7	20.1 -	-	Visible female internal genitalia	Large Deletion mutation involving exon 7 a.a 289 to exon 10	CAH-SW
14.	Precocious puberty with early puberche	BI P3 A2	5.1	85	54	1.4	1.1	14.8		Internal female genitalia with visible uterus and ovaries	Large Deletion mutation	CAH-SV, With GIPP
15.	Clitoromegaly, abnormal skin pigmentation	B1 P1 A1	5.1	87	53	2.1	1.0	16.3		Female internal genital organs	Deletion mutation in exon 10	CAH-SV
16.	Precocious puberty, pigmented skin	P2 P2 A1	4.9	212	86	1.4	1.2	17.9	Testosterone 10.04 ng/dl	No internal female genital organs, bilateral labio-scrotal gonads	Large Deletion mutation	CAH-SV,GIPP
17.	Precocious puberty, abnormal hair growth	P2 P2 A1	5.1	206	92	1.2	0.8	15.2	DHEA,62 ng/dl, testosterone 10.2 ng/ml	No internal female genital organs, bilateral labio-scrotal gonads	Deletion mutation in exon 10 a.a 413-487	CAH-SV ,GIPP
18.	Precocious puberty, hirshutism	B1 P3 A2 with menarche at age of 11.2 y	5.4	216	84	1.1	0.7	16.3	-	Female internal genital organs	Deletion mutation involving part of exon 9 a.a 424 to exon 10	CAH-SV,GIPP
19.	Precocious puberty	B1 P2 A1	4.8	182	67	1.3	0.8	17.2	Testosterone 0.5 ng/dl, LH 0.2 IU/L	No internal female genital organs, bilateral labio-scrotal gonads	Deletion mutation in exon 10 a.a 413-487	<b>CAH-SW,GIPP</b>

**Table 4:** Summarized data of patients underwent molecular study

**CAH:** Congenital adrenal hyperplasia

**GIPP:** gonadotrophin independent precocious puberty

**a.a:** amino acid

**SW:** Salt Wasting

**SV:** Simple virilizing



Added to these cases of CAH, one case report of gonadotrophin-dependent precocious puberty where; 9 month - aged female patient, the second to a mother aged 26 yrs and father of 36 yrs. The first sibling is 3 year-aged normal boy with irrelevant family history of similar conditions, complained of mother's notification of vaginal bleeding which started at the age of 6 months with no history of trauma. According to mother's statement, there was normal vaginal delivery, no history of incubation, and average birth weight. No minor or major anomalies were present. Regarding the vaginal bleeding, it stayed for about 4 days, and recurred again. This finding was preceded by appearance of pubic and scanty axillary hair but it did not make sense to the mother until the occurrence of vaginal bleeding, for which the mother sought medical advice and the patient was investigated. On examination, she had unremarkable neurological findings, non palpable thyroid gland, absent skin pigmentation. Examination of the breast revealed enlarged both breasts with firm consistency and developed nipple and areola, no discharge (Figures 1 and 2). As regard anthropometric measurements; she weighed 10 kg (0.8 SDS), her length was 75 cm (2 SD for age), corresponding to 0.9 SDS. She had tanner stage of A1 P2 B3 with two attacks of vaginal bleeding. Pelvic abdominal ultra sound showed adult sized uterus with pubertal size, shape and proportions, thin endometrial central line and

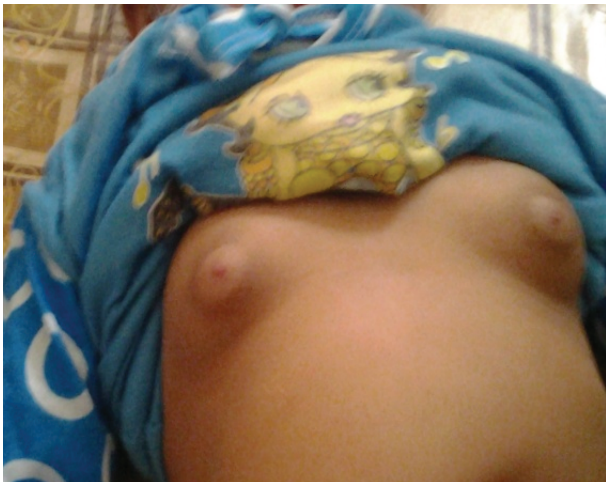uterine length of 43 mms (enlarged for age; i.e length >34 mms). In this scan, both ovaries are pubertal with bilateral (almost adult sized) follicular pattern, no related masses or cysts. Skeletal maturation was assessed by x-ray on Lt wrist, using Greulich and pyle [13]; the bone age of the patient was at 2 years (Figure 3) which is greater for her chronological age. MRI of the brain was done and no abnormalities were detected. As for hormonal assay, serum estradiol and LH, FSH levels were elevated and within the pubertal range; E2 was 48.0 pg/ml (ref. range 6.0-27.0), serum LH and FSH levels during GnRH stimulation test were 76.4 mIU/ml and 67.8 mIU/ml 4h post decapeptyl respectively.

All investigations came to a belief that this patient had idiopathic central precocious puberty. After counseling with her parents we started treatment in the form of GnRH agonist; Sc injection of decapeptyl 3.6 mg every 4 weeks to be continued for 11 years of her age and be followed up. Unless the patient started her medical treatment, she would be waiting for her third monthly interval of menstrual cycle. This case report emphasized how this condition should be evaluated through clinical, biological and radiological examination and properly managed.


## Discussion

Controversy is present about the normal age of onset of puberty in boys and girls [18-20]. In this study, the pubertal onset was significantly earlier in patients with both forms of CAH, compared with the observed normal reference [21]. Regarding growth in patients with CAH, ten patients aged less than 2 years; their Ht (SDS) was comparable to normal reference pattern in all groups of patients. This was not in accordance with Balsamo et al. [22]; who showed that in both sexes, the average length of patients with classic CAH was greater than the mean birth length in controls. He stated also, among CAH patients, those with SW form was longer but weighed less than those with SV form. On the other hand, in our study it was found that, at pubertal onset, mean Ht (SDS) appeared to be higher in boys especially those with SV form. Final height was reached in two female SV cases that were in the lower range of normal Egyptian females. This finding showed agreement with a multicenter analysis study which showed that pubertal growth is more impaired in patients with SV -CAH compared to SW- CAH patients [23].

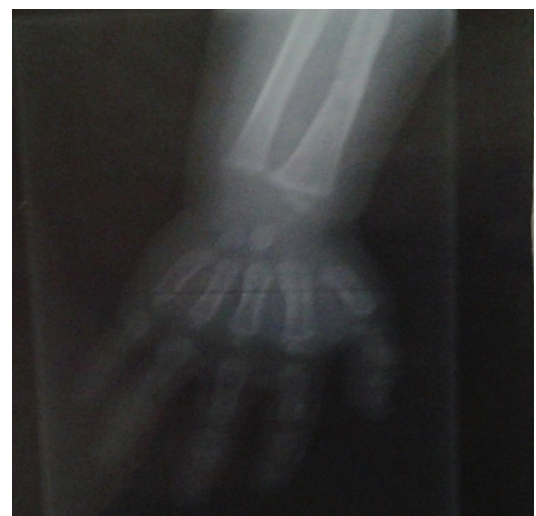About genital examination, Tanner stage revealed prepubertal testicular size of 3.5-4 ml, pubic hair stage 3 with slightly enlarged phallus in three pubertal male cases, plus breast stage 2 in pubertal girls with CAH. This is consistent with the findings of Emans and Jean [24] that clarified the



**Figure 1:** Photographs at 9 months of age showed breast development consistent with the degree of secondary sexual maturation.



**Figure 2:** Photographs at 9 months of age showed pubic hair development consistent with the degree of secondary sexual maturation.



**Figure 3:** Photograph showed osseous maturation, advanced for her chronological age.

hormonal effect on secondary sexual characters. Menarche occurred at the age of 11, 2 in two cases with SV form, which was comparable to reference age among Egyptian girls [21]. Most of our patients had advanced bone age at onset of puberty that might reflect the integrated effect of dose and duration of sex steroid action during pre-pubertal period which associated with poor height outcome. This is in accordance with Mogensen et al. [25]; who stated that CAH may result in rapid growth and precocious puberty with premature skeletal maturation. We found that none of our CAH patients had true precocious puberty so, did not require treatment with GnRH analogue; a consequence of excess of adrenal androgens, leading to early activation of the hypothalamic pituitary gonadal axis and occurrence of secondary central precocious puberty [26,27]. All patients in our study received hydrocortisone tablets according to our unit protocol and underwent follow-up measurement of 17 OHP and testosterone levels for treatment monitoring. These two steroids notably 17 OHP appeared to be markedly elevated during puberty; this is the basis of successful treatment of CAH which depends on achieving the delicate balance of suppressing adrenal androgen secretion while maintaining normal growth [27-29]. Family history was relevant in nine cases, so it is recommended that three- generational family pedigree and consanguinity should be obtained and structured. All of these are constant with the fact that CAH is autosomal recessive [30]. This emphasizes the importance of CAH screening programs together with molecular genetic testing especially when future pregnancies are anticipated.

The prevalence of different forms of CAH as well as their mutation pattern varies among ethnic populations Example of which are studies in Iran, Turkey, East India and Tunisia, where the latter showed high frequency of large deletions and Q318X mutations in Tunisian population [17].

As regard the molecular study for cyp 21 gene, variable sized deletions, observed in our patients, were the most relevant mutations. Substitution mutations (V 281 L) were found in three cases, despite its association for non – classic forms of CAH [31]. One case had normal genotype; 8-bp deletion mutation was not detected in our patients. These mutations in the gene caused alterations in the function which ultimately affected enzyme activity of 21 OH, of which its deficiency is the commonest cause of CAH [32,33]. As in our case reports, several reports showed that although the rarity of the constitutional type of central precocity, it should be kept in mind [34].

Precocious puberty is such a serious problem that girls and boys who began puberty long before their peers may be extremely self conscious about the changes occurring in their bodies. This may affect self- esteem and increase the risk of depression, so therapeutic approach remains to be determined [35].

## Conclusion

Continuous clinical practice shows variations in the expression of precocious puberty in children. Results of this study focused on the importance of monitoring of growth parameters and bone age as determinants of Precocious puberty, resulted from inadequate hormonal control of CAH with both clinical; SW and SV forms. These findings clarified that early diagnosis towards establishing effective screening program is crucial.

## References

1. Marshall WA, Tanner JM (1969) Variations in pattern of pubertal changes in girls. *Arch Dis Child* 44: 291-303.
2. Marshall WA, Tanner JM (1970) Variations in pattern of pubertal changes in boys. *Arch Dis Child* 45: 13-23.
3. Kaplowitz P (2011) Update on Precocious puberty: girls are showing signs of puberty earlier, but most do not require treatment. *Adv Pediatr* 58: 243-258.
4. Styne DM (1997) New aspects in the diagnosis and treatment of pubertal disorders. *Pediatr Clin North Am* 44: 505-529.
5. Speiser PW, Azziz R, Baskin LS, Ghizzoni L, Hensle TW, et al. (2010) Congenital adrenal hyperplasia due to steroid 21-hydroxylase deficiency: an Endocrine Society clinical practice guideline. *J Clin Endocrinol Metab* 95: 4133-4160.
6. White PC (2009) Neonatal screening for congenital adrenal hyperplasia. *Nat Rev Endocrinol* 5: 490-498.
7. Lee HH (2001) CYP21 mutations and congenital adrenal hyperplasia. *Clin Genet* 59: 293-301.
8. Sultan C, Gaspari L, Kalfa N, Paris F (2012) Clinical expression of precocious puberty in girls. *Endocr Dev* 22: 84-100.
9. Cohen-Bendahan CC, van de Beek C, Berenbaum SA (2005) Prenatal sex hormone effects on child and adult sex-typed behavior: methods and findings. *Neurosci Biobehav Rev* 29: 353-384.
10. Cole TJ, Bellizzi MC, Flegal KM, Dietz WH (2000) Establishing a standard definition for child overweight and obesity worldwide: international survey. *BMJ* 320: 1240-1243.
11. Prader A (1954) Genital findings in the female pseudohermaphroditism of the congenital adrenogenital syndrome; morphology, frequency, development and heredity of the different genital forms]. *Helv Paediatr Acta* 9: 231-248.
12. Tanner JM, Davies PS (1985) Clinical longitudinal standards for height and height velocity for North American children. *J Pediatr* 107: 317-329.
13. Greulich WW, Pyle SI (1959) Radiographic atlas of skeletal development of the hand and wrist. 2nd edition, Stanford University Press.
14. Lee PA, Houk CP, Ahmed SF, Hughes IA (2006) Consensus statement on management of intersex disorders. International Consensus Conference on Intersex. *Pediatrics* 118: e488-e500.
15. Speiser P, White PC (2003) Congenital adrenal hyperplasia. *N Engl J Med* 349: 776-788.
16. Oriola J, Plensa I, Machuca I, Pavia C, Rivera-Fillat F (1997) Rapid screening method for detecting mutations in the 21-hydroxylase gene. *Clin Chem* 43: 557-561.
17. Rabbani B, Mahdieh N, Ashtiani MT, Larjani B, Akbari MT, et al. (2012) Mutation analysis of the CYP21A2 gene in the Iranian population. *Genet Test Mol Biomarkers* 16: 82-90.
18. Herman-Giddens ME, Slora EJ, Wasserman RC, Bourdony CJ, Bhapkar MV, et al. (1997) Secondary sexual characteristics and menses in young girls seen in office practice: a study from the Pediatric Research in Office Settings network. *Pediatrics* 99: 505-512.
19. Rosenfield RL, Bachrach LK, Chernausk SD, Gertner JM, Gottschalk M, et al. (2000) Current age of onset of puberty. *Pediatrics* 106: 622-623.
20. Midyett LK, Moore WV, Jacobson JD (2003) Are pubertal changes in girls before age 8 benign? *Pediatrics* 111: 47-51.
21. Ghaly I, Hussein FH, Abdelghaffar S, Anwar G, Seirvogel RM (2008) Optimal age of sexual maturation in Egyptian children. *East Mediterr health J* 14: 1391-1399.
22. Balsamo A, Wasniewska M, Di Pasquale G, Salzano G, Baronio F, et al. (2006) Birth length and weight in congenital adrenal hyperplasia according to the different phenotypes. *Eur J Pediatr* 165: 380-383.
23. Grigorescu-Sido A, Bettendorf M, Schulze E, Duncea I, Heinrich U (2003) Growth analysis in patients with 21-hydroxylase deficiency: influence of glucocorticoid dosage, age at diagnosis, phenotype and genotype on growth and height outcome. *Horm Res* 60: 84-90.
24. Emans S, Jean S (2000) Physical Examination of the Child and Adolescent. In: *Evaluation of the Sexually Abused Child A Medical Textbook and Photographic Atlas*. Oxford University Press 64-65.

25. Mogensen SS, Aksglaede L, Mouritsen A, Sørensen K, Main KM, et al. (2011) Diagnostic work-up of 449 consecutive girls who were referred to be evaluated for precocious puberty. *J Clin Endocrinol Metab* 96: 1393-1401.
26. Lin-Su K, Vogiatzi MG, Marshall I, Harbison MD, Macapagal MC, et al. (2005) Treatment with growth hormone and luteinizing hormone releasing hormone analog improves final adult height in children with congenital adrenal hyperplasia. *J Clin Endocrinol Metab* 90: 3318-3325.
27. Longui CA, Kochi C, Calliari LE, Modkovski MB, Soares M, et al. (2011) Near-final height in patients with congenital adrenal hyperplasia treated with combined therapy using GH and GnRH $\alpha$ . *Arq Bras Endocrinol Metabol* 55: 661-664.
28. Quintos JB, Vogiatzi MG, Harbison MD, New MI (2001) Growth hormone therapy alone or in combination with gonadotropin-releasing hormone analog therapy to improve the height deficit in children with congenital adrenal hyperplasia. *J Clin Endocrinol Metab* 86: 1511-1517.
29. Cabrera MS, Vogiatzi MG, New MI (2001) Long term outcome in adult males with classic congenital adrenal hyperplasia. *J Clin Endocrinol Metab* 86: 3070-3078.
30. Finkelstein GP, Chen W, Mehta SP, Fujimura FK, Hanna RM, et al. (2011) Comprehensive genetic analysis of 182 unrelated families with congenital adrenal hyperplasia due to 21-hydroxylase deficiency. *J Clin Endocrinol Metab* 96: 161-172.
31. Bizzarri C, Crea F, Marini R, Benevento D, Porzio O, et al. (2012) Clinical features suggestive of non-classical 21-hydroxylase deficiency in children presenting with precocious pubarche. *J Pediatr Endocrinol Metab* 25: 1059-1064.
32. Ella SSA, Tawfeek MAM, Ellahony DM, Anees NM (2012) Cytogenetic and molecular study in intersex. *The Egyptian Journal of Medical Human Genetics* 13: 281-289.
33. Pajkrt E, Chitty LS (2004) Prenatal gender determination and the diagnosis of genital anomalies. *BJU Int* 93: 12-19.
34. Akhtar H, Guha K, Nahar Z (2008) Precocious puberty: A case report. *TAJ* 21: 177-179.
35. Bunraungsak S, Klomchan T, Sahakitrungruang T (2013) Growth pattern and pubertal development in patients with classic 21-hydroxylase deficiency. *J Asian Biomedicine* 7: 787-794.