

Ingestion of Sharp Foreign Objects: A Case Series, Literature Review and Management Recommendation

Hendry K¹, Glue P², Hill J¹ and Schultz M1,^{3*}

¹Gastroenterology Unit, Dunedin Hospital, Southern District Health Board, Dunedin, New Zealand

²Department of Psychological Medicine, Dunedin School of Medicine, University of Otago, Dunedin, New Zealand and

³Department of Medicine, Dunedin School of Medicine, University of Otago, Dunedin, New Zealand

*Corresponding author: Michael Schultz, Associate Professor, Department of Medicine, Dunedin School of Medicine, University of Otago, PO Box 19, Dunedin, New Zealand, E-mail: michael.schultz@otago.ac.nz

Received date: 30 April, 2015; Accepted date: 13 May, 2015; Published date: 20 May, 2015.

Citation: Hendry K, Glue P, Hill J, Schultz M (2015) Ingestion of Sharp Foreign Objects: A Case Series, Literature Review and Management Recommendation. J Gastric Disord Ther 1 (1): doi <http://dx.doi.org/10.16966/2381-8689.101>

Copyright: © 2015 Hendry K et al. This is an open-access article distributed under the terms of the Creative Commons Attribution License, which permits unrestricted use, distribution, and reproduction in any medium, provided the original author and source are credited

Abstract

Background: Current guidelines on the management of ingested sharp objects recommend the endoscopic removal of sharp objects from proximal to the pylorus and close monitoring for those that have progressed beyond the pylorus. The most recent guidelines focus primarily on the nature of the ingested object, disregarding the patient, have changed little since the 1990s and are based on, in general, low quality evidence.

Case series: This is a case series of ten separate attendances to the Emergency Department by four patients with accidental or deliberate ingestion of sharp objects. Three patients with a history of deliberate self-harm and borderline personality disorder, known to psychiatric services, had ingested a variety of objects including safety razor blades (up to 20), pencils and a tooth brush. The fourth patient accidentally swallowed a pencil sharpener. Radiologically identifiable foreign objects below the gastro-oesophageal junction were seen in all cases. Five cases proceeded to endoscopy. In two all of the foreign objects were removed. One case proceeded to gastrotomy with subsequent post-operative complications. As the series progressed we switched to a more conservative approach favouring observation and earlier discharge without intervention. No complications resulting from the foreign objects were identified during a follow-up period of up to 4 months. Psychological management also changed including avoidance of restrictive interventions, such as use of the Mental Health Act, and approaches enhancing coping mechanisms were emphasized. Another important aspect to management was more focus on interdisciplinary support, liaison and education between medical, surgical and psychiatric teams.

Introduction

The management of individuals who have swallowed sharp objects is challenging. There are published guidelines on the management of foreign body ingestion [1-3], which typically depends upon the object ingested – size, shape and, importantly, the location of the object within the GI tract at time of presentation to medical services. Ingestion of foreign bodies can be accidental - predominantly children, or deliberate - occurring more commonly in adults. Death rates from foreign body ingestion appear to be extremely low (one reported death from case series of 3058 individuals) [1,4-10]. This figure is much lower than the 1500 deaths per year in the US previously reported in the literature which date back to the 1970s [4,11-13,15]. Reasons for deliberate ingestion of foreign material include psychiatric illness, mental retardation, secondary gain (e.g. in prison populations), and alcohol intoxication [2]. Four major aetiologies have been identified in patients with primary psychiatric disorders who ingest foreign bodies - psychosis, malingering, pica and borderline personality disorder [14] - each of which have different management strategies. A review of management strategies [11] identified a range of different therapeutic approaches (medication, behavioural and psychological techniques), however the applicability of these findings is limited because they relate mainly to case reports or small case series. Because of its sporadic nature, it is also not possible to accurately estimate the frequency of foreign body ingestion in psychiatric patients.

Guidelines exist to aid with management of ingested foreign bodies [3] however much of the evidence for the guidelines is low quality and taken from publications dating back to the 1920s [1,3]. These guidelines do mention specific issues with regard to mentally incompetent patients

and timing of consent but do not discuss other issues around psychiatric patients and those seeking secondary gain. Intervention for these conditions may encourage or reinforce their behaviour and can lead to multiple re-attendances with deliberate ingestion.

Appropriate management depends upon ascertaining as much information as possible regarding the foreign body ingestion. A verbal history from the patient may give details of the circumstances around ingestion, the type and number of objects ingested, the time of ingestion and symptoms suggesting impending complications. A past history of luminal gut disorders or interventions that may influence the presence of anatomical abnormalities needs to be taken into account. The number of objects, their type, size, shape, structure and whether they would be expected to be seen on x-rays will help in deciding the appropriate intervention. Examination is important to exclude signs of perforation which would require a surgical approach. Abdominal and chest x-rays may help define the location of the object and help exclude complications. According to the current ASGE guidelines [3] objects located in the oesophagus require endoscopic intervention immediately if causing oesophageal obstruction, are sharp or if the object is a disk battery. Urgent endoscopy should be considered for all other objects within the oesophagus, for sharp-pointed objects in the stomach or duodenum and objects >6 cm long at or above the proximal duodenum. Non-urgent endoscopy is advised in asymptomatic patients who have coins remaining in the oesophagus for more than 24 hours, objects wider than 2.5 cm or batteries that remain in the stomach for more than 48 hours. Magnets are an additional concern. If swallowed in number they can stick together, trapping mucosa between them, preventing natural passage with increasing risk of mucosal injury. If within reach, endoscopic removal

should be attempted. These recommendations aim to limit the risks of perforation, mucosal damage or obstruction. Any item not discussed above will usually pass safely once past the oesophagus [1-4,12,15,16].

We present a case series of four individuals who ingested foreign objects and the management of 10 presentations to the Emergency Department over a 4 month period. Six of these presentations involved the same patient. Based on our experience we propose a more differentiated approach to these individuals with consideration of their underlying psychiatric condition.

Case Series

Patient 1

A 19 year old female presented to the Emergency Department six times between April and July 2013. On each occasion she had been an inpatient under psychiatric services for a diagnosis of BPD. She had multiple previous attendances to the Emergency Department with deliberate self-harm including overdoses and cutting of her forearms.

Attendance 1: The patient deliberately ingested eight safety razor blades after dismantling safety razors and extracting the blades from the plastic mouldings. She had no acute symptoms and a normal examination. An abdominal x-ray obtained 2 hours after ingestion showed several foreign objects in the stomach (Figure 1).

At gastroscopy, a gastric food bolus consisting of an orange and containing visible blade was identified and some mucosal damage was noted within the stomach. Only one blade could be removed due to inadequate endoscopic views and the patient proceeded to surgery, undergoing gastrotomy with removal of the food bolus and remaining blades. She remained in hospital for 6 days, during which time there was initial failure to remove a urinary catheter placed pre-operatively, and subsequent catheter-associated urinary tract infection for which she required antibiotics. She was discharged back to psychiatric services. Following suture removal, she re-attended the Emergency Department having re-opened her surgical incision to a depth of between 5-10mm with a pencil sharpener blade.

Attendance 2: The patient claimed to have ingested two razor blades and a pencil sharpener blade. This was confirmed radiologically. One blade was removed endoscopically from the stomach; a second blade seen in the duodenum could not be retrieved. She was transferred to the surgical services and monitored for 8 days. During this time she managed to ingest a further 2 razor blades after absconding from the ward. Sequential abdominal x-rays showed passage of objects through the bowel. She was discharged to psychiatric services without sustaining any complications.

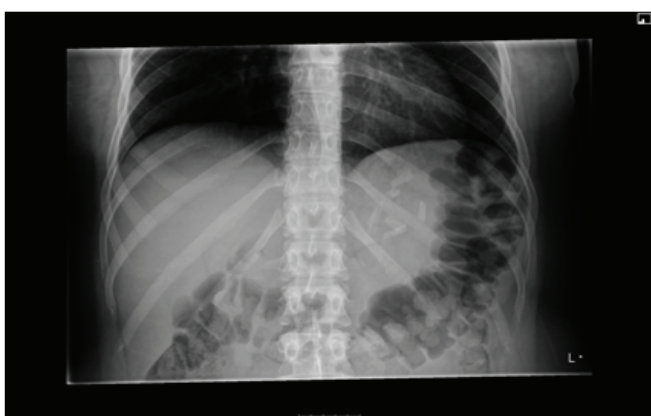


Figure 1: A radiograph highlighting multiple razor blades in the stomach of patient 1.

Attendance 3: The patient claimed to have ingested 20 razor blades whilst on leave from the psychiatry ward. 16 blades were identified in the stomach (Figure 2).

The patient proceeded to endoscopy and 10 razor blades were removed. The rest were obscured within a food bolus. The patient was observed for 12 hrs and discharged to psychiatric services without further serial x-rays. No subsequent abdominal complications were reported.

Attendance 4: The patient swallowed three sewing pins which were all located in the stomach at presentation. The patient was returned back to psychiatric services without intervention.

Attendance 5: The patient claimed to have swallowed 8 razor blades over the 8 hours prior to presentation. Two blades were seen in the duodenum on abdominal x-ray. The patient was observed overnight and discharged the next day to psychiatric services.

Attendance 6: The patient claimed to have swallowed 20 razor blade fragments from 10 whole blades. There were no significant findings on examination. Multiple blades were seen in the stomach. The patient was discharged from the Emergency Department back to psychiatric services without intervention.

Patient 2

A 15 year old male with no prior psychiatric diagnosis accidentally swallowed a pencil sharpener blade he had held in his mouth to prevent a friend from self-harming. He accidentally swallowed the blade after sneezing. He presented to the Emergency Department almost 24 hours later. No abdominal pain was reported but there were two episodes of loose bowel motions. The blade was easily identified within the small bowel. He was observed overnight and discharged home the following day.

Patient 3

A 20 year old female admitted from the psychiatric services having deliberately ingested six razor blades. She had a history of deliberate self-harm and BPD. She had mild upper abdominal discomfort at presentation. Observations were within normal limits with no evidence on examination of perforation or haemorrhage. Abdominal x-ray showed six blades in the stomach. All 6 blades were removed endoscopically. She was observed overnight and discharged back to the psychiatric services the next day. She returned several days later with a further deliberate ingestion of a razor blade broken into 6 fragments she had ingested approximately 4 hours before presentation. An initial report suggested she may have ingested synthetic cannabis around the same time. Again she had some mild epigastric discomfort on history. Observations were stable with no suspicion of a perforation or major haemorrhage. An x-ray suggested the fragments were distal to the stomach and she was discharged the same day.

Patient 4

A 21 year old female with a history of deliberate self harm presented to the Emergency Department having swallowed an adult toothbrush two days prior and 3 pencils on day of presentation. She had some abdominal pain. Abdominal x-rays showed the outline of the pencils in the stomach (Figure 3).

She underwent an endoscopy under general anaesthetic and the pencils were removed (Figure 4). The toothbrush could not be removed at the time but was subsequently removed endoscopically the following morning before the patient was discharged to psychiatric services.

Discussion

The presentation of patients who have ingested sharp objects can be

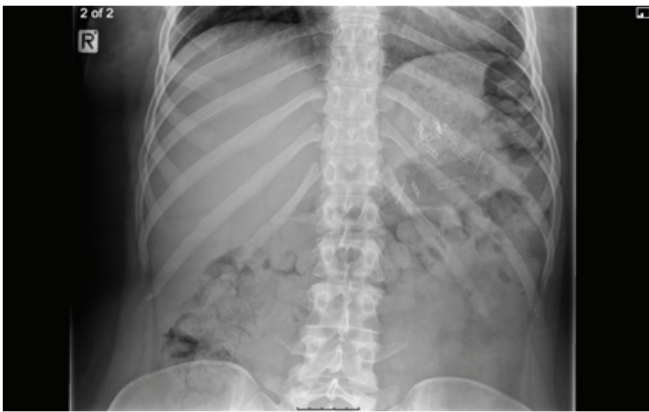


Figure 2: Radiograph showing multiple razor blades in the stomach of patient 1 on her third attendance to the Emergency Department.

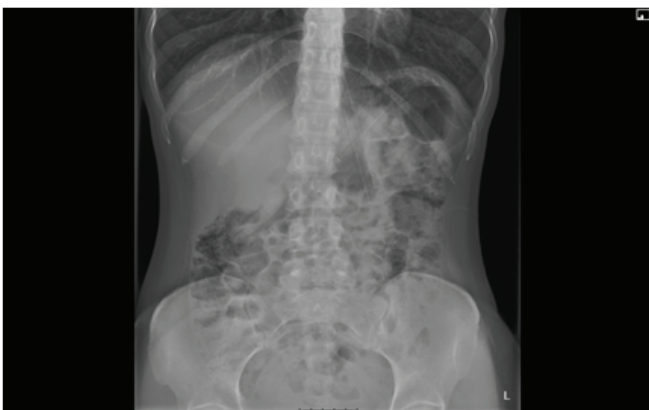

Figure 3: Radiograph showing several linear foreign objects in the stomach of patient 4 in keeping with the ingested pencils and toothbrush.

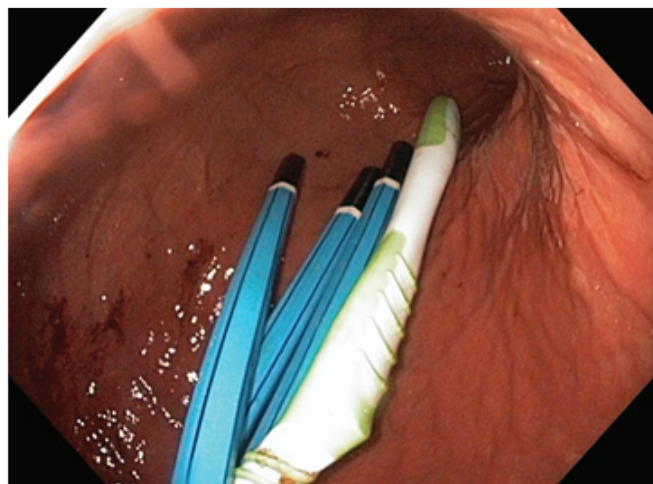


Figure 4: Endoscopic view of three pencils and a toothbrush in the stomach of patient 4.

challenging for the medical specialities involved. Most recent guidelines suggest removal if the object is located proximal to the pylorus, particularly if sharp, wide or long. Removal is also suggested if the object is in the duodenum but its dimensions make spontaneous passage unlikely. However, the guidelines merely take the specifications of the object into account with no regard to the underlying motivation of the patient.

In this case series, our experience of dealing with sharp object ingestion has evolved with the multiple presentations within a short timeframe. Initially, management was directed towards the removal of the razor blades given they were sharp, may have had caused mucosal damage already and could cause perforation. The possibility that the swallowing of sharp objects represented attention seeking behaviour by the patient was not taken into account. Case 1/attendance 1 proceeded to endoscopy and then to gastrotomy to remove all blades seen in the stomach. The post operative recovery was complicated by initial failure to remove the urinary catheter, a catheter associated urinary tract infection and subsequent deliberate self harm requiring re-suturing of her surgical wound. Attempts at endoscopic removal were made in the subsequent 3 attendances for razor blades within the stomach with varying degrees of success. Despite this, no complications were reported for the blades that were not removed and all passed spontaneously. The following three attendances were treated even more conservatively with no attempts to remove the foreign objects seen in the stomach and without subsequent complications.

The final attendance (case 4/attendance 1) highlights that a conservative approach cannot be taken when the ingested objects are long and spontaneous passage unlikely to occur. These items were successfully removed at endoscopy in two procedures and the patient would have to have undergone surgery had the endoscopic approach failed.

This series demonstrates that the risks of psychiatric and medical complications of intervention are significant compared to the potential or theoretical risk associated with passage of the ingested sharp objects. An unforeseen complication was reinforcement of secondary gain, due to increased input from medical, surgical and psychiatric teams, and this also needs to be taken into account when determining a management strategy. Initial management of Patient 1 was restrictive involving application of the Mental Health Act. This approach was ultimately counterproductive and lead to further episodes of self-harm, and often created anxiety and frustration in nursing and medical staff caring for her post-operatively. Subsequently psychological management approaches also changed, avoiding restrictive interventions, and focussing instead on identification of negative emotions and enhancing coping mechanisms. Another important aspect was an emphasis on interdisciplinary support, liaison and education between medical, surgical and psychiatric teams. Prompt assessment and discharge, if deemed to be appropriate, reduces burden to hospital services, does not positively reinforce the behaviour and may make further attempts at foreign body ingestion less likely. This group of attendances formed a cluster of cases that we had not seen before in our gastroenterology service. On discussion with psychiatric services, patients 1, 3 and 4 knew each other and had taken example from another patient, not included here, who had sought medical attention for ingesting objects [17]. Following our change in management, the attendance rate from these individuals reduced significantly.

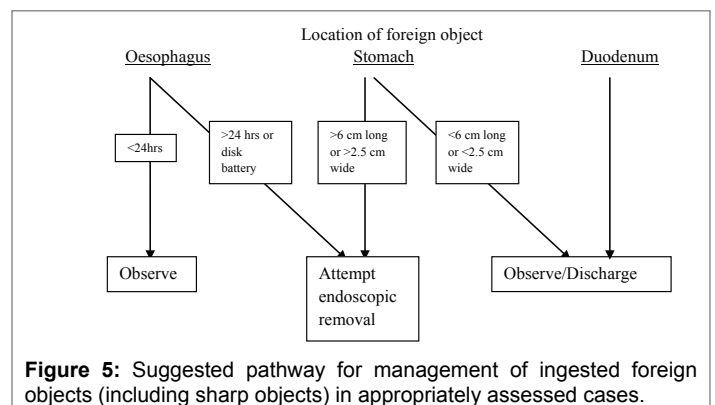


Figure 5: Suggested pathway for management of ingested foreign objects (including sharp objects) in appropriately assessed cases.

Conclusion

Our experience with this case series is that, in contrast to current guidelines, patients with deliberate ingestion of sharp objects, namely razor blades, which have dimensions that would be expected to negotiate the gastrointestinal tract naturally, can be treated conservatively. This approach minimises reinforcement of secondary gain, reduces risks from intervention and limits the burden on acute medical and surgical services. However, this approach does require active and continued communication between medical, surgical and psychiatric services to provide the patient with the required care either in the form of assessment and intervention for the underlying mental health issues and for any deterioration in physical health caused by the ingestion at a later stage.

We would recommend clinical assessment in the Emergency Department, radiological confirmation of the location and nature of the object(s) ingested and, if the patient is medically stable and the object is beyond the oesophagus, consideration for discharge without intervention with psychiatric support if required. A suggested flow chart for management of ingestion of foreign objects is suggested in Figure 5.

References

- Eisen GM, Baron TH, Dominitz JA, Faigel DO, Goldstein JL, et al. (2002) Guideline for the management of ingested foreign bodies. *Gastrointest Endosc* 55: 802-806.
- Ginsberg GG (1995) Management of ingested foreign objects and food bolus impactions. *Gastrointest Endosc* 41: 33-38.
- ASGE Standards of Practice Committee, Ikenberry SO, Jue TL, Anderson MA, Appalaneni V, et al. (2011) Management of ingested foreign bodies and food impactions. *Gastrointest Endosc* 73: 1085-1091.
- Webb WA (1995) Management of foreign bodies of the upper gastrointestinal tract: update. *Gastrointest Endosc* 41: 39-51.
- Chu KM, Choi HK, Tuen HH, Law SYK, Branicki FJ, et al. (1998) A prospective randomized trial comparing the use of the flexible gastroscope versus the bronchoscope in the management of foreign body ingestion. *Gastrointest Endosc* 47: 23-27.
- Velithkov NG, Grigorov GI, Losanoff JE, Kjossev KT (1996) Ingested foreign bodies of the gastrointestinal tract: retrospective analysis of 542 cases. *World J Surg* 20: 1001-1005.
- Cheng W, Tam PK (1999) Foreign-body ingestion in children: experience with 1265 cases. *J Pediatr Surg* 34: 1472-1476.
- Kim JK, Kim SS, Kim JI, Kim SW, Tang YS, et al. (1999) Management of foreign bodies in the gastrointestinal tract: an analysis of 104 cases in children. *Endoscopy* 31: 302-304.
- Hachimi-Idrissi S, Corne L, Vandenplas Y (1998) Management of ingested foreign bodies in childhood: our experience and review of the literature. *Eur J Emerg Med* 5: 319-323.
- Panieir E, Bass DH (1995) The management of ingested foreign bodies in children – a review of 663 cases. *Eur J Emerg Med* 2: 83-87.
- Poynter BA, Hunter JJ, Coverdale JH, Kempinsky CA (2011) Hard to swallow: a systematic review of deliberate foreign body ingestion. *Gen Hosp Psych* 33: 518-524.
- Palta R, Sahota A, Bemarki A, Salama P, Simpson N, et al. (2009) Foreign-body ingestion: characteristics and outcomes in a lower socioeconomic population with predominantly intentional ingestion. *Gastrointest Endosc* 69: 426-433.
- Schwartz GF, Polsky HS (1976) Ingested foreign bodies of the gastrointestinal tract. *Am Surg* 42: 236-238.
- Gitlin DF, Caplan JP, Rogers MP, Avni-Barron O, Braun I (2007) Foreign-body ingestion in patients with personality disorders. *Psychosomatics* 48:162-166.
- Ambe P, Weber SA, Schauer M, Knoefel WT (2012) Swallowed foreign bodies in adults. *Dtsch Arztebl Int* 109: 869-875.
- Blaho KE, Merigian KS, Winbery SL, Park LJ, Cockrell M (1998) Foreign body ingestions in the emergency department: case reports and review of treatment. *J Emerg Med* 16: 21-26.
- Dyke J, Hendry K, Hill J, Schultz M, Glue P (2014) Management of a Cluster of Foreign Body Ingestion Incidents in Patients with Borderline Personality Disorder. *OJPsych* 2014.