

Ivabradine as an Effective Heart Rate Controlling Agent in Coronary Computed Tomography Angiography: A Systematic Review

Sabarudin A*, Chan AL and Nasir NM

School of Diagnostic and Applied Health Sciences, Faculty of Health Sciences, Universiti Kebangsaan Malaysia, Kuala Lumpur, Malaysia

*Corresponding author: Sabarudin A, School of Diagnostic and Applied Health Science, Faculty of Health Science, Universiti Kebangsaan Malaysia, Jalan Raja Muda Abdul Aziz, 50300 Kuala Lumpur, Malaysia, Tel: +603-9289 7641; Fax: +603-2692 9032; E-mail: akmal.sabarudin@ukm.edu.my

Received date: 12 Mar 2016; Accepted date: 24 Mar 2016; Published date: 29 Mar 2016.

Citation: Sabarudin A, Chan AL, Nasir NM (2016) Ivabradine as an Effective Heart Rate Controlling Agent in Coronary Computed Tomography Angiography: A Systematic Review. *J Hear Health* 2(2): doi <http://dx.doi.org/10.16966/2379-769X.123>

Copyright: © 2016 Sabarudin A, et al. This is an open-access article distributed under the terms of the Creative Commons Attribution License, which permits unrestricted use, distribution, and reproduction in any medium, provided the original author and source are credited.

Abstract

We systematically reviewed the effectiveness of ivabradine to reduce heart rate prior to coronary computed tomography angiography (CCTA) examination. We collected articles from four databases (PubMed, Medline, Highwire Press, and Science Direct) published in English from January 2012 to February 2014. All studies involving ivabradine with a good image quality were included in this review. Only fifteen studies from seven literatures met the inclusion criteria and were included for analysis. Several premedication methods were used to evaluate the pharmacodynamics of ivabradine to reduce the patient's heart rate prior to CCTA examination ranging from a single dose to multiple doses of ivabradine and a combination of ivabradine and beta-blocker. Most literature agreed that the combination of ivabradine and beta-blocker resulted in a significant heart rate reduction (25.2%; 95% CI-22.8-28.9%) compared to either ivabradine alone (22.4%; 95% CI-18.0-24.3%) or beta-blocker alone (14.6%; 95% CI-9.0-21.1%). Although ivabradine results in better heart rate reduction than beta-blocker, a combination of both drugs provides an additive effect. With less side effects and better heart rate reductions, ivabradine can be applied clinically as an effective heart rate controlling agent in CCTA examination.

Keywords: Coronary CT angiography; Ivabradine; Beta-blocker; Heart rate reduction

Introduction

Coronary artery disease (CAD) leads to high mortality among men and women, especially in developed countries [1]. Various imaging modalities, pharmacological treatment, and invasive interventions are used to accurately diagnose and treat CAD [2]. Invasive coronary angiography (ICA) is the gold standard investigation in the assessment of CAD for both diagnosis and therapeutic purposes [3]. However, with rapid technological development of computed tomography (CT), a non-invasive alternative has been introduced to reduce the risk of invasive interventions, namely coronary computed tomography angiography (CCTA). The potential clinical application of CCTA includes CAD detection, heart function assessment, and anatomical structure of coronary arteries analysis [4-6]. The mean sensitivity and specificity ranges from 76% and 93% in a 4-slice CCTA to 99% and 96% in a 64-slice CCTA [7,8].

A low and consistent heart rate is a key factor to provide a good image quality with high diagnostic accuracy in CCTA. An increment in the patient's heart rate will cause motion artefacts, which leads to poor image quality and affects the accuracy of CAD detection [9]. A 320-slice CT scans the entire heart within a single heartbeat; this eliminates stair-step artefacts due to involuntary cardiac movement and reduces risk of motion artefact due to chest movement during breath-hold. Moreover, with the introduction of dual source CT, the temporal resolution is increased even at elevated heart rate, thereby reducing the problem of motion artefacts [10,11]. However, such techniques increase the level of radiation exposure to the patients. Several approaches have been identified to overcome this problem. For instance, applying tube current modulation mode using high pitch, low tube voltage and implementing adaptive statistical iterative reconstruction (ASIR) will reduce the radiation dose [12]. Moreover, step-

and-shoot scanning mode (prospective ECG-triggering CCTA) in CCTA reduces radiation exposure by 83% as compared to the conventional CCTA technique (retrospective ECG-gating) [13,14]. However, this technique is limited to patients who have a consistent heart rate below 65 beats per minute [13]. Thus, pre-medication such as beta-blockers (most commonly used is metoprololtartarate), calcium antagonists and nitrates are introduced to reduce the heart rate and stabilize heart rhythms.

The beta-blocker is not widely used as most patients with CAD would have been on long-term beta blocker therapy [15]. Beta-blockers are contraindicated in asthmatic patients as it may increase bronchoconstriction [16]. Calcium antagonist can be used as an alternate and is of limited value in patients with a history of heart failure or impaired left ventricular function [17]. Ivabradine is used in the treatment of chronic angina pectoris and chronic heart failure for decades [18]. Ivabradine blocks the funny channel (I_f) in the sinoatrial node [19] resulting in reduced heart rate without adversely affecting blood pressure and cardiac contractility [20,21]. In late 2009, ivabradine was introduced as a pre-medication heart rate controller for CCTA examination and has been adopted by institutions at present. The effectiveness in terms of accuracy is still inconclusive. Therefore, a systematic review was done to provide information on the effectiveness of ivabradine compared to beta-blocker (metoprololtartarate) as a pre-medication in CCTA.

Methods

Literature search

We searched four databases, including PubMed, Medline, Highwire Press, and Science Direct to identify studies using ivabradine as a pre-medication in CCTA examination and published between January 2010

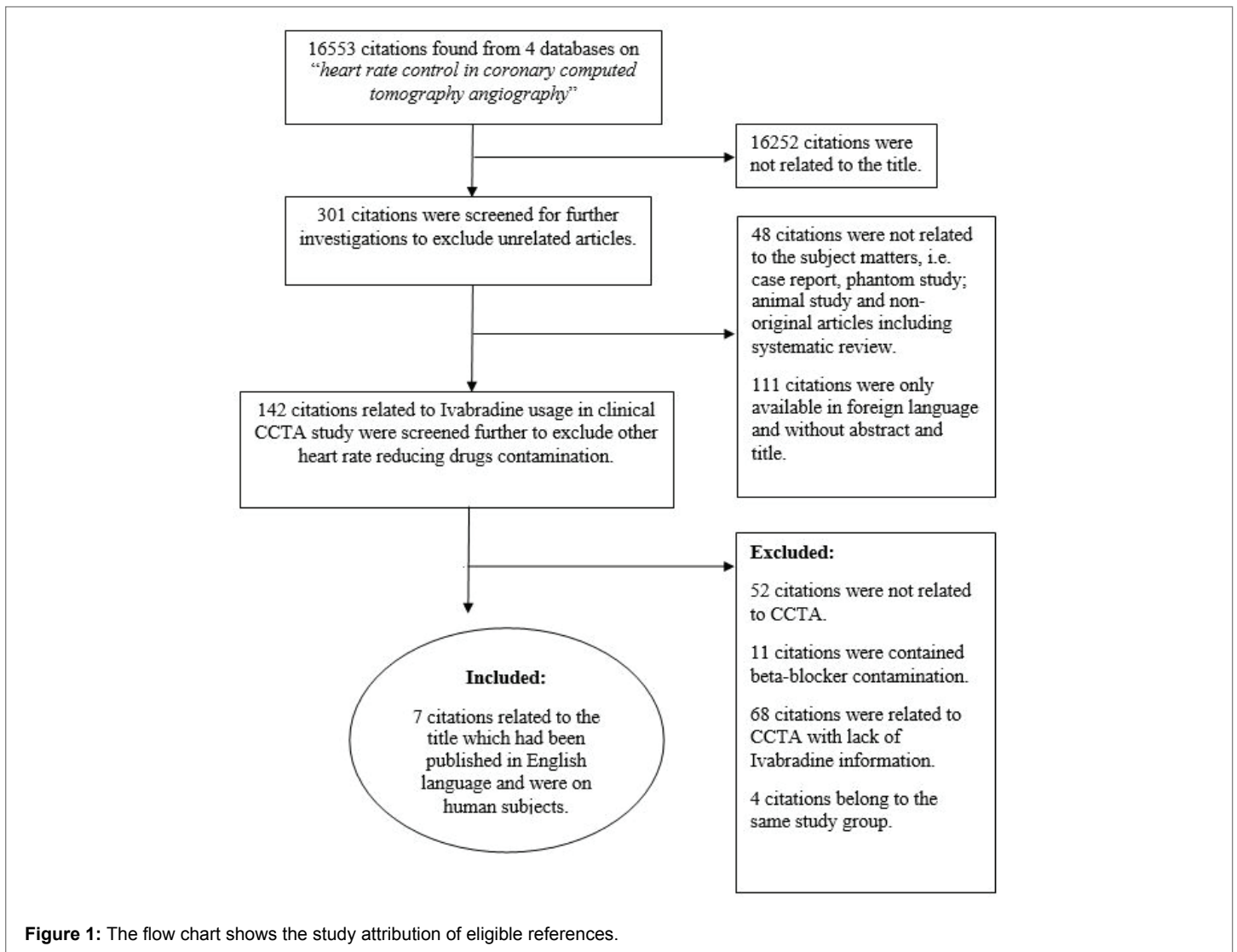


Figure 1: The flow chart shows the study attribution of eligible references.

and February 2014. The terms used for identification of the relevant articles in this study were 'heart rate control in CCTA', 'heart rate control premedication in CCTA' and 'Ivabradine used to control heart rate in CCTA'. The search was conducted on English literature and selected based on the following criteria: (a) CCTA was only performed using ivabradine as premedication; and (b) ivabradine studies provided with complete heart rate information. Studies with other cardiac drug therapy, case reports, phantom studies, animal studies, and other non-original articles were excluded from this review.

Data extraction and analysis

Authors' names, year of publication and patient numbers were noted in each article. Variables such as premedication dosage, admission heart rate, heart rate prior to CCTA, heart rate during CCTA and mean heart rate reduction were recorded in order to analyze the effectiveness of ivabradine as premedication prior to CCTA examination. Technical parameters such as number of detector collimation, gantry rotation time, exposure factors (mA and kVp), pitch, contrast injection method, and scanning mode were also recorded.

All images produced from these studies were of diagnostic quality. Each study was evaluated distinctively either using quantitative or qualitative method. The qualitative image quality evaluation was performed

referring to American Heart Association classification with a minimum of two independent reviewers interpreting the CCTA images using 4- and 5-point grading scales depending on overall image performance ('excellent', 'good', 'moderate' and 'not-interpretable') and presentation of artifacts ('no motion artefacts', 'minor artifacts', 'moderate artifacts', 'severe artifacts and 'unreadable') [22]. However, the image quality of each study was not discussed comprehensively in this review.

Statistical analysis

All data obtained were analyzed using the Statistical Package for the Social Sciences (SPSS) version 20.0. One-way ANOVA was used for comparison of mean total heart rate reduction in between single dose ivabradine, multiple doses ivabradine, beta-blocker, and combination of both ivabradine and beta-blockers as heart rate control agents in CCTA examination.

Results

Seven articles out of 16,553 citations found in four databases met the inclusion criteria and were included in the analysis. The flow chart of study attributions is shown in figure 1. Data on 903 patients from 7 ivabradine studies [23-29], 6 beta-blocker studies [23-26,28,29] and 2 combination of ivabradine and beta-blocker studies [23,24] were tabulated in tables 1-3

Authors/ Year of publication	No. of detector collimation	No. of patients	Age	Tube current (mAs)	Pitch	GRT (ms)	Contrast injection method	Scanning method	Dose of Ivabradine (mg)	Admission HR (b.p.m)	HR prior to CCTA (b.p.m)	HR during CCTA (b.p.m)
Celik et al. [27]	2 × 128 × 0.6	64 64 64	50 ± 8 51 ± 8 51 ± 9	180-300	3.4	280	BT	Retrospective	15 (SD) 10 (SD) 5 (bd for 5 days)	80 ± 8 78 ± 6 79 ± 7	67 ± 8 70 ± 7 68 ± 7	61 ± 5 64 ± 4 62 ± 5
Celik et al. [29]	2 × 128 × 0.6	63	58 ± 6	180-300	3.4	280	BT	Retrospective	15 (SD)	80 ± 7	65 ± 7	62 ± 7
Guaricci et al. [24]	64	30	60 ± 8	300	0.225	400	BT	Retrospective ECG-gating	5 (bd for 5 days)	73 ± 9	64 ± 7	59 ± 4
Guaricci et al. [23]	64	48	58.6 ± 7.8 59.6 ± 10.1	500	0.225	400	BT	Retrospective ECG-gating	5 (bd for 5 days) 7.5 (bd for 5 days)	73.2 ± 9.2 76.3 ± 7.7	62.8 ± 6.9 63.2 ± 7.6	58.0 ± 4.3 58.6 ± 7.8
Pichler et al. [28]	2 × 64 × 0.6	60	55 ± 13	680 340	0.2 0.2-0.39	330	TB	Retrospective ECG-gating	15 (SD)	76 ± 11(N) 74 ± 9(Y)	65 ± 7(N) 61 ± 8(Y)	58 ± 8(N) 56 ± 8(Y)
Bayraktutan et al. [25]	64	56	61 ± 8	500-750	0.18-0.24	400	BT	Retrospective ECG-gating	5 (bd for 3 days)	73 ± 5.8	65 ± 7.8	59 ± 4.1
Adile et al. [26]	64	50	55±9	850	0.2	400	BT	Retrospective ECG-gating	5 (bd for 2 days)	90.02 ± 7.0	68.4 ± 6.7	58.8 ± 1.3

Table 1: Ivabradine used as a heart rate controlling agent in CCTA examination.

GRT: Gantry rotation time; HR: Heart rate; NS: Not stated; BT: Bolus tracking; TB: Test bolus; bd: Twice a day; SD: Single dose; N: Patients who without received long-term beta-blocker therapy; Y: Patients who received long-term beta-blocker therapy.

Authors/ Year of publication	No. of detector collimation	No. of patients	Age	Tube current (mAs)	Pitch	GRT (ms)	Contrast injection method	Scanning method	Dose of beta-blocker (mg)	Admission HR (b.p.m)	HR prior to CCTA (b.p.m)	HR during CCTA (b.p.m)
Celik et al. [29]	2 × 128 × 0.6	62	59 ± 5	180-300	3.4	280	BT	Retrospective ECG-gating	5-10 (SD)	81 ± 7	69 ± 6	66 ± 6
Guaricci et al. [24]	64	31	64 ± 9	300	0.225	400	BT	Retrospective ECG-gating	50 (bd for 5 days)	74 ± 11	70 ± 11	63 ± 7
Guaricci et al. [23]	64	38	63.9 ± 8.8	500	0.225	400	BT	Retrospective ECG-gating	50 (bd for 5 days)	70.5 ± 9.4	67.7 ± 9.1	61.1 ± 6.3
Pichler et al. [28]	2 × 64 × 0.6	60	60 ± 12	680 340	0.2 0.2-0.39	330	TB	Retrospective ECG-gating	50 (SD)	76 ± 8 (N) 71 ± 9 (Y)	60 ± 6 (N) 61 ± 8 (Y)	60 ± 8 (N) 61 ± 9 (Y)
Bayraktutan et al. [25]	64	54	63 ± 11	500-750	0.18-0.24	400	BT	Retrospective ECG-gating	5 (SD)	75 ± 4.8	71 ± 9.8	64 ± 6.7
Adile et al. [26]	64	50	56 ± 10	850	0.2	400	BT	Retrospective ECG-gating	50 (SD)	91.9 ± 5.8	78 ± 6.9	63.2 ± 1.4

Table 2: Beta-blocker used as a heart rate controlling agent in CCTA examination.

GRT: Gantry rotation time; HR: Heart rate; NS: Not stated; BT: Bolus tracking; TB: Test bolus; bd: Twice a day; SD: Single dose; N: Patients who without received long-term beta-blocker therapy; Y: Patients who received long-term beta-blocker therapy.

Authors/ Year of publication	No. of detector collimation	No. of patients	Age	Tube current (mAs)	Pitch	GRT (ms)	Contrast injection method	Scanning method	Dose of beta- blocker + Ivabradine (mg)	Admission HR (b.p.m)	HR prior to CCTA (b.p.m)	HR during CCTA (b.p.m)
Guaricci et al. [24]	64	33	60 ± 10	300	0.225	400	BT	Retrospective ECG-gating	50+5 (bd for 5 days)	75 ± 9	61 ± 8	57 ± 5
Guaricci et al. [23]	64	38 38	59.6 ± 10.9 58.1 ± 9.9	500	0.225	400	BT	Retrospective ECG-gating	5+5 (bd for 5 days) 50+7.5 (bd for 5 days)	74.0 ± 9.5 77.1 ± 10.5	60.1 ± 7.4 57.3 ± 8.1	56.4 ± 5.5 54.0 ± 5.7

Table 3: Combination of ivabradine and beta-blocker used as heart rate controlling agents in CCTA examination.

GRT: Gantry rotation time; HR: Heart rate; NS: Not stated; BT: Bolus tracking; bd: Twice a day; SD: Single dose; N: Patients who without received long-term beta-blocker therapy; Y: Patients who received long-term beta-blocker therapy.

respectively. The information contains heart rates monitored in several stages including on arrival (HR admission), right before CCTA scanning (HR prior to CCTA) and during CCTA examination (HR during CCTA).

Analysis of heart rate reduction in CCTA examination

In ivabradine studies, the dosage used as premedication was administered either as a single dose (10 mg or 15 mg) or multiple doses (5

or 7.5 mg twice daily between 2 and 5 days prior to CCTA). The detailed comparison of total heart rate reduction for ivabradine, beta-blocker and combination of both studies were presented in box plot (Figure 2).

A comparison of HR admission and HR during CCTA among those three premedication techniques were analyzed and shown in bar chart (Figure 3). The highest heart rate reduction recorded among those 3 premedication techniques was the combination of ivabradine and beta-

blocker studies with 19.57 b.p.m (25.2%) followed by ivabradine studies with 17.83 b.p.m (22.4%) and beta-blocker studies with 14.45 b.p.m (14.6%), respectively.

Discussion

This systematic review provides a comparative analysis of the mean HR at the time of admission, HR prior to CCTA, HR during CCTA and total heart rate reduction between ivabradine, beta-blocker, and combination of ivabradine and beta-blocker as premedication in CCTA examination. Our analysis highlights major finding that ivabradine is effective as a heart, reducing agent prior to CCTA examination.

Although several strategies are widely available in clinical setup to reduce heart rate by premedication prior to CCTA examination, beta-blocking medication such as metoprololtartarate is the most prominent and commonly used. Many investigators have recommended the administration of a single dose of oral [30,31] or intravenous [32] beta-blocker to decrease the heart rate for CCTA examination preparation. However, the use of beta-blocker is contraindicated in many diseases. A study conducted by Shapiro et al. [15] stated that approximately 24% of the subjects failed to receive beta-blocker due to contraindications. Replacing beta-blocker with calcium channel blockers (diltiazem and verapamil) too is not an effective strategy since the heart rate reduction effect of these drugs is not sufficient for CCTA examination. Further, they are contraindicated in heart failure and significantly impaired left ventricle function. In atrial fibrillation cases, drugs commonly used are beta-blockers, non-dihydropyridine calcium channel antagonists, and digoxin but their use might be limited by hypotension or other side effects.

Ivabradine, was found to be safe and effective in reducing heart rate in patients with stable angina. Ivabradine selectively inhibits funny channel (I_f) and has minimal cardiovascular effects and is found to be safe in patients who were under long-term calcium channel blockers and effective to overcome limitations of other beta-blockers or calcium channel blockers side effects [29]. Indeed, the safety of ivabradine has been demonstrated

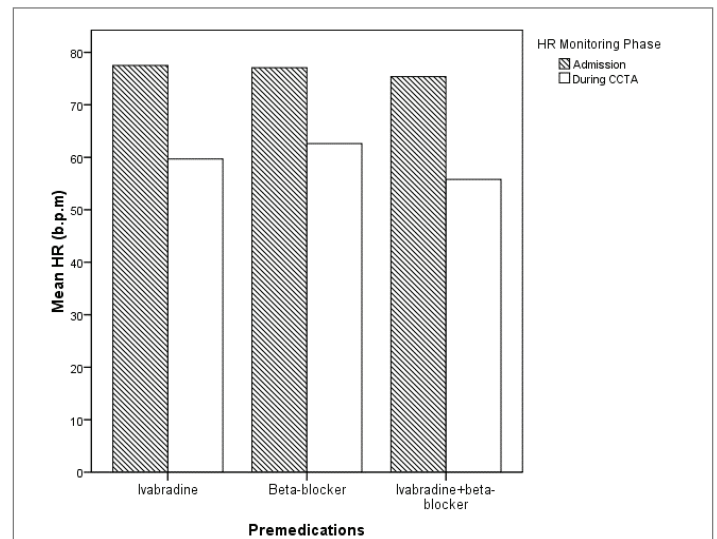


Figure 3: The bar chart shows the comparison between different pre-medications status (Ivabradine study, beta-blocker and combination of Ivabradine and beta-blocker studies) on mean heart rate. The heart rate on admission and during CCTA scanning were monitored and recorded. All 3 premedication conditions showed significant HR reductions in both HR phases.

in large clinical trials with minor side effects such as mild-to-moderate visual symptoms [27,33,34]. Our analysis reveals that premedication with ivabradine provides a better reduction in heart rate as opposed to beta-blocker premedication prior to CCTA examination. Although the side effects of ivabradine are uncommon, blurred vision is the most likely symptom which only occurred if doses are taken excessively more than 15 mg BD and thus, unlikely to be observed with the short time use in CCTA. With the advantages of minimal side effects, lower hemodynamic effects and better tolerance, ivabradine is a better alternative to beta-blocker [35].

In our analysis of ivabradine studies, both single high dose regimen and the multiple low dose regimes were found to be safe and effective in reducing the heart rate prior to CCTA scans. This was supported by Celik et al. [27] who reported that 15 mg of single-dose oral ivabradine given 150 seconds prior to scan was as effective as 5 mg of oral ivabradine given twice daily for 5 consecutive days. The single dose ivabradine regime may be a better option than a 5-day regime because of ease of administration and feasibility. In terms of drug safety, several studies supports that ivabradine as a single dose or as multiple doses are effective and safe to be used in clinical settings regardless of any medical procedures [34,36]. Moreover, in CCTA study, Bax et al. [37] found that a single IV bolus of ivabradine achieved a safe, rapid, and effective heart rate reducing effect in facilitating the performance of a successful CCTA examination.

Only two studies have used ivabradine and beta-blocker combination as a premedication technique prior to CCTA so far and they have shown that the highest heart rate reduction was successfully achieved compared to other studies. Guaricci et al. [24] suggested that a combination of 50 mg of beta-blocker (metoprolol) and 5 mg of ivabradine administered orally, twice a day for five consecutive days prior to CCTA yields the highest heart rate reduction compared to a single dose of beta-blocker or ivabradine alone. Furthermore, in their later study, Guaricci et al. [23] reported that with a slight increment in ivabradine dose by 2.5 mg, further heart rate reduction was achieved as compared to their previous findings (5 mg of ivabradine+50 mg of metoprolol).

The studies with ivabradine premedication resulted in superior CCTA image quality and diagnostic accuracy in the detection of CAD compared

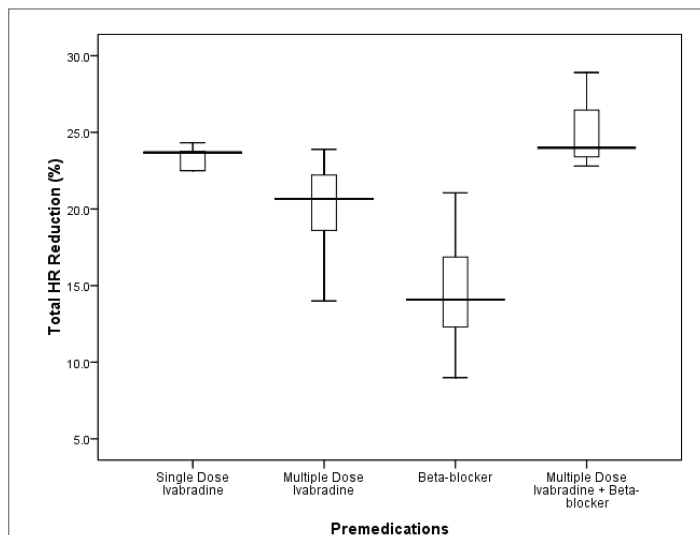


Figure 2: The box plot shows the comparison of total heart rate reduction CCTA in between single dose Ivabradine, multiple doses Ivabradine, beta-blocker and combination of multiple doses Ivabradine and beta-blocker studies. The boxes indicate the first to third quartiles; each midline indicates the median (second quartile) and the whiskers represent the maximum and minimum percentage of respective premedication used. The tremendous heart rate reduction was achieved during CCTA procedure when multiple doses of Ivabradine and beta-blocker were applied.

to beta-blocker premedication studies. Bayraktutan et al. [25] reported that 95.5% of coronary segments were diagnostically accepted with ivabradine studies compared to 89.9% in beta-blocker studies. Moreover, Celik et al. [27] reported that only 4.5% of the images were of unacceptable quality in ivabradine studies compared to 10.2% in beta-blocker studies. The most common cause of CCTA image degradation is a stair-step artifact due to involuntary cardiac motion. This phenomenon, however, can be avoided by lowering the heart rate and maintaining the cardiac pace [25]. With a slow heart rhythm, each image can be registered completely during scan acquisition resulting in improved image quality [38]. Several literatures agreed that most CCTA protocols recommend that the most optimal visibility of vessels with high diagnostic value can be achieved at heart rate not more than 65 b.p.m. [13,39,40].

CCTA examination has high radiation exposure compared to other diagnostic radiological investigations. Several approaches had been introduced to reduce the radiation dose to patient without affecting image quality [41]. Prospective ECG-triggered CCTA is one of them that reduces radiation dose by 83% compared to retrospective ECG-gated technique [13]. However, a low and stable heart rate is essential to perform this low radiation dose protocol effectively. Therefore, heart rate reduction remains as an important factor not only to optimize CCTA image quality, but also to limit radiation exposure. To date, no studies have specifically addressed the effectiveness of ivabradine as a heart rate reducing agent in prospective ECG-gated CCTA examination which may have high possibility to minimize radiation dose.

Only a small number of studies met our inclusion criteria for analysis. Most literature was excluded from this review due to lack of information provided such as patient's heart rate monitoring especially in ivabradine studies. In fact, almost all of ivabradine studies were described in the management of stable angina pectoris. Second, only few studies provide the details of image quality analysis. The total heart rate reduction provided in the literature was not in the same SI unit. Therefore, a conversion process to obtain similar unit (SI) is adopted in our data analysis.

Conclusions

The systematic review reveals that Ivabradine is an effective heart rate reducing agent in CCTA examination. Ivabradine is safe, and effective in reducing heart rate to generate image of diagnostically acceptable quality in almost all coronary segments in comparison to beta-blocker. In addition, further heart rate reduction can be achieved prior to CCTA examination with combination of ivabradine and beta-blocker regardless of prospective ECG-triggering or retrospective ECG-gating protocols.

Acknowledgement

We would like to thank Young Researcher Incentive Grant Scheme (GGPM-2013-099), Universiti Kebangsaan Malaysia, for financial support of the study review.

References

- Sabarudin A, Sun Z, Ng KH (2012) A systematic review of radiation dose associated with different generations of multidetector CT coronary angiography. *J Med Imaging Radiat Oncol* 56: 5-17.
- Cassar A, Holmes DR, Rihal CS, Gersh BJ (2009) Chronic coronary artery disease: diagnosis and management. *Mayo Clin Proc* 84: 1130-1146.
- Smith SCJ, Dove JT, Jacobs AK, Kennedy JW, Kereiakes D, et al. (2001) ACC/AHA guidelines for percutaneous coronary intervention (revision of the 1993 PTCA guidelines)-executive summary: a report of the American College of Cardiology/American Heart Association task force on practice guidelines (Committee to revise the 1993 guidelines for percutaneous transluminal coronary angioplasty. The Society for Cardiac Angiography and Interventions. *Circulation* 103: 3019-3041.
- Ollendorf DA, Kuba M, Pearson SD (2011) The diagnostic performance of multi-slice coronary computed tomographic angiography: a systematic review. *J Gen Intern Med* 26: 307-316.
- Miller JM, Rochitte CE, Dewey M, Arbab-Zadeh A, Niinuma H, et al (2008) Diagnostic performance of coronary angiography by 64-row CT. *N Engl J Med* 359: 2324-2336.
- Heilbron B, Andrews G, Isserow S, Forster BB (2007) Coronary computed tomographic angiography in British Columbia: A review. *BCM J* 49: 78-84.
- Sabarudin A, Md Yusof AK, Tay MF, Ng KH, Sun Z (2013) Dual-source CT coronary angiography: effectiveness of radiation dose reduction with lower tube voltage. *Radiat Prot Dosimetry* 153: 441-447.
- Sun Z, Choo GH, Ng KH (2012) Coronary CT angiography: current status and continuing challenges. *Br J Radiol* 85: 495-510.
- Giesler T, Baum U, Ropers D, Ulzheimer S, Wenkel E, et al. (2002) Noninvasive visualization of coronary arteries using contrast-enhanced multidetector CT: influence of heart rate on image quality and stenosis detection. *Am J Roentgenol* 179: 911-916.
- de Graaf FR, Schuijff JD, van Velzen JE, Boogers MJ, Kroft LJ, et al. (2010) Diagnostic accuracy of 320-row multidetector computed tomography coronary angiography to noninvasively assess in-stent restenosis. *Invest Radiol* 45: 331-340.
- Rixe J, Conradi G, Rolf A, Schmermund A, Magedanz A, et al. (2009) Radiation dose exposure of computed tomography coronary angiography: comparison of dual-source, 16-slice and 64-slice CT. *Heart* 95: 1337-1342.
- Sabarudin A, Sun Z (2013) Coronary CT angiography: Dose reduction strategies. *World J Cardiol* 5: 465-472.
- Sabarudin A, Sun Z, Yusof AK (2013) Coronary CT angiography with single-source and dual-source CT: comparison of image quality and radiation dose between prospective ECG-triggered and retrospective ECG-gated protocols. *Int J Cardiol* 168: 746-753.
- Earls JP, Berman EL, Urban BA, Curry CA, Lane JL, et al. (2008) Prospectively gated transverse coronary CT angiography versus retrospectively gated helical technique: improved image quality and reduced radiation dose. *Radiology* 246: 742-753.
- Shapiro MD, Pena AJ, Nichols JH, Worrell S, Bamberg F, et al. (2008) Efficacy of pre-scan beta-blockade and impact of heart rate on image quality in patients undergoing coronary multidetector computed tomography angiography. *Eur J Radiol* 66: 37-41.
- Tattersfield AE (1991) Respiratory function in the elderly and the effects of beta blockade. *Cardiovasc Drug Ther* 4: 1229-1232.
- Nicol ED, Arcuri N, Rubens MB, Padley SPG (2008) Considerations when introducing a new cardiac MDCT service. Avoiding the pitfalls. *Clin Radiol* 63: 355-369.
- Deedwania P (2013) Selective and specific inhibition of If with ivabradine for the treatment of coronary artery disease or heart failure. *Drugs* 73: 1569-1586.
- Dilaveris P, Giannopoulos G, Synetos A, Gatzoulis K, Stefanadis C (2006) Heart rate lowering by inhibition of the pacemaker current: a new therapeutic perspective in cardiovascular disease. *Cardiovasc Hematol Agents Med Chem* 4: 313-318.
- Manz M, Reuter M, Lauck G, Omran H, Jung W (2003) A single intravenous dose of ivabradine, a novel I(f) inhibitor, lowers heart rate but does not depress left ventricular function in patients with left ventricular dysfunction. *Cardiology* 100: 149-155.
- Joannides R, Moore N, Iacob M, Compagnon P, Lerebours G, et al. (2006) Comparative effects of ivabradine, a selective heart rate lowering agent, and propranolol on systemic and cardiac haemodynamics at rest and during exercise. *Br J Clin Pharmacol* 61: 127-137.

22. Scanlon PJ, Faxon DP, Audet AM, Carabello B, Dehmer GJ, et al. (1999) ACC/AHA guidelines for coronary angiography. A report of the American College of Cardiology/ American Heart Association Task Force on practice guidelines (Committee on Coronary Angiography). Developed in collaboration with the Society for Cardiac Angiography and Interventions. *J Am Coll Cardiol* 33: 1756-1824.
23. Guaricci AI, Maffei E, Brunette ND, Montrone D, Biase LD, et al. (2013) Heart rate control with oral ivabradine in computed tomography coronary angiography: a randomized comparison of 7.5 mg vs 5 mg regimen. *Int J Cardiol* 168: 362-368.
24. Guaricci AI, Schuijf JD, Cademartiri F, Brunetti ND, Montrone D, et al. (2012) Incremental value and safety of oral ivabradine for heart rate reduction in computed tomography coronary angiography. *Int J Cardiol* 156: 28-33.
25. Bayraktutan U, Kantarci M, Gundogdu F, Demirelli S, Yuce I, et al. (2012) Efficacy of ivabradin to reduce heart rate prior to coronary CT angiography: comparison with beta-blocker. *Diagn Interv Radiol* 18: 537-541.
26. Adile KK, Kapoor A, Jain SK, Gupta A, Kumar S, et al. (2012) Safety and efficacy of oral ivabradine as a heart rate-reducing agent in patients undergoing CT coronary angiography. *Br J Radiol* 85: e424-e428.
27. Çelik Ö, Atasoy MM, Ertürk M, Yalçın AA, Aksu HU, et al. (2014) Comparison of different strategies of ivabradine premedication for heart rate reduction before computed tomography coronary angiography. *J Cardiovasc Comput Tomogr* 8: 77-82.
28. Pichler P, Pichler-Cetin E, Vertesich M, Mendel H, Sochor H, et al. (2012) Ivabradine versus metoprolol for heart rate reduction before coronary computed tomography angiography. *Am J Cardiol* 109: 169-173.
29. Çelik Ö, Atasoy MM, Ertük M, Aksu HÜ, Yalçın AtA, et al. (2014) Single dose ivabradine versus intravenous metoprolol for heart rate reduction before coronary computed tomography angiography (CCTA) in patients receiving long-term calcium channel-blocker therapy. *Acta Radiol* 55: 676-681.
30. Shim SS, Kim Y, Lim SM (2005) Improvement of image quality with beta-blocker premedication on ECG-gated 16-MDCT coronary angiography. *Am J Roentgenol* 184: 649-654.
31. Pannu HK, Sullivan C, Lai S, Fishman EK (2008) Evaluation of the effectiveness of oral Beta-blockade in patients for coronary computed tomographic angiography. *J Comput Assist Tomogr* 32: 247-251.
32. Degertekin M, Gemici G, Kaya Z, Bayrak F, Guneyusu T, et al. (2008) Safety and efficacy of patient preparation with intravenous esmolol before 64-slice computed tomography coronary angiography. *Coron Artery Dis* 19: 33-36.
33. Borer JS, Fox K, Group JPI (2003) Antianginal and antiischemic effects of ivabradine, an I(f) inhibitor, in stable angina: a randomized, double-blind, multicentered, placebo-controlled trial. *Circulation* 107: 817-823.
34. Di Francesco D, Camm JA (2004) Heart rate lowering by specific and selective I(f) current inhibition with ivabradine: a new therapeutic perspective in cardiovascular disease. *Drugs* 64:1757-1765.
35. Patel N, Sakhi P, Jain S, Jain S, Patel K, et al. (2014) Ivabradine: a novel drugs to control heart rate of patients undergoing CT coronary angiography. *Sch J Med Sci* 2:171-175.
36. Bois P, Bescond J, Renaudon B, Lenfant J (1996) Mode of action of bradycardic agent, S 16257, on ionic currents of rabbit sinoatrial node cells. *Br J Pharmacol* 118: 1051-1057.
37. Bax J, Achenbach S, Cademartiri F, Garot J, Tendra M, et al. (2010) A randomized double blind trial on the efficacy and safety of a single intravenous bolus of ivabradine versus placebo for heart rate control during coronary CT angiography. *Eur Heart J* 31: 151.
38. Sabarudin A, Sun Z (2013) Coronary CT angiography: Diagnostic value and clinical challenges. *World J Cardiol* 5: 473-483.
39. Cademartiri F, Mollet NR, Runza G, Belgrano M, Malagutti P, et al. (2006) Diagnostic accuracy of multislice computed tomography coronary angiography is improved at low heart rates. *Int J Cardiovasc Imaging* 22:101-105.
40. Nieman K, Cademartiri F, Lemos PA, Raaijmakers R, Pattynama PMT, et al. (2002) Reliable noninvasive coronary angiography with fast submillimeter multislice spiral computed tomography. *Circulation* 106: 2051-2054.
41. Pontone G, Andreini D, Bartorelli AL, Cortinovis S, Mushtaq S, et al. (2009) Diagnostic accuracy of coronary computed tomography angiography: a comparison between prospective and retrospective electrocardiogram triggering. *J Am Coll Cardiol* 54: 346-355.