

# A Novel Case of Immunocompetent Cytomegalovirus enteritis after Cardiac Surgery

Simon Mbarushimana<sup>1\*</sup>, Asif Farooqui<sup>2</sup>, Aaron Ervine<sup>3</sup> and Haralabos Parissis<sup>2</sup>

<sup>1</sup>Department of General Surgery, James Cook University Teaching Hospital, Middlesbrough, England, United Kingdom

<sup>2</sup>Department of Cardiothoracic Surgery, Royal Victoria Hospital, Belfast, Northern Ireland, United Kingdom

<sup>3</sup>Department of Histopathology, Royal Victoria Hospital, Belfast, Northern Ireland, United Kingdom

\*Corresponding author: Simon Mbarushimana, Department of General Surgery, James Cook University Teaching Hospital, Marton Road, Middlesbrough, TS4 3BW, United Kingdom, Tel: +44 01642 850850; E-mail: [simon.mbarushimana2@nhs.net](mailto:simon.mbarushimana2@nhs.net)

Received date: 04 May 2016; Accepted date: 25 May 2016; Published date: 30 May 2016.

Citation: Mbarushimana S, Farooqui A, Ervine A, Parissis H (2016) A Novel Case of Immunocompetent *Cytomegalovirus enteritis* after Cardiac Surgery. J Hear Health 2(3): doi <http://dx.doi.org/10.16966/2379-769X.127>

Copyright: © 2016 Simon Mbarushimana, et al. This is an open-access article distributed under the terms of the Creative Commons Attribution License, which permits unrestricted use, distribution, and reproduction in any medium, provided the original author and source are credited.

## Abstract

**Background:** *Cytomegalovirus enteritis* (CMV) post coronary-bypass grafting has never been reported in an immunocompetent patient not on steroids. Moreover, there are no cases in the literature where in CMV enteritis led to small bowel ischemia.

**Case:** An immunocompetent patient presented with NSTEMI, triple-vessel disease and severe left ventricular dysfunction. He underwent urgent CABG. He developed multiple complications including gastrointestinal bleeding, acute abdomen and dialysis-resistant lactate acidosis. He underwent laparotomy and resection of perforated small bowel.

**Results:** Histology revealed CMV enteritis.

**Conclusions:** CMV enteritis must be considered and actively sought in immunocompetent patients who develop GI complications post CABG.

**Keywords:** CMV enteritis; CMV enteritis post CABG; CMV enteritis in immunocompetent patient

## Introduction

Despite improvements in surgical technique and perfusion technology, the incidence and mortality from gastrointestinal (GI) complications following cardiac surgery are reported to be up to 3.1% and 39% respectively [1,2]. One of the GI complications is Cytomegalovirus (CMV) induced bowel ischaemia. Symptoms and signs include abdominal pain, watery or bloody diarrhoea, per rectum bleeding, obstruction, perforation and fistula formation [3]. The severity and outcome of CMV enteritis depend on the host's immune status. Risk factors include acquired immune deficiency syndrome (AIDS), organ recipients, immunosuppression, haematological malignancies or chemotherapy [3-5]. While a case of CMV colitis has been reported in a post coronary artery bypass grafting (CABG) patient previously [5], this is the first histologically proven case of CMV small bowel ischemia in a patient who was neither immunosuppressed nor on steroid therapy preoperatively.

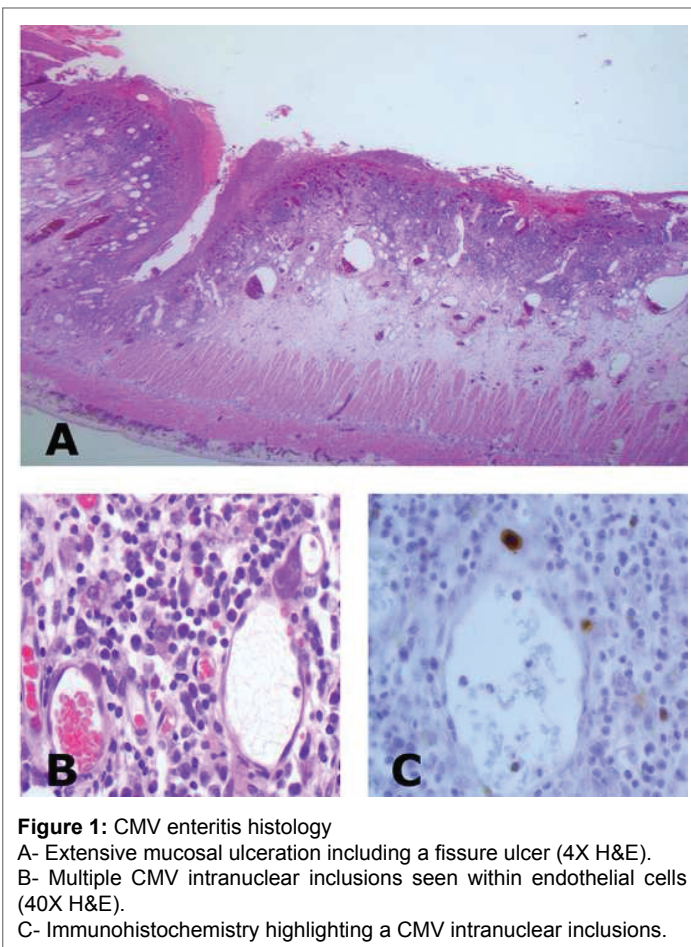
## Case Report

In 2013, a 65 year old male presented with crescendo angina and a delayed diagnosis of non-ST-elevation myocardial infarction (NSTEMI) was made. Coronary angiogram showed triple vessel disease and ejection fraction of 20%. Magnetic resonance imaging demonstrated some myocardial reversibility. His past medical history included myocardial infarction, hypertension, atrial fibrillation, and bowel polyps. One month after admission, he underwent three-vessel CABG and MAZE procedure. His three-vessel CABG was done without aortic crossclamp and cardioplegic arrest to minimize the risk of ischaemia: the left internal mammary artery was grafted to the left anterior descending artery, the obtuse marginal and posterior descending artery then had venous grafts fashioned. An intra-aortic balloon pump was inserted preoperatively.

His post-operative period was complicated: initially his chest was left open because of the difficulty to be weaned off cardiopulmonary bypass (CPB). As the heart appeared swollen with poor function, the patient was placed on renal replacement therapy and once the oedema subsided the chest was closed five days later. He underwent re-sternotomy with evacuation of hematoma on day 16. A combination of low cardiac output states, lower and upper GI bleeding requiring transfusions and multiple infections meant on day 21 he was still intubated, ventilated and requiring large amount of inotropes.

An oesophago-gastroduodenoscopy on day 21 and 29 showed erosive gastritis. Discrete superficial prepyloric erosions were treated with adrenaline and haemorrhagic gastritis managed with argon plasma coagulation. Acute abdominal signs and symptoms, progressive from day 21 to 34 ultimately culminated in abdominal distension, absent bowel sounds and dialysis resistant lactate acidosis. Despite abdominal CT showing dilated small bowel loops without a transition point or features of ischemia, on day 34 he underwent laparotomy, resection of an 82 cm length of necrotic, ulcerated and perforated small bowel and ileostomy.

Subsequent to histopathology confirming CMV enteritis (Figure 1), serologic tests were performed for CMV, Hepatitis (Hep) C and B and Human immunodeficiency virus (HIV). Quantitative CMV Polymerase Chain Reaction showed a result of 109000 IU/ml and 6 weeks later CMV immunoglobulin IgM was negative but CMV IgG positive (>250 AU/ml). Hep C PCR detected no viral load while HIV1 and HIV2 antibodies, p24 antigen, Hep C virus antibody, Hep B surface antigen and Hep B surface antibody were all negative. He remained in ICU for 75 days and spent 56 days on a normal ward before discharge.



**Figure 1:** CMV enteritis histology  
 A- Extensive mucosal ulceration including a fissure ulcer (4X H&E).  
 B- Multiple CMV intranuclear inclusions seen within endothelial cells (40X H&E).  
 C- Immunohistochemistry highlighting a CMV intranuclear inclusions.

## Conclusion and Discussion

A MEDLINE literature search of relevant papers failed to identify any other histologically proven case of post CABG CMV enteritis in a patient who was immunocompetent and not on steroids preoperatively. In one case, CMV colitis was attributed to concomitant use of long term steroids for polymyalgia [5]. Another case, diagnosed on colonoscopy one month after elective mitral and aortic valve replacement and CABG, does not provide any information on the patient's immune status or his/her complications during intensive care unit (ICU) stay [2]. CMV disease is often due to the reactivation of latent disease in immunosuppressed and in up to 36% critically ill immunocompetent patients [6]. This reactivation

is thought to be due the dysfunction of cellular immune system which causes shifting of T Helper 1 to T Helper 2 response or immune paralysis [7]. In our case, CMV reactivation is thus likely to be due to the stormy postoperative recovery.

Reports suggest improved survival rates can be achieved with early diagnosis, aggressive antiviral therapy [5] and, if indicated, early surgical intervention [8]. However, since patients likely to have GI complications of CMV are sedated and ventilated post cardiac surgery, clinical assessment and early diagnosis are a challenge. Indeed, in our case CMV enteritis was diagnosed on histology after laparotomy and small bowel resection. Consequently, we suggest firstly to consider CMV enteritis in immunocompetent patients who have complicated ICU stay and signs and symptoms such as abdominal pain, watery or bloody diarrhoea, bleeding or obstruction; and secondly to have a high index of suspicion for CMV enteritis in patients who are on steroids preoperatively.

## Presentation

Presented at WSCTS, Edinburgh, 19-22 September 2015.

## References

1. Dong G, Liu C, Xu B, Jing H, Li D, et al. (2012) Postoperative abdominal complications after cardiopulmonary bypass. *J Cardiothorac Surg* 7: 108.
2. Gulkarov I, Trocciola SM, Yokoyama CC, Girardi LN, Krieger KK, et al. (2014) Gastrointestinal complications after mitral valve surgery. *Ann Thorac Cardiovasc Surg* 20: 292-298.
3. Buckner FS, Pomeroy C (1993) Cytomegalovirus disease of the gastrointestinal tract in patients without AIDS. *Clin Infect Dis* 17: 644-656.
4. Vancíková Z, Dvorač P (2001) Cytomegalovirus infection in immunocompetent and immunocompromised individuals--a review. *Curr Drug Targets Immune Endocr Metabol Disord* 1: 179-187.
5. Camprodon RA, Jacob S, Malkawi A, Al-Ghnam R (2007) CMV colitis presenting as acute abdomen requires early diagnosis and treatment to avoid mortality. *Acta Chir Belg* 107: 378-381.
6. Sandkovsky U, Florescu DF, Um JY, Raichlin E, Lowes BD, et al. (2013) Cytomegalovirus reactivation and colitis after left ventricular assist device placement. *Int J Infect Dis* 17: e348-e351.
7. Kalil AC, Florescu DF (2009) Prevalence and mortality associated with cytomegalovirus infection in nonimmunosuppressed patients in the intensive care unit. *Crit Care Med* 37: 2350-2358.
8. Davidson T, Allen-Mersh TG, Miles AJ, Gazzard B, Wastell C, et al. (1991) Emergency laparotomy in patients with AIDS. *Br J Surg* 78: 924-926.