

Use of External Jugular Vein Puncture Technique in Ambulatory Settings for HCV or HIV/HCV Co-infected People Who Inject Drugs

Erika Castro*¹ and Claire Elise Burdet^{1,2}

¹Center for Addiction Medicine, Service of Community Psychiatry, Department of Psychiatry, Lausanne University Hospital (CHUV), Lausanne, Switzerland

²Family Medicine, CLSC de Côte-des-Neiges, McGill University, Montréal, Québec, Canada

*Corresponding author: Erika Castro, Center for Addiction Medicine, Service of Community Psychiatry, Department of Psychiatry, Lausanne University Hospital (CHUV), Lausanne, Switzerland, Tel: +41 21 314 84 00; Fax: +41 21 314 87 35; E-mail: erika.castro-bataenjer@chuv.ch

Received date: 20 Mar 2017; Accepted date: 17 May 2017; Published date: 23 May 2017.

Citation: Castro E, Burdet CE (2017) Use of External Jugular Vein Puncture Technique in Ambulatory Settings for HCV or HIV/HCV Co-infected People Who Inject Drugs. J HIV AIDS 3(2): doi <http://dx.doi.org/10.16966/2380-5536.141>

Copyright: © 2017 Castro E, et al. This is an open-access article distributed under the terms of the Creative Commons Attribution License, which permits unrestricted use, distribution, and reproduction in any medium, provided the original author and source are credited.

Abstract

Chronic hepatitis C virus infection is a global epidemic mainly affecting Eastern Mediterranean and European Regions with 2.3% and 1.5% prevalence, respectively. In addition, nearly 80% of people with HIV who inject drugs also have HCV infection. Current HCV direct acting antiviral agents (DAA) are well tolerated and available in most western countries. However, routine limb vein puncture remains a medical barrier for treatment of HIV/HCV coinfection of long-term people who inject drugs (PWIDs). In fact, difficult venous access due to poor vascular health consecutive to years of intravenous drug injection is a common constraint. External jugular vein puncture is a simple and safe procedure, which can easily be performed in an ambulatory setting in patients with very poor peripheral venous capital. This technique proves useful for blood screening and medical follow-up of polymorbid PWIDs (HIV/HCV co infection, non-infectious hepatic disorders, cardiovascular diseases, metabolic disorders, etc.) However no published protocol is currently available.

This article reviews the indications of external jugular vein puncture, its' possible complications and the advantages it can offer long-term PWIDs followed elsewhere in view of overcoming medical obstacles for monitoring HIV therapy, DAAs and other concomitant treatments. It also provides a hands-on procedure of the technique based on the expertise of the Lausanne's addiction medicine clinic.

Keywords: Hepatitis C Virus; Co infection; External Jugular Vein; Direct-Acting Antiviral Treatment; Vein puncture

Setting the Problem

Globally, there are 37 million people infected with HIV and 115 million people with hepatitis C virus (HCV). Furthermore, 71 million people have chronic hepatitis C infection. According to WHO regions, Eastern Mediterranean and European countries have the highest prevalence rates of chronic hepatitis C with 2.3% and 1.5% respectively [1,2].

In addition, nearly 80% of people with HIV who inject drugs also have HCV co infection [1,3]. Screening and further treatment of HIV and HCV infections presupposes frequent and large blood collections for evaluation of HIV antiviral treatment (ART) and direct-acting antiviral treatment (DAA) efficacy, as well as monitoring for systemic side-effects of DAA therapy including drug-drug interactions with ART and other co-medications [4].

A good number of licensed rapid tests are currently available for antibody screening of HIV and HCV using capillary blood and saliva, respectively [5]. However, for diagnosis confirmation and viral load measuring we do not dispose of standardized algorithms based on capillary blood draw [6]. Peripheral venous access and limb phlebotomy can be challenging in long-term PWIDs due to poor vascular health as a result of years of intravenous drug injection and related medical complications [7,8]. Furthermore, femoral drug injection is a common practice among PWIDs [9-11].

In this context optional central blood draw from external jugular vein (EJV) was previously assessed in PWIDs with difficult venous access proving to be safe with no recorded adverse events and high level of satisfaction among all patients [12]. EJV puncture is a simple

procedure, which can easily be performed in an ambulatory setting so as to circumvent the difficulty of obtaining large blood specimens in patients with very poor peripheral venous capital and allow medical follow-up polymorbid PWIDs (HIV and HCV infections, non-infectious hepatic disorders, metabolic disorders, COPD, cardiovascular disease, etc.). It is used on routine basis by clinicians in Lausanne's center for addiction medicine in accordance to a local guideline [13].

However no published protocol is currently available. Therefore this article reviews the indications of external jugular vein puncture, its' possible complications and the advantages it can offer long-term PWIDs followed elsewhere in view of overcoming medical obstacles for monitoring HIV therapy, DAAs and other concomitant treatments. It also provides a hands-on procedure of the technique based on the expertise of the Lausanne's addiction medicine clinic.

Suitability of the Technique: Indications and Contraindications to EJV Puncture

Prior to performing an EJV blood collection, it is crucial to thoroughly assess the patient's peripheral venous capital, and identify any sites suitable for limb vein puncture. Difficult venous access can be established using both patient history (multiple failed attempts at peripheral vein puncture), and clinical examination.

Equally crucial is to assess and address the risk of reviving drug craving in PWID who have previously injected their external jugulars should this site be chosen to draw blood samples. Check for coagulopathy and platelet level in the patient's record, and if abnormal, exercise precaution so as to minimize the risk of prolonged bleeding.

If no alternate suitability for blood collection from conventional peripheral sites is identified, proceed to bilateral EJV assessment for suitability for vein puncture. If the EJV is not clearly identifiable visually, or if there is the presence of local bruising or trauma to the neck, EJV vein puncture should not be attempted. Prior EJV injectors with important local venous scar tissue should also not undergo this procedure. Profound alterations in clotting or coagulation, or an agitated poorly cooperative patient (possibly under influence of psychoactive substances) are also general (yet relative) contra-indications to performing EJV blood collection.

Advantages of the Technique

- Drawing blood samples from central veins as EJV presents no additional pain to the patient [12].
- The EJV is a *superficial* vein, with little risk of provoking lesions to profound structures when collecting blood from it - unlike attempts to access the internal jugular which can be complicated by a pneumothorax for example.
- The neck is a fairly “clean” site for blood sampling, unlike the groin, and may thus limit the risk of infectious complications related to blood sampling [14].
- There is no adjacent artery to the EJV such as there is in the groin, which reduces the risk of arterial puncture and the associated complication of a compressive hematoma [14]. This consideration is especially relevant in patients who may have concurrent coagulopathy or thrombocytopenia as a result of HCV-related liver disease, HCV-treatment, alcohol misuse, etc.
- In the case of patients who have particularly difficult peripheral venous access, EJV vein puncture presents an important risk-reduction strategy for blood collectors due to the reduction in the number of vein puncture attempts necessary to collect blood.
- The EJV is a superficial vein which presents a relatively large caliber in comparison with peripheral limb veins, and thus the decent EJV blood-flow results in blood samples sufficient in volume for adequate analysis.

The Procedure

Topographic anatomy

The external jugular vein is a superficial vein situated on the lateral portion of the neck. It is easily identified visually, and runs obliquely from the angle of the mandible down to the middle of the clavicle. Its diameter is roughly 5-10mm, but varies widely from one side to the other, between individuals, and seems inversely correlated to the diameter of the internal jugular vein on the ipsilateral side [15] as shown in Figure 1.

Preparation and positioning of the patient

- Clearly explain the procedure to the patient to obtain his informed consent, and reduce any anxiety.
- Inform the patient about risks incurred through EJV drug injection, thus limiting the temptation for ulterior use of this venous route of access.
- Make sure the patient is fully supine, with the head lying flat. Examine both left and the right neck sides to visually explore both EJVs. A slight Trendelenburg position if the examination table so allows, or asking the patient to perform a Valsalva maneuver can help to better identify the EJV by visualization and palpation (Figure 2a).

EJV Blood collection step-by-step

- Use an adequately equipped area to perform the procedure, so as to ensure patient security and reduce infectious risks.
- Wash and/or disinfect hands, and wear gloves.
- Ask the patient to lay down supine on his back, and to rotate his head to the side. The patient's head must lie in a relatively neutral position, neither extended nor flexed, as this could mask the EJV. Make sure the patient is in a comfortable position.
- Ask the patient to perform a Valsalva manoeuvre so as to distend the EJV (Figure 2a).
- If the EJV proves difficult to visually identify, slightly lower the head by elevating the neck by propping the shoulders up with a pillow (Figure 2b).
- Clean the skin superficial to the EJV with cutaneous disinfectant. Allow the skin to dry.
- Place a finger on the EJV on its' distal portion towards the clavicle.
- Gently introduce the butterfly needle (22 G or 21 G) in the EJV following its direction.
- Once the butterfly is introduced in the EJV lumen, reassure the patient by inviting him/her to breathe normally if the Valsalva maneuver is still being performed.
- Attach the vacutainer adaptor to the butterfly needle, and collect blood samples as needed.
- Withdraw the butterfly needle and apply some pressure to the site of vein puncture during 3-5 minutes to minimize the risk of ulterior bleeding.
- Avoid multiple vein puncture attempts to the EJV to preserve the vein from damage, and avoid excessive discomfort to the patient.

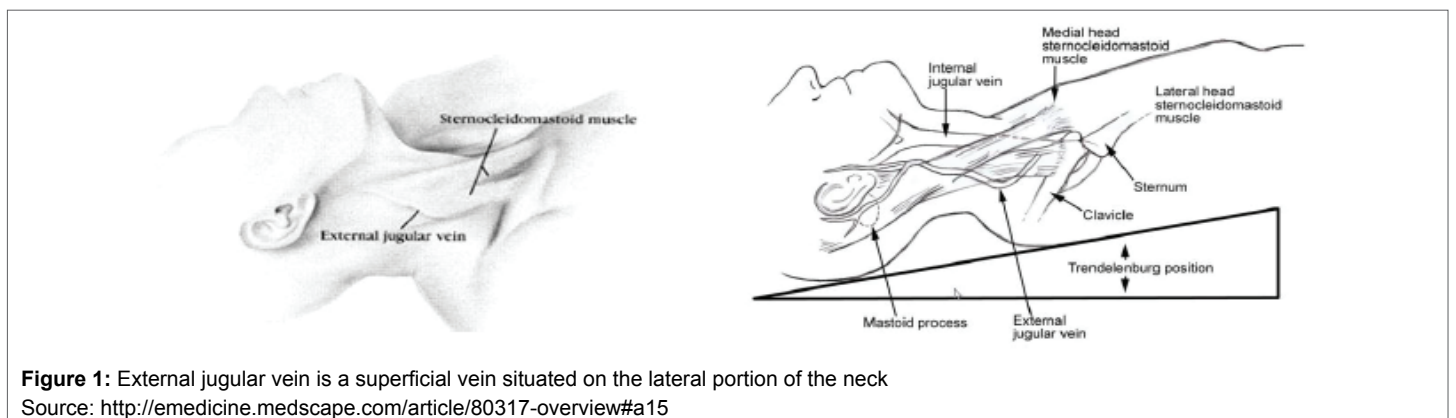


Figure 1: External jugular vein is a superficial vein situated on the lateral portion of the neck
Source: <http://emedicine.medscape.com/article/80317-overview#a15>

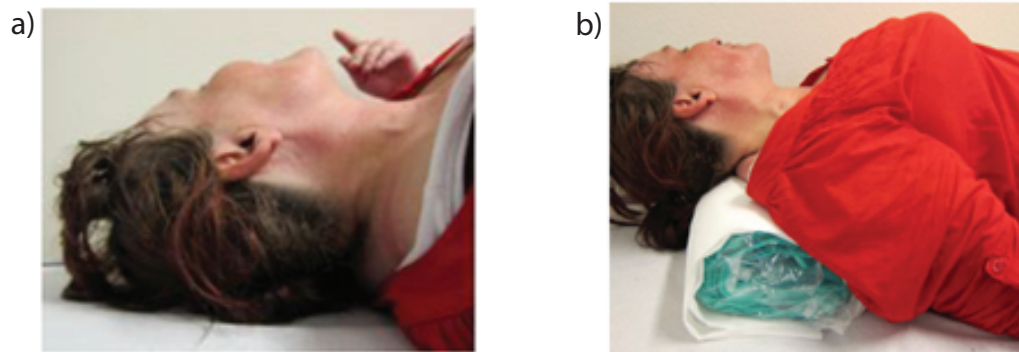


Figure 2: a) Lateral Supine Head Position
b) Optional Positioning of Patient to Better Visualize EJV

Post-procedural precautions and recommendations

- Help the patient to resume a seated position, and inform the patient of the possibility of feeling slightly dizzy. As for any other vein puncture, a vaso-vagal reaction is possible.

Summary

EJV blood sampling is an easily and safely performed bedside technique which can prove useful in the clinical management of patients with poor peripheral venous capital, thus affording them the blood work required to treat them optimally.

Acknowledgements

We are grateful to Dr Martine Monnat (Former head of the center for addiction medicine) and the health care workers from the center for their input in integrating EJV blood draw as a standard of care for PWID.

Informed consent was obtained from the patient who kindly accepted to be photographed during a routine procedure of EJV puncture required for her medical follow-up.

We thank Dr. Philip Bruggmann (Internal medicine chief at Arud Centers for Addiction Medicine, Zurich, Switzerland) for his critical reading of this paper.

References

1. Platt L, Easterbrook P, Gower E, McDonald B, Sabin K, et al. (2016) Prevalence and Burden of HCV Co-Infection in People Living with HIV: A Global Systematic Review and Meta-Analysis. *Lancet Infect Dis* 16: 797-808.
2. WHO Hepatitis C Fact Sheet (2017).
3. National Center for HIV/AIDS, Viral Hepatitis, STD and TB Prevention (2014) USA.
4. European Association for the Study of the Liver (2017) EASL Recommendations on Treatment of Hepatitis C 2016. *J Hepatol* 66: 153-194.
5. Easterbrook P, Johnson C, Figueroa C, Baggaley R (2016) HIV and Hepatitis Testing: Global Progress, Challenges, and Future Directions. *AIDS Rev* 18: 3-14.
6. Easterbrook PJ, WHO Guidelines Development Group (2016) Who to Test and How to Test for Chronic Hepatitis C Infection - 2016 WHO Testing Guidance for Low- and Middle-Income Countries. *J Hepatol* 65: S46-S66.
7. Fiddes R, Khattab M, Abu Dakka M, Al-Khaffaf H (2010) Patterns and Management of Vascular Injuries in Intravenous Drug Users: A Literature Review. *Surgeon* 8: 353-361.
8. Kral AH, Bluthenthal RN, Erringer EA, Lorvick J, Edlin BR (1999) Risk Factors Among IDUs Who Give Injections to or Receive Injections from Other Drug Users. *Addiction* 94: 675-683.
9. Coffin PO, Coffin LS, Murphy S, Jenkins LM, Golden MR (2012) Prevalence and Characteristics of Femoral Injection Among Seattle-Area Injection Drug Users. *J Urban Health* 89: 365-372.
10. Miller PG, Lintzeris N, Forzisi L (2008) Is Groin Injecting An Ethical Boundary for Harm Reduction? *Int J Drug Policy* 19: 486-491.
11. Higgs P, Dwyer R, Duong D, Thach ML, Hellard M, et al. (2009) Heroin-Gel Capsule Cocktails and Groin Injecting Practices Among Ethnic Vietnamese in Melbourne, Australia. *Int J Drug Policy* 20: 340-346.
12. Mason S, Watts A, Sheils S, Koorey D (2007) Improving Access to HCV Treatment: External Jugular Venipuncture Can Overcome Problems with Difficult Venous Access. *Int J Drug Policy* 18: 433-436.
13. Castro E (2014) External jugular venipuncture protocol. Medical direction proceedings. University Hospital of Lausanne (CHUV), Lausanne, Switzerland.
14. Lafferty K, Greene T, McNamara RM (2006) Femoral Phlebotomy: The Vacuum Tube Method is Preferable Over needle Syringe. *J Emerg Med* 31: 83-85.
15. Stickle BR, McFarlane H (1997) Prediction of a Small Internal Jugular Vein by External Jugular Vein Diameter. *Anaesthesia* 52: 220-222.