

# A Case of Incidental Diagnosis of Renal Cell Carcinoma by Endoscopic Ultrasound

Vikrant Parihar\*, Roisin Stack, Alaa Alakkari and BM Ryan

Gastroenterology Department, Tallaght Hospital, Dublin, Ireland

\*Corresponding author: Vikrant Parihar, Gastroenterology department, Tallaght hospital, Dublin-24, Ireland 00353-414200, Tel: 877400354; E-mail: [vikpar37@yahoo.com](mailto:vikpar37@yahoo.com)

Received date: 28 May 2016; Accepted date: 12 Aug 2016; Published date: 17 Aug 2016.

Citation: Parihar V, Stack R, Alakkari A, Ryan BM (2016) A Case of Incidental Diagnosis of Renal Cell Carcinoma by Endoscopic Ultrasound. *Int J Nephrol Kidney Fail* 2(4): doi <http://dx.doi.org/10.16966/2380-5498.137>

Copyright: © Parihar V, et al. This is an open-access article distributed under the terms of the Creative Commons Attribution License, which permits unrestricted use, distribution, and reproduction in any medium, provided the original author and source are credited.

## Abstract

We herein report a case of Renal Cell Cancer (RCC) picked up incidentally with an Endoscopic Ultrasound (EUS) in a patient with a very recent normal Transabdominal ultrasound (TAUS). The mass was successfully resected surgically.

**Keywords:** Renal cell carcinoma; Endoscopy; Ultrasound

## Introduction

TAUS is generally accepted as a preliminary test for renal masses [1] but the quality can be impaired in obese patients. In one study the detection rate with conventional TAUS was 71 % [2].

## Case Report

A 55 year old male with a prior history of cholecystectomy for symptomatic gall bladder stones six years previously presented with ongoing pain in the right hypochondrium of several months duration. He denied back pain, dysuria, hematuria or weight loss. On examination he had abdominal obesity with raised BMI (40 Kg/M<sup>2</sup>) but otherwise appeared healthy with a normal abdominal examination. His biochemical profile including full blood count and renal function were all within range. TAUS done in another institution six months earlier had been reported as normal and a subsequent gastroscopy showed uncomplicated Barrett's oesophagus. Given the location of pain and history of gallstones a EUS was performed to further evaluate the biliary tree. During the EUS he was noted to have a poorly defined hypoechoic hyper vascular mass in the right para duodenal region (Figure1a). The right kidney itself could not be seen and determination of exact size and origin of the lesion was not possible due to its large size which on a number of views was greater than the field of the ultrasound. Involvement of the Inferior vena cava (IVC) was suspected with mobile vegetative lesions seen in the IVC. Same day CT abdomen (Figure1b) showed a 9.8 × 12 cm right renal mass predominantly at the upper and interpolar area of the kidney. There was involvement of the right renal vein with early extension of the thrombus into the inferior vena cava. His CT thorax did not reveal any metastasis. Clean catch urine sample after EUS revealed microscopic hematuria. Following discussion at MDT meeting he underwent an open right radical nephrectomy with a curative intent. Follow-up scanning with a CT scan every 3 months hasn't revealed any disease recurrence to date.

Most of the incidentally diagnosed renal masses for imaging carried out for non-urological indications are likely early stage RCC. However our patient had a locally advanced RCC (pT3) which had previously been missed on TAUS.

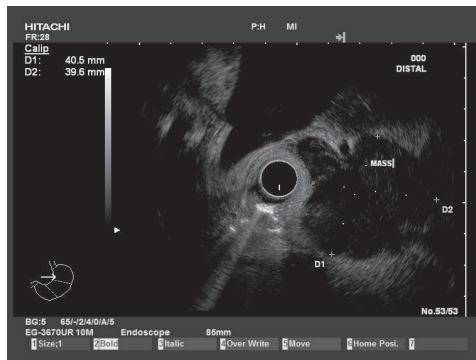
## Discussion

Tumors of the kidney are the third most common malignancy of the genitourinary system following that of reproductive and urinary system with around 39,900 new cases diagnosed each in the United States [3]. RCC accounts for over 90% of malignant kidney tumors and is usually unifocal with a single mass in one of the kidneys. Early diagnosis is key to cure [4]. Biopsy of renal tumors is usually avoided due to concern for needle tract seeding [5] and potential for complications such as bleeding, infection and arteriovenous fistula. However biopsy is indicated in selected cases where the diagnosis is not clear and needs to be differentiated from a renal abscess or infected cyst, or when RCC must be differentiated from metastatic malignant disease or renal lymphoma [6]. The risk of needle track seeding is minor but it should be balanced against the need for tissue diagnosis in certain cases [7].

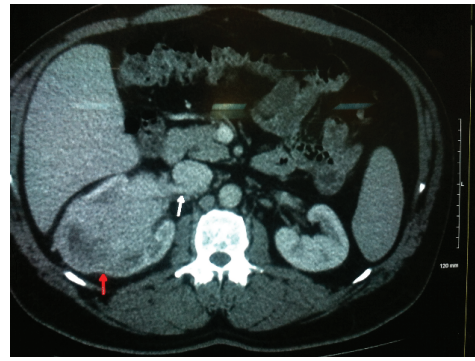
The anatomic location of both kidneys allows excellent endosonographic evaluation with the movement of the probe in the stomach or duodenum sufficient to visualize both kidneys. The proximity of the EUS tip to the kidneys from within the gastrointestinal tract allows for accurate access for tissue acquisition if required. However a study from teaching hospitals in the U.S. showed EUS biopsy of renal masses is rarely performed [8]. In most cases diagnosis of RCC will be based on imaging characteristics but renal biopsy is indicated in selected cases. Where tissue is required, EUS guided renal biopsy is best applied to central anterior renal masses, while in tumors on the posterior aspect of the kidney, percutaneous access is probably superior [9].

## Conclusion

We accept that the case report describes an incidental finding during EUS, which cannot be used to screen for RCC. But at the same time it offers an alternate modality for examinations of renal masses especially in obese individuals, or those with altered surgical anatomic alterations. We recommend that in every EUS examination, endosonographers should pay attention to possible renal lesions and include renal abnormalities in their reports. This technique appears safe and feasible and should be considered when results would affect patient management. Further reports will clarify the use of EUS in the diagnosis and treatment of RCC.



1a - EUS



1b - CT abdomen

**Figure 1:** EUS showing a mass lesion (1a) with further clarification on CT abdomen (1b) showing the mass (red arrow) and its extension into the renal vein (white arrow).

## References

1. Tosaka A, Ohya K, Yamada K, Ohashi H, Kitahara S, et al. (1990) Incidence and properties of renal masses and asymptomatic renal cell carcinoma detected by abdominal ultrasonography. *J Urol* 144: 1097-1099.
2. Dong XQ, Shen Y, XuLW, XuCM, BiW, et al. (2009) Contrast-enhanced ultrasound for detection and diagnosis of renal clear cell carcinoma. *Chin med J(Engl)* 122: 1179-1183.
3. Kosary CL, Mc Laughlin JK (1993) Kidney and renal pelvis. In: Miller BA, Ries LAG, Hankey BF (eds) *SEER Cancer Statistics Review, 1973-1990*. National Cancer Institute, Bethesda, Maryland, USA.
4. Robson CJ, Churchill M, Anderson W (1969) The results of radical nephrectomy for renal cell carcinoma. *J Urol* 101: 297-301.
5. Goethuys H, Van Poppel H, Oyen R, Baert L (1996) The case against fine-needle aspiration cytology for small solid kidney tumors. *Eur Urol* 29: 284-287.
6. Campbell SC, Novic AC, Burowski RM (2007) *Renal tumors*. Campbell-Walsh Urology, 9<sup>th</sup> edition, Elsevier, New York, USA.
7. Artifon EL, Lopes RI, Kumar A, Lucon AM, Dall'oglio M, et al. (2008) Endoscopic ultrasound facilitates histological diagnosis of renal cell cancer. *J Endourol* 22: 2447-2450.
8. DeWitt J, Gress FG, Levy MJ, Hernandez LV, Eloubeidi MA, et al. (2009) EUS-guided FNA aspiration of kidney masses: a multicenter U.S. experience. *Gastrointest Endosc* 70: 573-578.
9. Roberto Iglesias Lopes, Renata Nobre Moura, Everson Artifo (2015) Endoscopic ultrasound-guided fine-needle aspiration for the diagnosis of kidney lesions: A review. *World J Gastrointest Endosc* 7: 253-257.