

Anti N-methyl-d-aspartate (NMDA) Receptor Encephalitis with Frustrated Diagnosis Course: A Case report

Huanquan Liao[#], Hongyan Zhou[#] and Ling Chen^{*}

Department of Neurology, First Affiliated Hospital, Sun Yat-Sen University, Guangzhou, China

[#]These authors contributed equally

Corresponding author: Ling Chen, MD, PhD, Department of Neurology, First Affiliated Hospital, Sun Yat-Sen University, No.58 Zhongshan Road 2, Guangzhou 510080, China, E-mail: sumsdiy@163.com

Received date: 28 Sept 2015; **Accepted date:** 10 Nov 2015; **Published date:** 16 Sept 2015.

Citation: Liao H, Zhou H, Chen L (2015) Anti N-methyl-d-aspartate (NMDA) Receptor Encephalitis with Frustrated Diagnosis Course: A Case Report. *J Neurol Neurobiol* 2(1); doi <http://dx.doi.org/10.16966/2379-7150.116>

Copyright: © 2015 Liao H, et al. This is an open-access article distributed under the terms of the Creative Commons Attribution License, which permits unrestricted use, distribution, and reproduction in any medium, provided the original author and source are credited.

Abstract

Anti-N-methyl-D-aspartate (NMDA) receptor encephalitis is a rare disease with uncertain etiology and pathogenesis that affects young women. Its diagnosis can be delayed because of the nonspecific neuropsychiatric symptoms in the foreground. This article describes the details of a recent complicated case of a patient with this condition which is related to an ovarian teratoma. Correct diagnostic and prompt treatment of anti-NMDA receptor encephalitis remains a serious clinical challenge due to its unspecific manifestations and varying response to treatments. The information will be of interest to clinicians working with encephalitis patients.

Keywords: Anti-NMDA receptor encephalitis; Ovarian teratoma

Background

Ovarian teratoma-related anti N-methyl-d-aspartate (NMDA) receptor encephalitis is a rare disease with uncertain etiology and pathogenesis. The signs and symptoms are often nonspecific, which makes the diagnosis difficult. Herein, the author presents a case of anti-NMDA receptor encephalitis with frustrated diagnosis course.

Case Report

The patient, a 28-year-old maternal female from Guangdong province, suffered headache, insomnia and fever (ever highest body temperature 41.0°C) since January 07 2014. Upon the onset of the symptoms, he was once treated as an out-patient in a local clinic with unknown diagnoses and therapy and the symptoms were relieved. However, she appeared to be unresponsive with fewer words and became anxious since February 13 2014.

After her hospitalization in a local countryside hospital, she was diagnosed as “anxiety” and given anti-anxiety treatment, yet the improvement was still dissatisfied. From February 20 2014 on, during her hospital stay, she started to suffer frequent general tonic clonic seizures and was treated by depakine. Since February 25 2014, the patient suffered from persistent consciousness. Skull CT revealed brain edema. She was given trachea intubation, along with anti-infection, dehydration, sedation and other treatment, but the condition was not improved.

Consequently, on February 27 2014, she was transferred to a municipal hospital. Examination of cerebrospinal fluid (CSF) by lumbar puncture revealed no abnormalities in biochemical indicators. The CSF pressure was 120 mm H₂O, and leucocytes concentration was 45 × 10⁶/L. Electroencephalographic (EEG) investigation revealed medium-diffused abnormalities with slow waves. The patient was initially diagnosed with viral encephalitis and treated with methylprednisolone (anti-inflammatory), human gammaglobulin, mannitol, phenobarbital, valproate, levetiracetam, and chloral hydrate (anti-epileptic). However, the symptoms did not improve, and the seizures worsened. On March 24 2014, she was transferred to a provincial hospital. Brain magnetic resonance

imaging (MRI) revealed bilateral symmetric abnormal signals in the lenticular nuclei areas (Figure 1). She was treated with similar diagnoses and therapies, but the mental and epileptic symptoms exacerbated.

On May 14 2014 the patient arrived to the emergency room of the Neurology Department in our hospital for further diagnosis and treatment. After hospitalization, more detailed examination was undertaken. The parameters of routine blood test, blood clotting test, liver and kidney function test, blood glucose level, electrolytes level, routine urine and stool tests, erythrocyte sedimentation rate, and C-reactive protein were normal. The tests for infectious diseases (hepatitis B, syphilis, and human immunodeficiency virus) were negative. Immune indexes (antinuclear antibody, extractable nuclear antigen, and anticardiolipin) were within the normal range. EEG investigation revealed medium-diffused abnormalities. The treatment regiment described above was continued. On May 22 2014, the lumbar puncture and the CSF examination were carried out again. The CSF pressure was 140 mm H₂O, leucocytes level was 2 × 10⁶/L, and biochemical indicators were normal. Pandy's test, tests for Gram-negative bacilli, Gram-negative cocci, acid-fast bacilli, and *Staphylococcus aureus*, and T-spot were negative. The immunoglobulin-G index was within normal limits and anti-aquaporin 4 antibodies were not detected. Diazepam and midazolam were terminated. Levetiracetam, chloral hydrate, phenobarbital, and clonazepam were prescribed for controlling the seizures. With regard to tumor markers, we noticed that CA125 (71.89 U/mL) was relatively high, so B-mode ultrasonographic investigations of pancreas, spleen, thyroid, and kidneys, and chest X-ray were performed. The additional imaging examination of pelvic computed tomography (CT) scan revealed (Figure 2) a low density mass (15 × 10 × 17 mm) in the right ovary, consistent with the diagnosis of teratoma. The possibility of anti-NMDA receptor encephalitis was considered at this point. The second lumbar puncture and CSF examination were done on May 30 2014. CSF was sent to the Laboratory of Neurology, Third Affiliated Hospital of Sun Yat-sen University to check for NMDA receptor antibodies (Figure 3). NMDA receptor antibodies test was positive in CSF (1:1), so the patient was finally diagnosed with anti-NMDA receptor encephalitis. The patient was sent to the Department of Gynecology. The

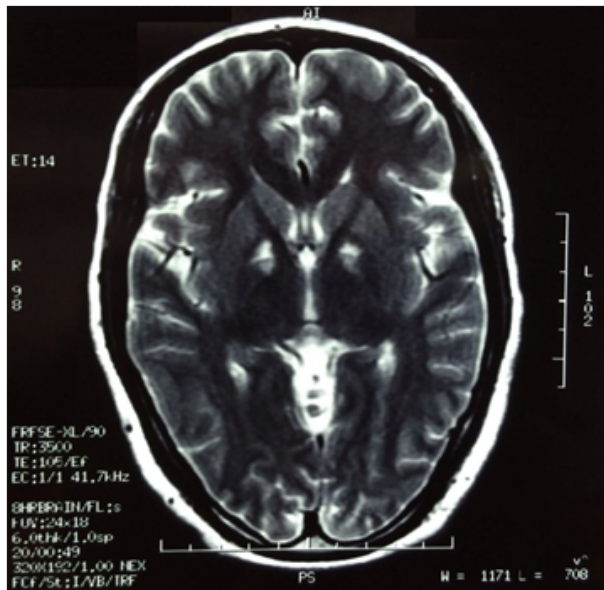


Figure 1: Brain MRI revealed bilateral symmetric abnormal signals in the lenticular nucleus areas

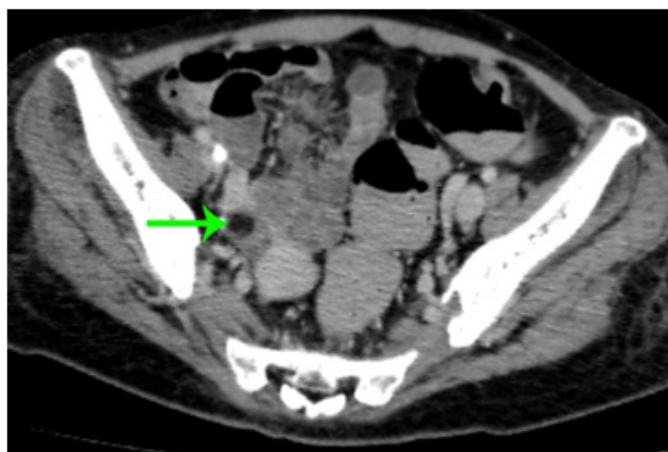


Figure 2: Pelvic CT scan revealed right ovary teratoma(Arrow).

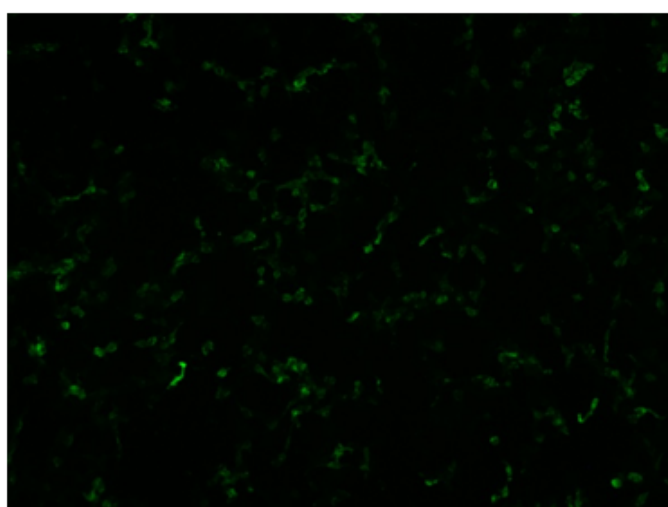


Figure 3: Indirect immunofluorescence of NMDA receptor antibodies.

laparoscopic cystectomy in the right ovary was performed on June 18 2014. Postoperative pathological examination confirmed the diagnosis of mature cystic teratoma in right ovary (Figure 4). After surgery, the patient's frequency of seizures can be reduced. However, due to severe pulmonary infection, the patient finally died of septic shock.

Discussion

Our reported patient had the prodromal symptoms of headache and fever at the beginning. Days later, seizure symptom developed. After CSF examination, she was diagnosed as encephalitis. The treatment with antiviral and anti-inflammatory drugs did not improve the symptoms, which gradually got worse. During the active treatment, organic diseases were excluded by the first imaging examination. Eventually, anti-NMDA receptor encephalitis was considered, and the anti-NMDA receptor antibodies were detected in CSF confirming the definite diagnosis.

Encephalitis is an acute or chronic inflammatory disease of the central nervous system. Limbic encephalitis (LE) is an inflammatory condition related to the hippocampus, amygdaloid, and insular cortex. LE is subdivided into three categories depending on whether it is caused by viral infections, mediated by autoantibody, or concomitant to autoimmune diseases [1].

The pathogenesis of this disease is not clear, and different possibilities have been suggested. Some authors suggest that a tumor or a viral infection triggers the immunological response [2]. Most cases are probably immune mediated, the best evidence for which comes from the demonstration of antineuronal antibodies in the CSF and serum of patients. These antibodies react with neuronal proteins that are usually expressed by the patients' tumour, and their detection is the basis of useful diagnostic tests [3,4].

At presentation, about half of the patients have abnormal MRI findings, most commonly increased signal on fluid-attenuated inversion recovery (FLAIR) in the cerebral or cerebellar cortex without significant clinical correlation [5]. CT scans and ultrasound examinations are generally used to check for tumors, and ovarian teratoma is found in the majority of patients. On EEG examination, diffuse delta waves or epilepsy waves could be seen during no reaction stage and excessive movement stage [6]. CSF examination shows abnormalities, mainly in the form of nonspecific inflammatory reactions, in 80 % of patients at early stages [2]. NMDA receptor antibodies could be detected in serum and CSF [7].

The differential diagnosis condition may present in the domain of either the neurologist or the psychiatrist, depending on whether psychiatric symptoms precede the neurological features, as is often the case. In the course of diagnostics, other viral and autoimmune diseases, metabolic, toxic, and other types of paraneoplastic limbic encephalitis (such as anti-AMPA receptor encephalitis [8] and anti-GABA receptor encephalitis [9]) should be excluded, and the presence of NMDA receptor antibodies should be confirmed in the serum and CSF. All patients should be examined for the presence of tumors, especially ovarian teratoma or testicular germ cell cancer.

Based on an extensive review, Dalmau and colleagues proposed an algorithmic strategy to guide treatment [7]. The first line of immunotherapy consists of corticosteroids, intravenous immunoglobulins, and plasma exchange (alone or in combination). The second line of immunotherapy (rituximab or cyclophosphamide or both) is usually needed in the case of a delayed diagnosis or in the absence of a tumor [7,10]. Patients usually start to gradually improve within 2-3 weeks of tumor removal and immunotherapy. The persistence of high CSF antibody titers suggests the need for continuation of treatment. Compared with other types of paraneoplastic encephalitis, the prognosis for anti-NMDA receptor encephalitis is better [11]. Dalmau [7] reported that approximately 75 %

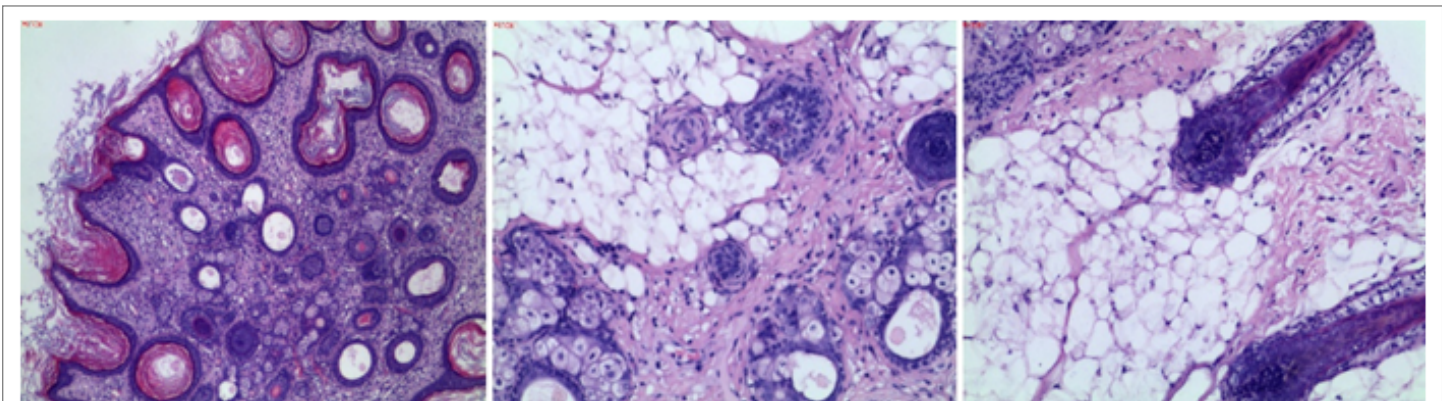


Figure 4: Postoperative pathological examination confirmed the diagnosis of mature cystic teratoma in right ovary.

of patients recover completely or only with minor disabilities. The rest of the patients remain serious ill or die.

Conclusion

Correct diagnostic and prompt treatment of anti-NMDA receptor encephalitis remains a serious clinical challenge due to its unspecific manifestations and varying response to treatments. The possibility of anti-NMDA receptor encephalitis must be considered on the condition when the treatment with antiviral and anti-inflammatory drugs does not improve the symptoms, especially in young woman patients. Definite diagnosis requires anti-NMDA receptor antibodies detection in CSF or blood. Anti-NMDA receptor antibodies can be found well before the detection of tumor. The information will be of interest to clinicians working with encephalitis patients.

Conflict of Interest

This is a case report without any industry-sponsorship. All the authors report none to disclosures.

References

- Asztely F, Kumlien E (2012) The diagnosis and treatment of limbic encephalitis. *Acta Neurol Scand* 126: 365-375.
- Hughes EG, Peng X, Gleichman AJ, Lai M, Zhou L, et al. (2010) Cellular and synaptic mechanisms of anti-NMDA receptor encephalitis. *J Neurosci* 30: 5866-5875.
- Posner JB, Dalmau J (1995) Clinical enigmas of paraneoplastic neurologic disorders. *Clin Neurol Neurosurg* 97: 61-70.
- Vitaliani R, Mason W, Ances B, Zwerdling T, Jiang Z, et al. (2005) Paraneoplastic encephalitis, psychiatric symptoms, and hypoventilation in ovarian teratoma. *Ann Neurol* 58: 594-604.
- Dalmau J, Tuzun E, Wu HY, Masjuan J, Rossi JE, et al. (2007) Paraneoplastic anti-N-methyl-D-aspartate receptor encephalitis associated with ovarian teratoma. *Ann Neurol* 61: 25-36.
- Iizuka T, Sakai F, Ide T, Monzen T, Yoshii S, et al. (2008) Anti-NMDA receptor encephalitis in Japan: long-term outcome without tumor removal. *Neurology* 70: 504-511.
- Dalmau J, Lancaster E, Martinez-Hernandez E, Rosenfeld MR, Balice-Gordon R (2011) Clinical experience and laboratory investigations in patients with anti-NMDAR encephalitis. *Lancet Neurol* 10: 63-74.
- Lai M, Hughes EG, Peng X, Zhou L, Gleichman AJ, et al. (2009) AMPA receptor antibodies in limbic encephalitis alter synaptic receptor location. *Ann Neurol* 65: 424-434.
- Lancaster E, Lai M, Peng X, Hughes E, Constantinescu R, et al. (2010) Antibodies to the GABA(B) receptor in limbic encephalitis with seizures: case series and characterisation of the antigen. *Lancet Neurol* 9: 67-76.
- Hachiya Y, Uruha A, Kasai-Yoshida E, Shimoda K, Satoh-Shirai I, et al. (2013) Rituximab ameliorates anti-N-methyl-D-aspartate receptor encephalitis by removal of short-lived plasmablasts. *J Neuroimmunol* 265:128-130.
- Byrne S, McCoy B, Lynch B, Webb D, King MD (2014) Does early treatment improve outcomes in N-methyl-D-aspartate receptor encephalitis? *Dev Med Child Neurol* 56: 794-796.