

# Nutrition and Food Technology: Open Access

Research Article

Volume: 1.1

Open Access

## Differentiation between Normal and Abnormal Yellow Colour of Beef Carcasses in Sulaimani New Slaughterhouse

**San Arkan Manuchar<sup>1\*</sup>, Murad Hazhaow Omer<sup>2\*</sup>, and Heshu Rahman<sup>2,3</sup>**<sup>1</sup>Directorate of Veterinary, Veterinary Hospital, Sulaimani City, Kurdistan Region, Northern Iraq<sup>2</sup>College of Veterinary Medicine, University of Sulaimani, Sulaimani Nwe, Street 27, Zone 11, Sulaimani City, Kurdistan Region, Northern Iraq<sup>3</sup>Faculty of Veterinary Medicine, Universiti Putra Malaysia, 43300UPM, Serdang, Selangor, Malaysia**\*Corresponding author:** Hazhaow Muhamad Murad, College of Veterinary Medicine, University of Sulaimani, Sulaimani Nwe, Street 27, Zone 11, Sulaimani City, Kurdistan Region, Northern Iraq, Tel: + 9647701595663; **E-mail:** [hazhaow@gmail.com](mailto:hazhaow@gmail.com)**Received date:** 15 Sept 2015; **Accepted date:** 30 October 2015; **Published date:** 31 October 2015.**Citation:** Manuchar SA, Omer MH, Rahman H (2015) Differentiation between Normal and Abnormal Yellow Colour of Beef Carcasses in Sulaimani New Slaughterhouse. *Nutr Food Technol* 1(1): doi <http://dx.doi.org/10.16966/2470-6086.105>**Copyright:** © 2015 Manuchar SA, et al. This is an open-access article distributed under the terms of the Creative Commons Attribution License, which permits unrestricted use, distribution, and reproduction in any medium, provided the original author and source are credited.

### Abstract

The colour of meat and fat of carcasses have a great effect on consumers demand especially beef carcasses. The majority of beef carcasses have creamy-white to cream fat colour. Yellowness of fat is due to the presence of carotenoid pigments within adipocyte or due to certain diseases like jaundice. The significance of this study was to differentiate between normal and abnormal beef yellow carcasses by using chemical laboratory tests and scientific basics. For this purpose, sixty yellow carcasses had been examined through the period end of September 2013 to the end of March 2014. The fat samples obtained from different parts of the carcasses and through the Rimmingtone and Fowri chemical tests, the actual cause of yellowness was determined. These results approved that the sex has a major effect on carotenoid deposition in the majority of the carcasses. Therefore, jaundice cases were determined for the first time in Sulaimani slaughter house chemically. Miss diagnosis of carotenoid carcasses as jaundice case causes a greater economic loss and its necessary to make Rimmingtone and Fowrie Tests as a routine laboratory tests in Sulaimani Slaughter houses for differentiation.

**Keywords:** Jaundice; Chemical test; Sulaimani slaughterhouse; Beef carcass

### Introduction

Red meat contains high biological value proteins, range of fats and important micronutrients that are needed for good health throughout life. Purchased red meat usually consists of both lean tissue (muscle) and fat tissue, which can be either distributed throughout the muscle as marbling (internal fat) or surrounding the muscle meat as selvage or external fat [1].

The colour of bovine subcutaneous adipose tissue (carcass fat) is an important component of beef carcass quality and thus, beef carcass grading systems [2]. In most beef markets, excessive yellowness in bovine carcass fat colour is undesirable [3].

Consumers usually prefer white fat in finished beef, and some export markets place high value on colour of fat in cuts of beef [4]. Beef fat normally has white to creamy white colour [5]. Morgan Everitt [6] approved that yellowness of fat is due to the presence of carotenoid pigments within adipocytes or due to certain diseases. Beta carotene, is a major precursor of vitamin A, and is the main contributing carotenoid pigment in beef fat although trace amounts of alpha-carotene and xanthophylls have also been found. According to Herenda et al. [7] icterus is the result of an abnormal accumulation of bile pigment, bilirubin, or haemoglobin in the blood. Yellow pigmentation is mainly observed in the skin, internal organs, sclera (the white of the eye), tendons, cartilage, arteries, joint surfaces, which is a clinical sign of a faulty liver or bile duct malfunction, but it may be also caused by diseases in which the liver is not impaired and divided into three main categories; Pre-hepatic jaundice (haemolytic icterus), hepatic jaundice (toxic icterus) and post-hepatic jaundice (obstructive icterus).

In Sulaimani slaughterhouse, the routine inspection for the suspected yellow carcasses depends on naked -eye and experience of the inspector.

So the aim of this study was to differentiate between the yellow carcasses which may be due to carotene accumulation or icterus by using chemical tests as laboratory examination for confirmation.

### Material and Methods

#### Materials

- Sodium hydroxide (Merk, Germany)
- Di ethyl Ether (PARS Chemi, India)

#### Sampling

Fat samples were obtained from different location of (60) suspected beef carcasses (male and female), in 15 days through the period (End of September/2013 to the end of March/2014) from Sulaimani slaughterhouse. Samples were placed in a close glass containers, then transferred to the laboratory in Sulaimani Slaughter house immediately for analysis.

#### Methods

Two gram of fat samples was placed in test tube and 5 mL of a 5% of NaOH were added. The mixture was boiled for about 1 minute, and shaken frequently until the fat was dissolved. Then the test tubes were cooled under the tap water till it was comfortably warm to the hand. An equal volume of ether was added and mixed gently. The mixer allowed settling down. The solution settled out in to layers [8].

#### Interpretation of the test

- The bile salt is soluble in water, so if the color was due to jaundice; the bottom layer will be colored yellow.

- b. If the color was due to carotene, the top layer colored yellow, as these are soluble in ether. The judgment was easier when test tube viewed against a white back-ground.

## Results

Table 1 shows the percentage number of cases according to the carotene and jaundice. The result revealed that at the (day 4 and day 13) of the study the percentage of slaughtered animals with carotene case were high, while jaundice cases were high at the (day 12). Figure 1 shows the percentage number of carotenoid cases according to the breed. The number of local breeds (Sharabi-Sub breed Karadi) slaughtered in Sulaimani slaughterhouse were higher than foreigners one, where Figures 2a and 2b which shows the percentage of cases with carotene and jaundice results according to the animal sex. In carotene cases; a high percentage recorded in females, while in jaundice cases male percentage were high. In Table 2, the results revealed both of carotenoid and jaundice cases were high in outdoor feeding animals.

Table 3 shows the regression analyses of four factors on carotenoid and jaundice yellow beef carcasses. It was found that there is negative relationship between all included independent variables (sex, breed, age and diet) on the one hand, and the carotenoid in the other.

While Figure 3 shows positive result for icterus (jaundice), by using Rimmingtone and Fowrie tests, the result showed that the bottom layer had yellow colour, while the top had white. Where Figure 4 shows positive result for carotene by using Rimmingtone and Fowrie tests, and the result indicated that the top layer had yellow colour, while the bottom layer had white colour. Figure 5 shows the carotenoid cases features among other cases in Sulaimani Slaughterhouse, whereas Figure 6, shows the features of jaundice, carotenoid, and normal carcasses. In the icteric cases, all part of the carcass had yellow colour (body fat, tendon, internal organ, white tissue), while in carotenoid carcass, only body fat had yellow colour. In Figure 7 which show ictric (jaundice) carcasses with internal organ, and illustrate the yellow colour in internal organ (liver, kidney, lungs, heart fat). Then Figure 8 shows the foreign breed of beef (Brahman) in Sulaimani slaughterhouse and Figure 9 demonstrates the local breed of beef (Sharabi-Sub Karadi).

## Discussion

In the routine postmortem examination in Sulaimani slaughterhouse, animals with yellow colour were treated as “suspects” on examination;

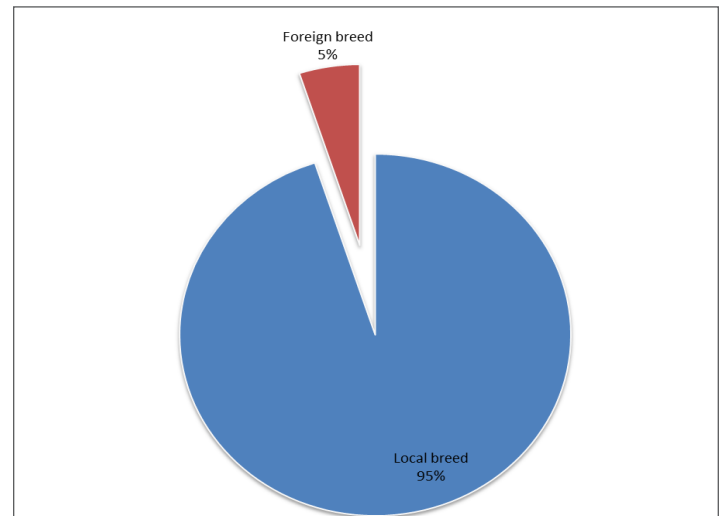
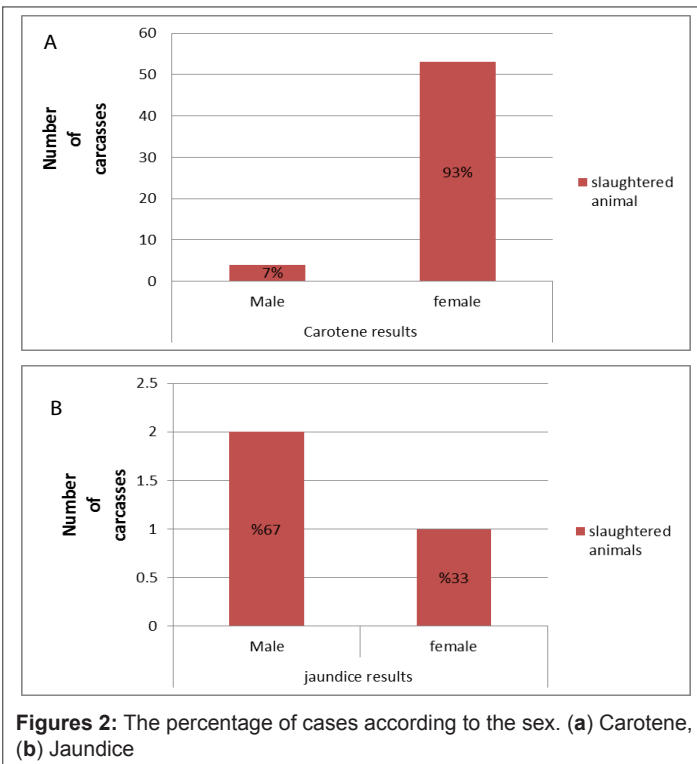


Figure 1: The percentage of carotenoid cases according to the breed

judgment depends on inspector choice by naked eye and experience. The percentage of cases according to the carotene and jaundice, had been shown in Table 1, which revealed that the carotenoid carcasses had high value in day (4 and 13) of inspection (22/10/2013 and 5/3/2014), those two days marked the October and March in this study. In our province, it has been well known that March is the beginning of the spring season, and the pastures had been developed, so the outdoor feeding started again. For November the same results could be true, as reported by Yang et al. [9] Strachan et al. [10] inclusion of grazed or conserved grass in cattle diets lead to yellow coloured carcass fat because such forages are rich sources of the compounds responsible for yellowness, namely  $\beta$ -carotene. While in winter the animals spent longer period on a conventional indoor ration and become less yellow in colour [11]. The jaundice cases usually occur as a disease case not depending on the season, this is mainly due to causative agent. Carotenoids are relatively unstable and as soon as grass appears to have dried, their concentration much reduced. Most grains contain only small concentrations of carotenoids. This is why colour decreases when cattle are fed in feedlots fat. Beta-carotene is only a minor component (about 5-8%) of the total carotenoids in plants. However, it is selectively absorbed, accounting for more than 80% of the yellow pigments present in beef fat with carotenoid cases [12].

Month	Day	No. of Slaughtered animals	No. of cases with carotene	%	No. of cases with jaundice	%
September	Day 1	146	5	3.4%	1	0.68%
October	Day 2	91	2	1.36%	0	0
October	Day 3	110	4	3.6%	0	0
October	Day 4	49	5	10.2%	0	0
January	Day 5	102	2	1.96%	0	0
January	Day 6	127	5	4.72%	0	0
February	Day 7	165	4	2.42%	0	0
February	Day 8	127	6	4.72%	0	0
February	Day 9	91	1	1.09%	0	0
February	Day 10	83	2	2.4%	0	0
March	Day 11	100	3	3%	1	1%
March	Day 12	73	3	5.47%	1	1.36%
March	Day 13	95	8	8.42%	0	0
March	Day 14	97	2	2.06%	0	0
March	Day 15	107	5	4.67%	0	0
	Total	1573	57		3	

Table 1: The percentage of examined cases according to the carotene and jaundice



**Figures 2:** The percentage of cases according to the sex. (a) Carotene, (b) Jaundice


otene results		Jaundice results	
Indoor	Outdoor	Indoor	Outdoor
3	54	0	3
7%	93%	0%	100%

**Table 2:** The percentage of carotene and jaundice cases according to the feed source


Variables	Coefficients	Standard Error	T-test	P- value
Intercept	1.0946	0.1948	5.6172	6.62E-07
Sex Male=1, Female=0	-0.3164	0.1121	-2.8206	0.00665
Breed local=1, foreign=0	-0.0442	0.1167	-0.3788	0.7062
age (years)	-0.0130	0.0205	-0.6330	0.5293
Diet outdoor=1, indoor=0	-0.0108	0.1499	-0.0721	0.9427
R square	14%			
F-Test	2.16			

**Table 3:** The regression analysis of carotenoid and jaundice yellow beef carcasses according to variable factors

Figure 1 shows that the number of carotenoid cases, is higher in local breed than foreigners, which is well distinguished in Figures 8 and 9, this could be due to that the local breed (Sharabi) has the ability to deposit  $\beta$ -carotene in their fat more than that of the foreign breed (Brahman). The intensity of fat depend on breed; [6] Morgan and Everitt, 1969 also agreed with that in their study, where they claimed that fat colour intensity and carotene levels were higher in the Jersey than in Friesian and Aberdeen Angus cattle. While Kruk et al. [13] discovered that pure Jersey -cows had higher  $\beta$ -carotene concentrations in their subcutaneous adipose tissue than either Jersey Limousin or pure Limousin cows. Figure 2a shows number of cases with carotene according to the animal sex, which in carotene cases a high percentage recorded in females. Walker et al. [3] also reported that females had yellower subcutaneous fat than steers. Barton



**Figure 3:** Positive result for icterus (jaundice) (Rimmingtone and Fowrie tests)



**Figure 4:** Positive result for carotene (Rimmingtone and Fowrie tests)

and Pleasants, [14], who compared different breeds of steers rose on pasture and slaughtered at 30 months of age, and found that beef breeds had significantly more carcasses with white fat than dairy breed carcasses and the Jersey breed had more with yellow fat carcasses than any other breed. There is a great effect of lipid metabolism on the colour of bovine carcass fat during lactation. Lactogenesis in ruminants is a lipid metabolism where by lipolysis increases and lipogenesis decreases in adipose tissue [15]. Dunne et al. [16], claimed that the high concentration of carotene in the dairy cows was due to accumulation of carotenoid through the life of cow coupled with intermittent periods of lipid depletion coincident with lactations and produce the yellow adipose tissue of old dairy cows. Where Figure 2b showed that the numbers of jaundice cases were high in male (67%) than female, this could be due to that jaundice is a disease case which

may relate to parasitic, hepatic or obstructive condition. According to Table 2, there was a high value of carotenoid cases in outdoor beef, as mentioned before the outdoor feed contain grass and green forage, while indoor feeding mainly contain grain, maize silage would decrease the yellowness of adipose tissue and have little effect on the sensory characteristics of beef as approved by [17], who used cereal based concentrate instead grass silage in the ration of beef cattle. Feeding concentrates produces subcutaneous adipose tissue which is less yellow than that from cattle fed diets containing forage [10,18]. The same fact was also recommended by Yang et al. [19] who reported that cattle predominantly pasture fed tended to accumulate  $\beta$ -carotene in subcutaneous and intramuscular fat. Simonne et al. [20] reported Japanese Black steers are fed roughage containing little  $\beta$ -carotene to avoid producing yellow body fat, especially subcutaneous fat. Because not all of the ingested and absorbed carotene is transformed into vitamin A, the surplus is present first in the blood and then deposited in adipose and hepatic tissues, where it accumulates. As a result, yellow fat is frequently observed in the carcasses of pasture-fed animals [6,10,19,21].

Unfortunately, the result revealed that more female are slaughtered in Sulaimani slaughterhouse than male local breed, which is against meat laws and legislations except in certain cases such as sterility or emergency [22]. The regression analyses of four factors on carotenoid and jaundice yellow beef carcasses, showed that there was negative relationship between the all included independent variables (sex, breed, age and diet) on the one hand and the carotenoid in the other, as shown in Table 3. More specifically, male sex variable has inverse impact on the dependent variable (carotenoid). So it is expected high status among females as been approved in Figure 2a, it's to be noted that according to (T-test) this variables is the only significance variables, apart from intercept coefficients. It was clear that the significance of other variables (except sex) can be attributed to the reality of the data which obtained from owners and size of data.

The positive result for jaundice, as been showed in Figure 3 which revealed the yellow coloration in bottom layer while the upper layer was white, this is due to that, bile salt are not soluble in water. Whereas Figure 4 revealed the positive result for carotene, with yellow top layer because carotene soluble in ether and that's why the bottom was white [8].

At daily routine inspection after slaughtering, the carotenoid cases appeared obviously among other carcasses due to specific yellow colour as shown in Figure 5. Icterus is the result of an abnormal accumulation of bile pigment, bilirubin, or haemoglobin in the blood. Yellow pigmentation is observed in the skin, internal organs, tendons, cartilage, arteries, joint surfaces [7], as shown in Figure 6, both jaundice and carotenoid and normal- white carcass appeared with quite differential between these two cases just at the slaughtering line of the slaughterhouse. In icteric case,

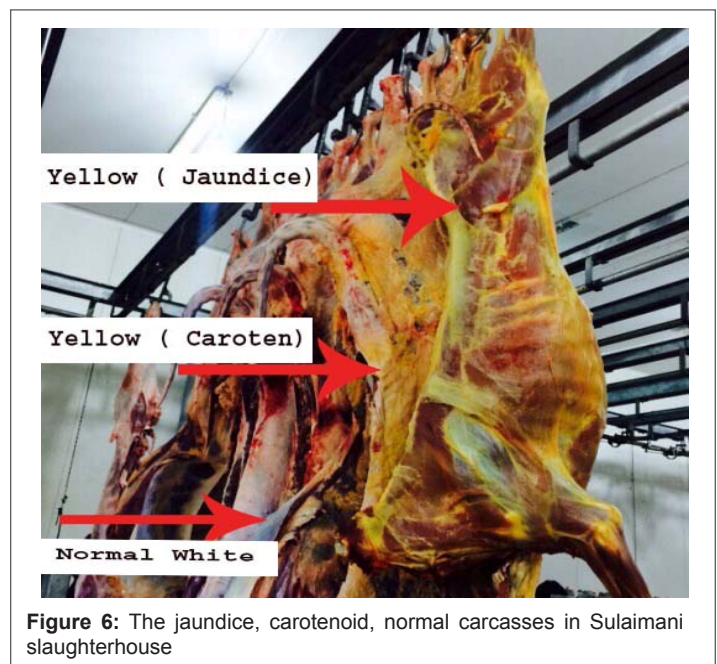


Figure 6: The jaundice, carotenoid, normal carcasses in Sulaimani slaughterhouse

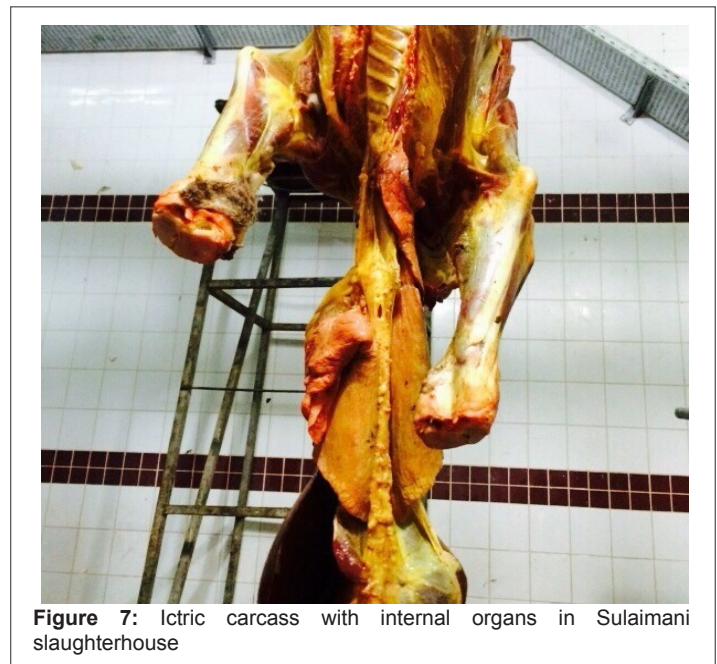


Figure 7: Icteric carcass with internal organs in Sulaimani slaughterhouse

the whole carcass white tissue colours were become yellow. While in carotenoid carcasses only the adipose tissue were have yellow colour [19]. Also Figure 7, revealed that the icteric carcass in Sulaimani slaughterhouse, the yellow colouration of the whole body and internal organ appear.

The foreign breed of beef (Brahman) in Sulaimani slaughterhouse, were came from India and Pakistan by transit throw Iran, Figure 8. Recognizing Brahman is easy because of its loose skin, large hump over the shoulders, and large drooping ears. Brahmans vary in color from light gray or red to almost black [23], whereas the local breed of beef (Sharabi), was easy to recognize in the abattoir as have been seen in Figure 9. The Sharabi is a cattle breed indigenous to the northern part of Iraq, it is small in size, black in colour and white line dividing the body along the abdomen, chest and back into two halves. Some white spots may be seen on the sides [24].



Figure 5: The carotenoid cases among normal cases in Sulaimani slaughterhouse



**Figure 8:** The foreign breed of cow (Brahman) in Sulaimani slaughterhouse



**Figure 9:** The local breed of cow (Sharabi –Sub breed Karadi) in Sulaimani slaughterhouse

## Conclusions

Miss diagnosis of carotenoid carcasses as jaundice case cause a greater economic loss and its necessary to adopt (Rimington and Fowrie tests) as a routine laboratory tests in Sulaimani slaughterhouse for differentiation. In male beef, we expected high jaundice case, so the male yellow carcasses are more suspected than females, because a regression result showed that this variable has negatively significance effect on carotenoid. The slaughtering of local breed females in Sulaimani slaughterhouse is higher than male which cause a great economic loss also its against the meat legislation and laws.

## Acknowledgements

We like to show our appreciation to College of Veterinary Medicine, Sulaimani University, and to Directorate of Veterinary of Sulaimani City for supporting this study. Many thanks to Dr. Heshu S.R. for her guidance and efforts.

## References

- Williams PG (2007) Nutritional composition of red meat. In: Wollongong UO (eds) *Medicine and Health*.
- Wood JD, Fisher AV (1997) Carcass and meat quality: definitions and measurements. In: *Effects of Extensification on Animal Performance, Carcass Composition and Product Quality*. Occasional Publication No.4 of Concerted Action AIR3-CT93-0947. Melle-Gontrode, Belgium.
- Walker PJ, Warner RD, Winfield CG (1990) Sources of variation in subcutaneous fat colour of beef carcasses. *Proceedings of the Australian Society of Animal Production* 18: 416-419.
- Trenkle A (2002) Relative Value of White Corn When Fed to Finishing Cattle and Its Effects on Color of Carcass Fat. *Beef Research Report-Iowa State University*.
- Morgan DS (1995) Quality and Grades of Carcasses of Meat of Animals. *United State of America*.
- Morgan JH, Everitt GC (1969) Some factors affecting yellow fat colour in Cattle. *New Zealand Society of Animal Production* 29: 164-176.
- Herenda D, Chambers PG, Ettriqui A, Seneviratna P, Da Silva TJ (2000) Manual on meat inspection for developing countries. FAO Corporate Document Repository.
- Wilson GW (2005) *Wilsons Practical Meat Inspection*, Oxford, UK, Blackwell Publishing.
- Yang A, Larsen TW, Tume RK (1992) Carotenoid and retinol concentrations in serum, adipose tissue and liver and carotenoid transport in sheep, goats and cattle. *Australian Journal of Agricultural Research* 43: 1809-1817.
- Strachan DB, Yang A, Dillon RD (1993) Effect of grain feeding on fat colour and other carcass characteristics in previously grass-fed *Bos indicus* steers. *Australian Journal of Experimental Agriculture* 33: 269-273.
- Boccard RL, Naude RT, Cronje DE, Smit MC, Venter HJ, et al. (1979) The influence of age, sex and breed of cattle on their muscle characteristics. *Meat Sci* 3: 261-280.
- AMPC & MLA (2006). *Meat Technology Update*. Food Science, Australia.
- Kruk ZA, Malau-Aduli AE, Pitchford WS, Bottema CD (1998) Genetics of fat colour in cattle. In: *Sixth World Congress in Genetics Applied to Livestock Production* 121-124.
- Barton RA, Pleasants AB (1993) Fat colour and meat colour in different breeds of steers in five consecutive years raised on pasture and slaughtered at 30 months of age. *Proceedings of the New Zealand Society of Animal Production* 53: 389-391.
- Swanson LV (1989) Discussion - Interactions of nutrition and reproduction. *Dairy Science* 72: 805-814.
- Dunne PC, Monahan FJ, Omara FP, Molone AP (2009) Colour of bovine subcutaneous adipose tissue: A review of contributory factors, associations with carcass and meat quality and its potential utility in authentication of dietary history. *Meat Sci* 81: 28-45.
- Moloney AP, Drennan MJ (2013) Characteristics of fat and muscle from beef heifers offered a grass silage or concentrate-based finishing ration. *Livestock Science* 152: 147-153.
- Forrest RJ (1981) Effect of high concentrate feeding on the carcass quality and fat colouration of grass reared steers. *Canadian Journal of Animal Science* 61: 575-580.
- Yang A, Brewster MJ, Lanari MC, Tume RK (2002) Effect of vitamin E supplementation on -tocopherol and B-carotene concentrations in tissues from pasture- and grain-fed cattle. *Meat Sci* 60: 35-40.
- Simonne AH, Green NR, Bransby DI (1996) Consumer acceptability and b-carotene content of beef as related to cattle finishing diets. *Food Sci* 61: 1254-1256.
- Mora O, Romano JL, González E, Ruiz FJ, Shimada A (2000) Low cleavage activity of 15,15-dioxygenase convert beta-carotene to retinol in cattle compared with goats, is associated with the yellow pigmentation of adipose tissue. *Int J Vitam Nutr Res* 70: 199-205.
- Gracey FJ, Collins DS, Huey JR (1999) *Meat Hygiene*. 10th edition, W.B. Saunders, London. n
- Riley DG, Chase CC, Hammond AC, Johnson DD, et al. (2014) Estimated genetic parameters for carcass traits of Brahman cattle. *J Anim Sci* 80: 955-962.
- Maarof NN (1992) Performance of Sharabi cattle. *Emir J Food Agric* 4: 110-119.