

# New Treatments for Age Related Macular Degeneration: The Role of Anti-Angiogenic Agents in the Treatment of Choroidal Neovascular Membrane - A Case of Recurrent Membrane

Hudson de Carvalho Nakamura\*

*Eye Bank Foundation of Goias, Brazil*

**\*Corresponding author:** Hudson de Carvalho Nakamura, Rua 13, Numero 45 Edificio Winner Torre I, Apto-1301, Jardim Goias Goiania Brazil, Tel: 556283427777; **E-mail:** [hudson.nakamuraeyemd@gmail.com](mailto:hudson.nakamuraeyemd@gmail.com)

**Received date:** 21 Mar 2016; **Accepted date:** 16 Apr 2016; **Published date:** 20 Apr 2016.

**Citation:** Nakamura HDC (2016) New Treatments for Age Related Macular Degeneration: The Role of Anti-Angiogenic Agents in the Treatment of Choroidal Neovascular Membrane - A Case of Recurrent Membrane. J Pharm Anal Insights 1(3): doi <http://dx.doi.org/10.16966/2471-8122.108>

**Copyright:** © 2016 Nakamura HDC. This is an open-access article distributed under the terms of the Creative Commons Attribution License, which permits unrestricted use, distribution, and reproduction in any medium, provided the original author and source are credited.

## Abstract

Age related macular degeneration is a common cause of blindness, and its worse manifestation, the choroidal neovascular membrane, can affect a person's quality of life, especially in the submacular form. The treatment of the membrane, in the past, was performed only with laser photocoagulation of the membrane, which reduced the risks of visual loss when treated without delay. If the membrane treated was located in the macula, central visual area, the outcome was bad despite treatment. Several studies ranging from the Macular Photocoagulation Studies to intraocular injections nowadays, proved that with prompt treatment with laser photocoagulation, the contrast sensitivity got better within a couple of years, better than leaving the lesion untreated. Recent studies show how the mechanisms of action of new developed drugs for the treatment of choroidal neovascular membranes, help improve patient's outcome.

Ancient treatments, still performed, such as Photodynamic Therapy acted on halting the growth of the membrane, but had to be repeated several times to achieve the results wanted. Another option that did not last long was Transpupillary Thermotherapy, with the use of nonthermal laser to treat the choroidal neovascular membrane; treatments such as macular translocation were carried out but had many complications related to the procedure, and were discontinued; clinical research in pharmacology showed vascular endothelial growth factor as a precursor of choroidal neovascular lesions.

So the development of pharmacological treatment for the membrane came to the most evolving drugs used in ophthalmology today, starting with pegaptanib sodium (Macugen) and other drugs under current studies such as bevacizumab (Avastin). Ranibizumab (Lucentis) is also used for the treatment of the disease, and Aflibercept (Eyleid) was approved and used in many clinical protocols. Corticosteroids were an option for the treatment of choroidal neovascular membranes, to mention triamcinolone acetate, Ozurdex (dexametasone implant), and Iluvien (fluocinolone acetone), these last one being delivered as intravitreal implant differently from the others mentioned, delivered as injections. Prompt diagnosis is desired as many patients arrive past the time of treating the membrane, which may worsen their outcomes. Clinical exam, Oct and Oct angiography are far more used nowadays. We hope to change that outcome understanding of mechanisms of action of these drugs and trying to develop new treatments as well as effective medications.

We show a case of subretinal neovascular membrane treated with bevacizumab that failed and developed a recurrent neovascular membrane, and a new treatment switching the medication was indicated.

**Keywords:** Age related macular degeneration; Choroidal neovascularization; Vascular endothelial growth factor; Intraocular injections; Intraocular implants

**Abbreviations:** ARMD: Age Related Macular Degeneration; CNV: Choroidal Neovascularization; VEGF: Vascular Endothelial Growth Factor; PDT: Photodynamic Therapy; PEDF: Pigment Epithelium Derived Factor; RPE: Retinal Pigment Epithelium; FDA: Food and Drug Administration; Oct: Ocular Computerized Tomography; FA: Fluorescein Angiography; OCTA: Oct Angiography; PDGFR: Protein Derived Growth Factor Receptors; PDGF: Protein Decided Growth Factor

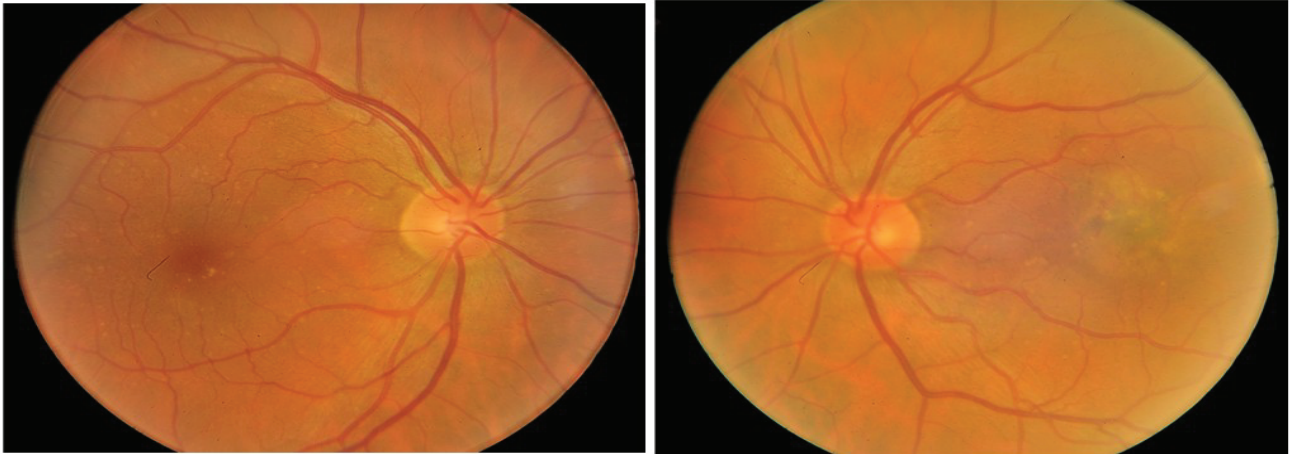
## Introduction

Age-related macular degeneration is the most common cause of severe vision loss in elderly persons in developed countries. Age related macular degeneration is a painless, irreversible, degenerative eye condition associated with the damage of photoreceptor cells (Figure1) [1].

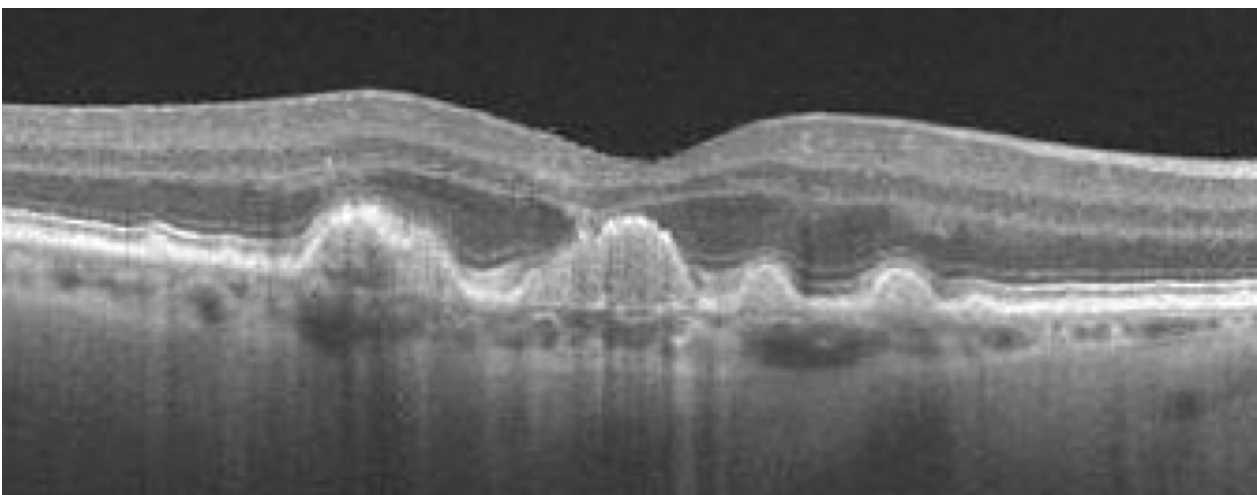
Two types of the disease are classified, dry and wet, the first being far more common, the latter usually worse and associated with metamorphosis and vision distortion, with loss of central vision. Various agents are used

for treatment, and prevention of the disease, and dietary and life style considerations may avoid complications of the disease, keeping a stable visual acuity and quality of life. Early identification of the disease is of great importance.

The choroidal neovascularization is the primary lesion of age-related macular degeneration to be treated. The membrane extends anteriorly through defects in Bruch's membrane (Figure 2) into the space below the retinal pigment epithelium and/or neurosensory retina, leading to fluid



**Figure 1:** Colour fundus photograph of the right and left eye, respectively, showing normal optic nerves but retinal pigment epithelial changes especially in the left eye, with was later diagnosed as choroidal neovascular membrane before treatment with infra ocular bevacizumab. Plus, the patient had metamorphosia in the left eye that motivated him to the consultation with the retina specialist.



**Figure 2:** Oct image showing how the choroidal neovascular membrane appears, breaking through the bruch's membrane towards the RPE

accumulation, bleeding or lipids in the subretinal space. Fibrous tissue may appear, causing central vision loss. The current macular degeneration related to age treatment in its exudative form is the main challenge in the world of ophthalmology.

Because of recent research into biomaterials and nanotechnology [2] major advances has been gained in the field of intraocular injections and delivery systems. New therapies [3,4] are recently presented to the patient in order to prevent neovascular age-related macular degeneration.

Several mechanisms have been proposed to explain these phenomena. Vascular endothelial growth factor (VEGF) [5-7] production when blocked lead to an increase in other angiogenic pathways as a compensatory mechanism, thus up-regulating VEGF production by macrophages within choroidal neovascular membranes [8,9].

Photodynamic therapy [10] is a modality is based on the fact that the choroidal neovascular membranes have tissue characteristics that differ from normal blood vessels in terms of retaining dye. The treatment, which uses a combination of drugs and laser therapy, a verteporfin

photosensitive compound that localizes to the target tissue is injected into a peripheral vein and excited with laser light of a specific wavelength. Activated verteporfin forms free radicals, and coagulation of the leaking vessels responsible for cellular injury ensues.

Thermal laser photocoagulation was the treatment of choice for many years in the management of patients with wet ARMD. In this procedure, the laser is directed toward the choroidal neovascular membrane, to destroy it. This procedure, however, has been associated with a high rate of recurrence [11].

Based on their histology, Gass classified CNVMs into Type 1 and Type 2. Type 1, the subepithelial CNV grows between the basement membrane of the RPE and the inner collagenous zone of Bruch's membrane [12]. The CNVs associated with punctate inner choroidopathy (PIC), presumed ocular histoplasmosis syndrome (POHS) and with other PSII are assumed to be Type 2 membranes; so called inflammatory membranes, and in Type 2, the CNV grows beneath the sensory retina, lying anteriorly to the RPE.

Other modalities [13-17] of treatment include macular translocation, submacular surgery and photocoagulation of the feeder vessel, the last one, guided by green indocyanine, can result in a better outcome, with the focal treatment of the choroidal neovascular membrane complex.

Auto-antibodies against antiangiogenic agents have been documented in the systemic circulation of patients undergoing chronic anti-VEGF therapy for exudative age related macular degeneration, preventing the action of these agents. Choroidal neovascular lesion composition might well change with time with more mature and therefore less VEGF sensitive vessels, so that prompt us to overcome such difficulty with new agents available [18].

The target layers of their retina and adjacent tissues, represented by the retinal pigment epithelium (RPE) and the Bruch membrane (BM) [19], respectively, can be complicated by choroidal neovascular membrane, formed after damage to the retinal pigment epithelium. A protein, the pigment epithelium derived factor (PEDF), could have an inhibitory effect on ocular neovascularization, as well as the VEGF, an angiogenic factor [20]. The balance between these antiangiogenic and angiogenic [21] factors may halt or ensue the origin of the choroidal neovascular membrane. Activation of VEGF induces vascular permeability, endothelial cell proliferation, and cell migration thus resulting in the formation of a network of new vessels [22]. Several clinical trials test the relative efficacy of different drugs and subtypes of the choroidal neovascular membrane [23-25].

Vascular endothelial growth factor (VEGF) has been implicated as a trigger process in the pathogenesis of ARMD-related choroidal neovascular membrane. Anti- VEGF agents for the treatment of choroidal neovascular membrane and are under active clinical investigation, and include anti-VEGF antibodies, gene therapy and protein kinase C inhibition and anti-VEGF aptamer. Many cases are shown to have resulted in a better outcome after intraocular injections with resolution of the membrane after most of times some intraocular injections (Figure 3).

We show a case of subretinal neovascular membrane treated with bevacizumab that fails with recurrent neovascular membrane, and a new treatment switching the medication was indicated.

### Case Report

We performed bevacizumab [2] intraocular injections in a patient with metamorphosis and CNV diagnosed on December, 2015. The patient was free of systemic symptoms, and had solely eye symptoms, manifested by metamorphosis in the left eye. The patient had visual acuity of counting fingers at 15 centimeters in the left eye, and 20/40 in the right eye. He had three injections of bevacizumab in December, 2015 followed by two more injections in January and February, 2016. He used to see a central blur out of the left eye and the right eye was asymptomatic. The patient was submitted to Oct - ocular computerized tomography and fluorescein angiography, before and after treatment. The patient was still counting fingers, but without the blur, and felt that his visual acuity got a lot better. The Oct pre-treatment showed a foveal minimum thickness of 313 microns and after the injections that increased to 340 microns, despite he noticed better visual acuity. The fluorescein angiography showed recurrent leakage from the membrane. Because of the risk of worsening both clinically and anatomically, and mainly because the lesion was still leaking and active, we decided to switch the drug to Ranibizumab, with the aim of halting the CNV formation quicker, to avoid worsening of the patient's visual acuity (Figure 4).

### Discussion

Antiangiogenic Compounds mostly used [26-28]:

#### Pegaptanib sodium

Pegaptanib [29] sodium is an aptamer against VEGF165, the isoform identified with pathological angiogenesis, the aptamer being an

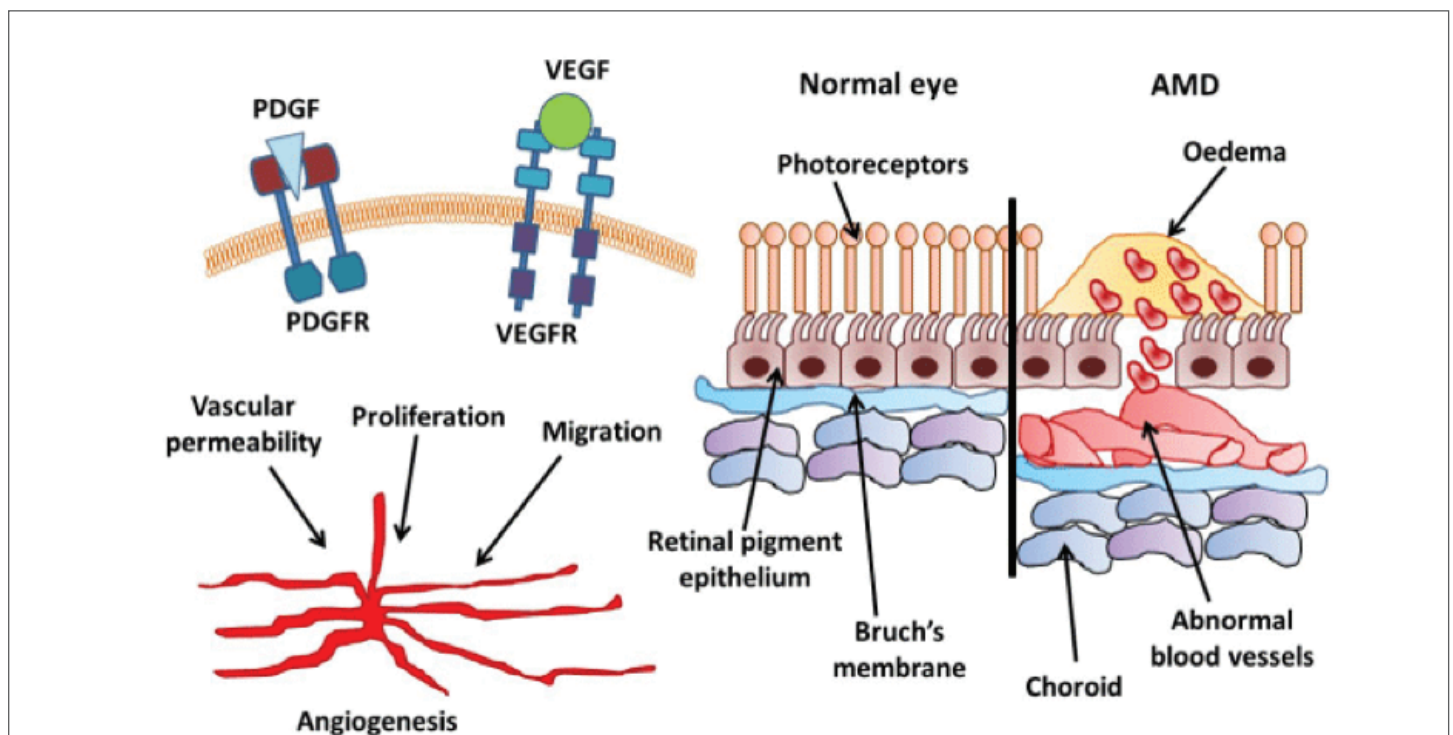


Figure 3: Mechanism of action of the VEGF and the structures involved.



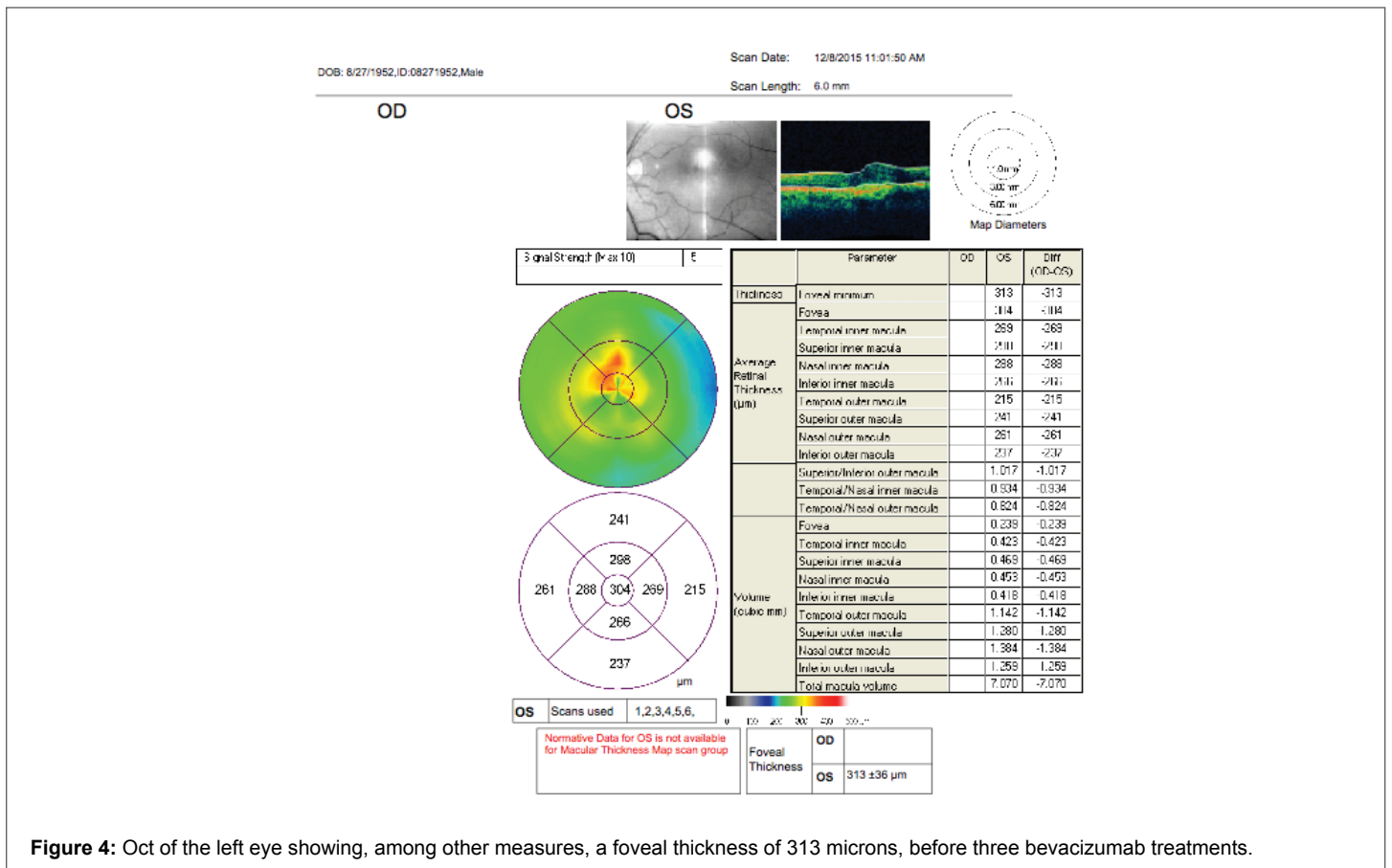


Figure 4: Oct of the left eye showing, among other measures, a foveal thickness of 313 microns, before three bevacizumab treatments.

oligonucleotide that acts like a high affinity antibody to VEGF, neutralizing it before it can contact its receptor.

### Ranibizumab

Ranibizumab is a recombinant monoclonal antibody Fab fragment that neutralizes all active forms of VEGF-The FDA approved the use of ranibizumab for the treatment of all angiographic subtypes of subfoveal neovascular ARMD.

### Bevacizumab [2]

Bevacizumab is a humanized, recombinant monoclonal immunoglobulin G (IgG) antibody that binds and inhibits all VEGF isoforms and is currently approved for systemic use in metastatic colorectal cancer and non-small cell lung cancer, and is used for CNV secondary to ARMD since 2005. Most of the reports of bevacizumab are uncontrolled, open-label case series that have suggested functional and anatomical efficacy, short-term safety, and lower costs (Figures 5-9).

### Aflibercept

The VIEW 1 and VIEW 2, two similarly designed double-masked, randomized multicenter clinical trials, demonstrated that intravitreal aflibercept dosed monthly or every 2 months after a loading dose of 3 monthly doses was non inferior to monthly ranibizumab.

The major concern for ocular complications following intravitreal anti-VEGF injections was for endophthalmitis, and non-infectious inflammation to the biologic anti-VEGF agents; other complications could be retinal tears, retinal detachment, tears of the retinal pigment epithelium; elevated intraocular pressure and cataracts.

### Important designed studies

The Comparison of Age-Related Macular Degeneration Treatment Trials (CATT) research group demonstrated that at 1 year, bevacizumab and ranibizumab had equivalent effects on visual acuity when administered according to the same schedule. Bevacizumab administered monthly was equivalent to ranibizumab administered monthly, with 8.0 and 8.5 letters gained, respectively.

To date, there are several studies and many more coming on the way, demonstrating the efficacy of intravitreal injections [30]:

The MARINA (Minimally classic/occult trial of the Anti- VEGF antibody Ranibizumab In the treatment of Neovascular Age-related Macular Degeneration) study demonstrated the intravitreal administration of ranibizumab for two years to prevent vision loss while improving the mean visual acuity with low rates of serious adverse events, in patients with minimally classic or occult choroidal neovascularization secondary to age-related macular degeneration.

The ANCHOR (anti-VEGF antibody for the treatment of predominantly classic choroidal neovascularization in age-related macular degeneration) study demonstrated that ranibizumab provided greater clinical benefit after two years than verteporfin PDT in patients with age related macular degeneration with new-onset, predominantly classic CNV.

The PRONTO (Prospective Optical coherence tomography imaging of patients with Neovascular age- related macular degeneration Treatment with intraocular ranibizumab) study used an Optical Coherence Tomography (OCT)-guided variable dosing regimen with intravitreal ranibizumab. During the first year, retreatment with ranibizumab was performed at each monthly visit if any criterion was fulfilled such



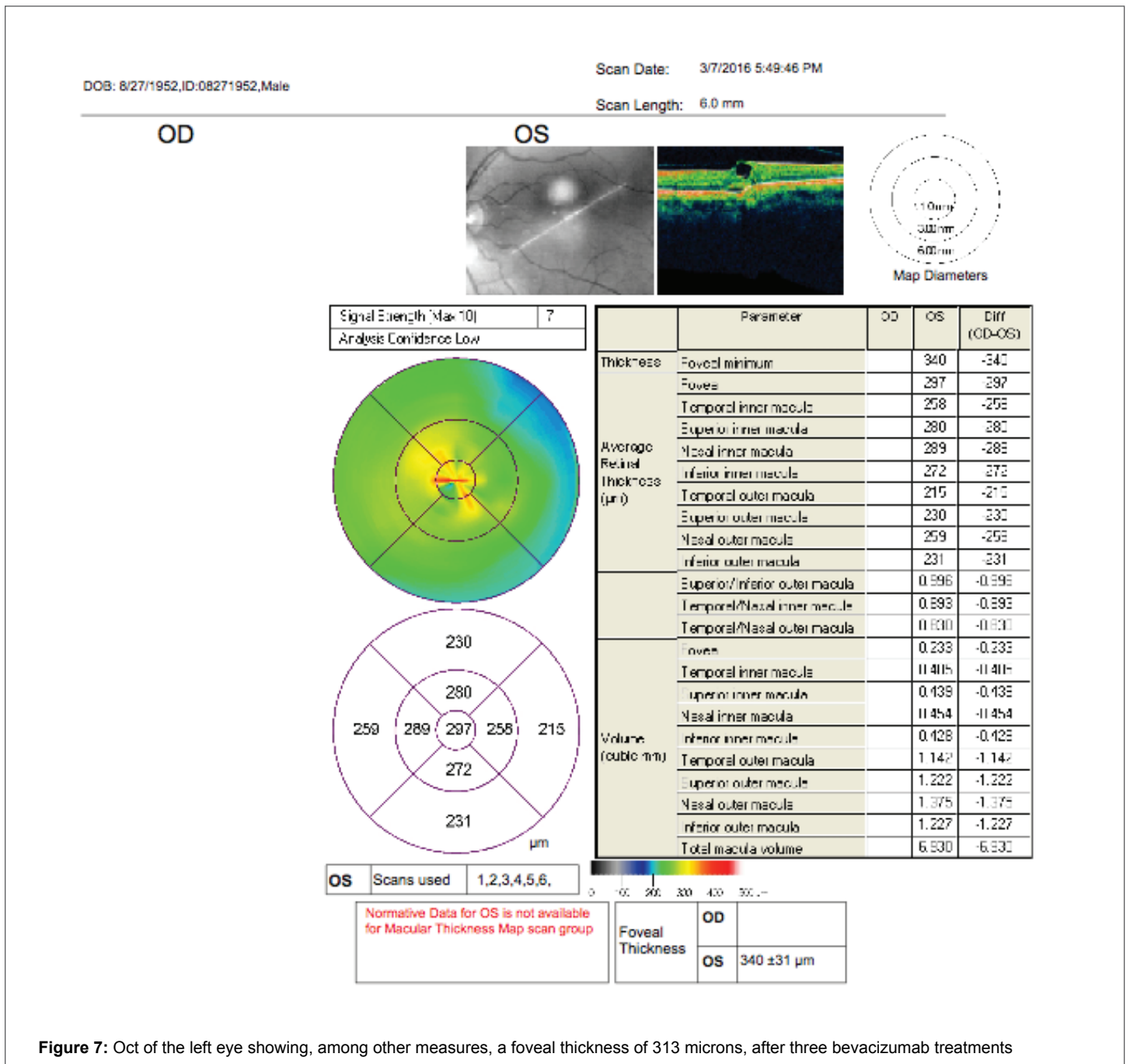


Figure 7: Oct of the left eye showing, among other measures, a foveal thickness of 313 microns, after three bevacizumab treatments

as an increase in OCT-CFT of at least 100 µm or a loss of 5 letters or more. During the second year, the retreatment criteria were amended to include retreatment if any qualitative increase in the amount of fluid was detected using OCT. This study demonstrated that at month 24, the mean VA improved by 11.1 letters and the CFT decreased by 212 µm. The VA improved by 15 letters or more in 43% of patients. These VA and OCT outcomes were achieved with an average of 9.9 injections over 24 months. As-needed (PRN), OCT-guided variable dosing with intravitreal ranibizumab resulted in VA outcomes comparable to the outcomes from the phase III clinical studies (monthly injection), but fewer intravitreal injections were required.

Pegaptanib appears to be an effective therapy for AMD. However, it does not lead to any improvement in the mean visual acuity.

The PIER (Phase IIIb, multicenter, randomized, double-masked, sham Injection-controlled study of the Efficacy and safety of Ranibizumab in subjects with subfoveal CNV with or without classic CNV secondary to age-related macular degeneration) study demonstrated that ranibizumab administered monthly for three months and then quarterly provided visual acuity benefits to patients with neovascular age related macular degeneration and was well tolerated. However, the observations from the MARINA and ANCHOR trials suggest that the PIER regimen of dosing every three months after three monthly doses provides less benefit in terms of visual acuity on average than continued monthly dosing. Monthly dosing may be necessary in some patients to achieve maximal treatment benefit from ranibizumab.

The CLEAR-IT (Clinical Evaluation of Anti-angiogenesis in the Retina Intravitreal Trial) study demonstrated that PRN dosing of VEGF Trap-Eye





after 12 weeks of monthly or quarterly fixed dosing maintained clinically and statistically significant improvements in vision and retinal thickness until at least week 52 in patients with neovascular AMD, with a low frequency of reinjection.

VEGF Trap-Eye was generally well tolerated, with a safety profile similar to that reported with other intravitreally administered anti-VEGF agents.

The LEVEL (Evaluation of Efficacy and Safety in Maintaining Visual Acuity with Sequential Treatment of Neovascular age related macular degeneration) study assessed the efficacy of pegaptanib as maintenance therapy in AMD patients who experienced a clinical improvement in disease following an induction phase. The induction maintenance using nonselective, followed by selective VEGF inhibitors should be considered for the treatment of AMD. Such an approach has special relevance for patients with cardiovascular co morbidities who require anti-VEGF drugs to manage their AMD.

The VISION (VEGF Inhibition Study In Ocular Neovascularization) study demonstrated that in the group given pegaptanib at 0.3 mg, 70% of patients lost fewer than 15 letters of visual acuity, as compared with 55% among the controls ( $P < 0.001$ ).

## Conclusion

The knowledge of the molecular physiopathology of the CNV [31] prompted the treatment of different subtypes of its neovascular form. Several studies, some mentioned above, contributed for backing up the use of these agents worldwide, even though some studies are still on the way and others are to come. But the future promises better results, and the combination of treatments with other drugs and also old treatments such as laser and PDT and others are still applied.

Pharmacology gives us a broad spectrum of options, and together with other related specialties, to date nanotechnology [25], gives us a better appreciation of the future. Some patients are prone to better results rather than other patients, and that may be corrected with different drugs switched after a good clinical evaluation, added with Ocs and FA, as well as other diagnosing tools, such as Oct angiography.

We need more studies to compare, especially with the new OctA tool, and that will help us in the follow up of these patients and management of new patients in order to avoid the growth of the CNV.

Despite recurrent rates could be high and switching medications may be necessary for the sake of the patient's vision, that decision should be taken without delay, to avoid growth of the choroidal neovascular membrane and its recurrence with devastating effects specially if located on the foveal area. We showed a case that needed retreatment with a new drug, switched to another medication able to perform better.

## References

- Ávila MP (1997) Subretinal neovascularization: contribution on angiographic and therapeutic study of patients with age-related macular degeneration [dissertation]. Belo Horizonte: Universidade Federal de Minas Gerais.
- Abrishami M, Zarei-Ghanavati S, Soroush D, Rouhbakhsh M, Jaafari MR, et al. (2009) Preparation, characterization, and in vivo evaluation of nanoliposomes-encapsulated bevacizumab (avastin) for intravitreal administration. *Retina* 29: 699-703.
- Li LX, Turner JE (1988) Transplantation of retinal pigment epithelial cells to immature and adult rat hosts: short- and long-term survival characteristics. *Exp Eye Res* 47: 771-785.
- Liu HA, Liu YL, Ma ZZ, Wang JC, Zhang Q (2011) A lipid nanoparticle system improves siRNA efficacy in RPE cells and a laser-induced murine CNV model. *Invest Ophthalmol Vis Sci* 52: 4789-4794.
- Eyetech Study Group (2002) Preclinical and phase 1A clinical evaluation of an anti-VEGF pegylated aptamer (EYE001) for the treatment of exudative age-related macular degeneration. *Retina* 22: 143-152.
- Marano RJ, Toth I, Wimmer N, Brankov M, Rakoczy PE (2005) Dendrimer delivery of an anti-VEGF oligonucleotide into the eye: a long-term study into inhibition of laser-induced CNV, distribution, uptake and toxicity. *Gene Ther* 12: 1544-1550.
- Marano RJ, Wimmer N, Kearns PS, Thomas BG, Toth I (2004) Inhibition of in vitro VEGF expression and choroidal neovascularization by synthetic dendrimer peptide mediated delivery of a sense oligonucleotide. *Exp Eye Res* 79: 525-535.
- D'Amico DJ, Goldberg MF, Hudson H, Jerdan JA, Krueger S, et al. (2003) Anecortave acetate as monotherapy for the treatment of subfoveal lesions in patients with exudative age-related macular degeneration (AMD): interim (month 6) analysis of clinical safety and efficacy. *Retina* 23: 14-23.
- (1997) Interferon alpha-2a is ineffective for patients with choroidal neovascularization secondary to age related macular degeneration. *Arch Ophthalmol* 115: 865-872.
- Schmidt-Erfurth U, Miller JW, Sickenberg M, Pournaras CJ, Laqua H, et al. (1997) Photodynamic therapy of subfoveal choroidal neovascularization in a phase I/II trial study: Preliminary results of multiple treatments. *Invest Ophthalmol Vis Sci* 38: s17.
- (1998) Laser treatment in eyes with large drusen. Short term effects seen in a pilot randomized trial. *Ophthalmology* 105: 11-23.
- Zhang K, Hopkins JJ, Heier JS, Birch DG, Halperin LS (2011) Ciliary neurotrophic factor delivered by encapsulated cell intraocular implants for treatment of geographic atrophy in age-related macular degeneration. *Proc Natl Acad Sci U S A* 108: 6241-6245.
- Machemer R, Sugita G, Tano Y (1979) Treatment of intraocular proliferations with intravitreal steroids. *Trans Am Ophthalmol Soc* 77: 171-180.
- Machemer R (1996) Five cases in which a depot steroid (hydrocortisone acetate and methylprednisolone acetate) was injected into the eye. *Retina* 16: 166-167.
- O'Reilly MS, Boehm T, Shing Y, Fukai N, Vasios G, et al. (1997) Endostatin: An endogenous inhibitor of angiogenesis and tumor growth. *Cell* 88: 277-285.
- Penfold PL, Wong JG, Gyory J, Billson FA (2001) Effects of triamcinolone acetonide on microglial morphology and quantitative expression of MHC-II in exudative age-related macular degeneration. *Clin Experiment Ophthalmol* 29: 188-92.
- Pepic I, Hafner A, Lovric J, Pirkic B, Filipovic-Grcic J (2010) A nonionic surfactant/chitosan micelle system in an innovative eye drop formulation, *J Pharm Sci* 99: 4317-4325.
- Sieving PA, Caruso RC, Tao W, Coleman HR, Thompson DJ, et al. (2006) Ciliary neurotrophic factor (CNTF) for human retinal degeneration: phase I trial of CNTF delivered by encapsulated cell intraocular implants. *Proc Natl Acad Sci U S A* 103: 3896-3901.
- van Zeeburg EJ, Maaijwee KJ, Missotten TO, Heimann H, van Meurs JC (2012) A free retinal pigment epithelium-choroid graft in patients with exudative age-related macular degeneration: results up to 7 years, *Am J Ophthalmol* 153: 120-127.
- Rosenfeld PJ, Schwartz SD, Blumenkranz MS, Miller JW, Haller JA, et al. (2005) Maximum tolerated dose of a humanized anti-vascular endothelial growth factor antibody fragment for treating neovascular age-related macular degeneration. *Ophthalmology* 112: 1048-1053.



21. Penfold PL, Madigan MC, Gillies MC, Provis JM (2001) Immunological and aetiological aspects of macular degeneration. *Prog Retin Eye Res* 20: 385-414.
22. Barouch FC, Miller JW (2004) Anti-vascular endothelial growth factor strategies for the treatment of choroidal neovascularization from age-related macular degeneration. *Int Ophthalmol Clin* 44: 23-32.
23. Folkman J, Ingber DE (1987) Angiostatic steroids. Method of discovery and mechanism of action. *Ann Surg* 206: 374-383.
24. Haritoglou C, Tadayoni R, May CA, Gass CA, Freyer W, et al. (2006) Short-term in vivo evaluation of novel vital dyes for intraocular surgery. *Retina* 26: 673-678.
25. Jousseaume AM, Kirchhof B (2003) [Angiogenesis in ophthalmology. A theme with a future]. *Ophthalmologie* 100: 281-283.
26. Michels S, Rosenfeld PJ (2005) [Treatment of neovascular age-related macular degeneration with Ranibizumab/ Lucentis]. *Klin Monatsbl Augenheilkd* 222: 480-484.
27. Tolentino MJ, Brucker AJ, Fosnot J, Ying GS, Wu IH, et al. (2004) Intravitreal injection of vascular endothelial growth factor small interfering RNA inhibits growth and leakage in a nonhuman primate, laser-induced model of choroidal neovascularization. *Retina* 24: 132-138.
28. van Wijngaarden P, Coster DJ, Williams KA (2005) Inhibitors of ocular neovascularization: promises and potential problems. *JAMA* 293: 1509-1513.
29. Moshfeghi AA, Puliafito CA (2005) Pegaptanib sodium for the treatment of neovascular age-related macular degeneration. *Expert Opin Investig Drugs* 14: 671-682.
30. (2012) Iluvien 190 Micrograms Intravitreal Implant in Applicator, Public Assessment Report, Medicines and Healthcare products Regulatory Agency.
31. Kato A, Kimura H, Okabe K, Okabe J, Kunou N, et al. (2005) Suppression of laser-induced choroidal neovascularization by posterior sub-tenon administration of triamcinolone acetonide. *Retina* 25: 503-509.