

## Cryptococcuria with Subsequent Cryptococcal Pneumonia in a Patient with Impaired Immunity

Ramon EA Jacobs\*

Department of Medicine, Division of General Internal Medicine & Clinical Innovation, New York University School of Medicine, USA

\*Corresponding author: Ramon E.A. Jacobs, Department of Medicine, Division of General Internal Medicine & Clinical Innovation, New York University School of Medicine, USA, Tel: +1-646-501-6937; Fax: +1-212-263-6022; E-mail: [Ramon.Jacobs@nyumc.org](mailto:Ramon.Jacobs@nyumc.org)

Received date: 08 Jan 2016; Accepted date: 18 Feb 2016; Published date: 23 Feb 2016.

Citation: Jacobs REA (2016) Cryptococcuria with Subsequent Cryptococcal Pneumonia in a Patient with Impaired Immunity. J Infect Pulm Dis 2(1): doi <http://dx.doi.org/10.16966/2470-3176.111>

Copyright: © 2016 Jacobs REA. This is an open-access article distributed under the terms of the Creative Commons Attribution License, which permits unrestricted use, distribution, and reproduction in any medium, provided the original author and source are credited.

### Abstract

*Cryptococcus neoformans* is encapsulated yeast that is often associated with serious pulmonary and Central Nervous System (CNS) infections in immune compromised hosts. Disseminated cryptococcosis occurs hematogenously. Cryptococcuria has been rarely described in patients without evidence of systemic cryptococcal infection. We describe a case of cryptococcuria in a patient on chronic corticosteroid therapy for sclerosing mesenteritis that was later found to have cryptococcal pneumonia, metastatic adenocarcinoma as well as combined T- and B-cell deficiency.

**Keywords:** Cryptococcuria; *Cryptococcus neoformans*; Immune deficiency; Immuno compromised host; Mycotic prostatitis; Urogenital tract

### Introduction

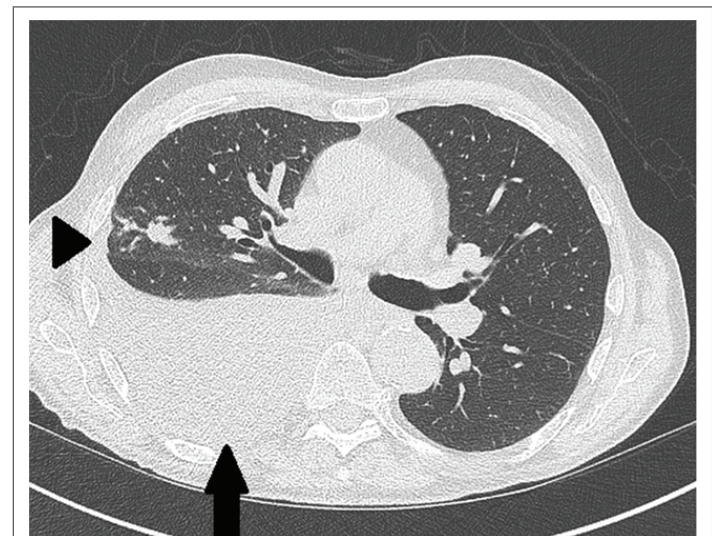
Cryptococcal infections have mostly been described in immune compromised hosts who have hematologic malignancies, AIDS, or who are post-transplant [1,2]. The most common site of infection is the respiratory tract however *Cryptococcus neoformans* has been isolated from various body sites [2]. It has rarely been isolated from the urine in patients without evidence of disseminated disease. Treatment options are the same as those with disseminated disease or evidence of meningoencephalitis however there is a paucity of studies investigating individual body sites outside of the lung and CNS. We present a case of cryptococcuria and subsequent cryptococcal pneumonia in an HIV-negative gentleman.

### Case Presentation

An 84-year-old HIV negative gentleman with a history of Parkinson's disease and sclerosing mesenteritis maintained on daily prednisone presents initially with less than one day of crampy, intermittent abdominal pain and vomiting. Other than the above diagnoses, he was otherwise well. He is a retired printing foreman with a 50-pack year smoking history, having quit several years prior. His primary mobility is via a motorized wheelchair and has a home health aide to help with his everyday needs.

On further history, his last bowel movement was four days prior to admission. His abdominal exam was benign. Laboratory analyses were remarkable for a mild leukocytosis, pyuria and hematuria. Plain abdominal radiography revealed stool throughout the colon. Abdominopelvic Computed Tomography (CT) imaging done eight days prior to presentation revealed findings consistent with his known sclerosing mesenteritis. He had no urinary symptoms. He was started on a bowel regimen with good effect and overnight had complete resolution of his abdominal discomfort and nausea. His leukocytosis resolved and he was discharged home the following day. Three days after discharge, his urine culture resulted with growth of 50,000 colony forming units (CFUs) of *Cryptococcus neoformans* sensitive to fluconazole and voriconazole. He continued to do well at home and was referred to see an immune compromised host infectious disease specialist. He had no previous urologic instrumentation, no fevers, pulmonary, or neurologic

symptoms other than his stable Parkinson's symptoms. Repeat urinalysis and urine culture were done without any growth of *Cryptococcus*. Serum cryptococcal antigen was negative and a fungal immune diffusion panel was negative for presence of *Histoplasma*, *Coccidioides*, *Blastomyces*, and *Aspergillus*. A (1,3)-Beta-D-glucan assay was indeterminate. The decision was made to follow closely off of antifungal therapy and follow serum cryptococcal antigen biweekly. He was evaluated by his primary urologist given his history of benign prostatic hypertrophy (BPH) and he had no signs of prostatitis. A CT scan of the chest revealed a moderate-sized right pleural effusion with compressive atelectasis, right upper lobe airway impaction, and a 4-5 millimeter subpleural nodule (Figure 1). He sustained a mechanical fall at home and presented to our emergency department where he was found to have mild hypoxia to 88% and tachycardia. He



**Figure 1:** Axial contrast enhanced computed tomography (CT) demonstrates a moderate-sized pleural effusion (black arrow) and bronchial mucoid impaction (black arrowhead)

was admitted and started empirically on intravenous fluconazole for suspected pulmonary cryptococcal disease. A thoracentesis was obtained with 1.8 liters of fluid removed. A lumbar puncture to assess cerebrospinal fluid for central nervous system (CNS) infection was performed. Fungal cultures and cryptococcal antigen assessment of the blood, pleural, and cerebrospinal fluid were negative. A repeat urine culture obtained revealed recurrent growth of *Cryptococcus*. He was started on empiric antibiotic therapy for presumed concomitant community-acquired pneumonia and an immunodeficiency workup was started. Immunoglobulin G was low at 561. Intracellular adenosine triphosphate (ATP) levels were low at 105 nanograms/milliliter (ng/mL) and CD4 count was also low at 67 with a CD4/CD8 ratio of 0.07. Cytopathology from the pleural exudate revealed adenocarcinoma likely metastatic from a lower gastrointestinal source. Positron emission tomography computed tomography (PET CT) revealed metastatic disease to the liver and enhancement of his known sclerosing mesenteritis. The patient was ultimately transitioned to hospice care and passed away peacefully in the hospital.

## Discussion

*C. neoformans* is an encapsulated yeast commonly associated with avian guano and can be found in soil polluted with the excrement [3]. It has worldwide distribution and can be found on both animals and humans. Cryptococcal infection is often associated with immune compromised hosts and has been described in patients with hematologic malignancies, diabetes, chronic rheumatologic disorders, organ transplantation, AIDS, and in those on chronic corticosteroid therapy [1,2,4]. Pulmonary cryptococcosis is the most common site of infection with the second most common site being the central nervous system (i.e., meningitis or encephalitis). Disseminated cryptococcosis occurs hematogenously [5]. Cryptococcuria has been described in the setting of disseminated cryptococcosis however it has rarely been described as a urinary tract isolate [6,7]. Wise and Shteynshlyuger [8] suggest that the prostate (as well as the kidneys) are potential reservoirs for *C. neoformans* in patients with AIDS after these organisms were found persisting in the prostate after disseminated cryptococcosis was adequately treated in patients with meningitis. Our patient had extensive source sampling from various sites including blood, pleural fluid, sputum cultures, and cerebrospinal fluid without evidence of disseminated disease. The Infectious Disease Society of America (IDSA) 2010 Clinical Practice Guidelines for the Management of Cryptococcal Disease note the following: "non meningeal, nonpulmonary cryptococcosis represents the consequence of dissemination even if the clinical syndrome is confined to a single anatomical site. Treatment regimens are similar to those for disseminated or CNS disease because there are no substantial specific studies for individual body sites except for the lung and CNS" [9]. Larsen et al. [10] note that cryptococcuria can persist even after conventional antifungal therapy, postulating that the prostate and/or kidney serve as major sanctuaries for urogenital tract infections or colonization. As noted by most major international infection-related clinical societies including the IDSA, American Thoracic Society, and the European Society of Clinical Microbiology and Infectious Diseases, impaired T cell function and immunosuppression are major risk factors for cryptococcal disease both of which were present in this particular patient [9]. It is vitally important that for patients with any of the above noted risk factors to sample both the lungs and cerebrospinal fluid to

assess for *cryptococcus*. Wise and Shteynshlyuger [8] noted that, in cases without dissemination, removal of the infected prostate gland in isolated mycotic prostatitis could be curative. Unfortunately, this patient was not well enough to undergo source sampling of the prostate prior to his demise. We postulate that he may have had disseminated cryptococcosis that seeded his genitourinary tract (specifically, the prostate) which preceded the pulmonary manifestations of this disease.

## Acknowledgments

None

## Conflict of Interest Statement

I have no disclosures or conflicts of interest to report.

## Study Sponsorship or Funding

None

## Consent

Written informed consent obtained from the next of kin, the patient's wife. Available upon request.

## References

1. Segal BH, Bow EJ, Menichetti F (2002) Fungal infections in non transplant patients with hematologic malignancies. *Infect Dis Clin North Am* 16: 935-964.
2. Perfect JR, Casadevall A (2002) Cryptococcosis. *Infect Dis Clin North Am* 16: 837-874.
3. Bennett JE, Kwon-Chung KJ, Howard DH (1977) Epidemiologic differences among serotypes of *Cryptococcus neoformans*. *Am J Epidemiol* 105: 582-586.
4. Hadley S, Karchmer AW (1995) Fungal infections in solid organ transplant recipients. *Infect Dis Clin North Am* 9: 1045-1074.
5. Chang YC, Stins MF, McCaffery MJ, Miller GF, Pare DR, et al. (2004) Cryptococcal yeast cells invade the central nervous system via transcellular penetration of the blood-brain barrier. *Infect Immun* 72: 4985-4995.
6. Severo CB, Pinto GL, Sotilli J, Garcia MR, Gazzoni AF, et al. (2011) Cryptococcuria as manifestation of disseminated cryptococcosis: Staib agar as a selective identification medium. *Mycoses* 54: e760-766.
7. Kiertiburanakul S, Sungkanuparph S, Buabut B, Prachartam R (2004) Cryptococcuria as a manifestation of disseminated cryptococcosis and isolated urinary tract infection. *Jpn J Infect Dis* 57: 203-205.
8. Wise GJ, Shteynshlyuger A (2006) How to diagnose and treat fungal infections in chronic prostatitis. *Curr Urol Rep* 7: 320-328.
9. Perfect JR, Dismukes WE, Dromer F, Goldman DL, Graybill JR, et al. (2010) Clinical practice guidelines for the management of cryptococcal disease: 2010 update by the infectious diseases society of america. *Clin Infect Dis* 50: 291-322.
10. Larsen RA, Bozzette S, McCutchan JA, Chiu J, Leal MA, et al. (1989) Persistent *Cryptococcus neoformans* infection of the prostate after successful treatment of meningitis. California Collaborative Treatment Group. *Ann Intern Med* 111: 125-128.