

Forgotten Intrauterine Contraceptive Device - An Unusual Cause Of Enterouterine Fistula

Abhay Y Desai¹, Dnyaneshwar S², and Vishwas D Pai^{1*}

¹Department of Surgery, B K L Walawalkar Hospital and research centre, Shree KshetraDervan, Maharashtra 415606 India

²Department of Obstetrics and Gynecology, B K L Walawalkar Hospital and research centre, Shree KshetraDervan, Maharashtra 415606, India

*Corresponding author: Dr. Vishwas. D. Pai, Department of Surgery, B K L Walawalkar Hospital and research centre, Shree KshetraDervan, Maharashtra 415606, India, Tel: +91-9167518002; E-mail: vishpai88@gmail.com

Received date: 27 Aug 2015; Accepted date: 01 Sep 2015; Published date: 06 Sep 2015.

Citation: Desai AY, Dnyaneshwar S, Pai VD (2015) Forgotten Intrauterine Contraceptive Device - An Unusual Cause Of Enterouterine Fistula. J Surg Open Access 1(1): doi <http://dx.doi.org/10.16966/2470-0991.102>

Copyright: © 2015 Desai AY, et al. This is an open-access article distributed under the terms of the Creative Commons Attribution License, which permits unrestricted use, distribution, and reproduction in any medium, provided the original author and source are credited.

Abstract

Intrauterine contraceptive device is one of the most popular forms of reversible contraception. Though considered as a safe method, uterine perforation and migration of IUCD into the peritoneal cavity or invasion into one of the adjacent viscera has been reported in English literature. We are presenting the case of an elderly lady presenting with persistent vaginal discharge which on investigations was found to be due to enterouterine fistula. As the lady had forgotten about the IUCD placed more than 20 year back, diagnosis could only be established only on examination of the resected specimen of entero uterine fistula. This case stresses the importance of creating awareness among the users of IUCD regarding the need for periodic examination to confirm the normal position of IUCD as well as its timely removal once family is complete.

Keywords: Forgotten intrauterine contraceptive device, Migrated intrauterine contraceptive device, IUCD, Enterouterine fistula, Utero enteric fistula

Introduction

Intra uterine contraceptive device (IUCD) is one of the most commonly used birth control methods with over one million individuals adopting this method of contraception worldwide [1]. The popularity of the device is not only because of its effectiveness but also because of lower cost, reversibility, one time applicability and excellent safety profile [2]. However, rarely an IUCD can migrate beyond the uterus into adjacent organs of the pelvis or the peritoneal cavity. We are presenting a case of forgotten IUCD which had migrated into ileum resulting in an entero uterine fistula.

Case Report

A 59 yr old post menopausal lady presented with persistent vaginal discharge and vague lower abdominal pain of 2 years duration. There was no history of fever or bowel or bladder disturbances. She had received antibiotic therapy in the past on several occasions though without much relief. Per vaginal examination revealed tenderness over the uterus, otherwise no pathology responsible for the white discharge. She was mother of 5 children and her last delivery was 25 year back. As Ultrasound examination of the pelvis was inconclusive, contrast enhanced computed tomography (CECT) of the pelvis was performed. It revealed a loop of small intestine adherent to the fundus of the uterus with leakage of oral contrast into the uterus suggestive of enterouterine fistula (Figure 1a). On exploratory laparotomy, a loop of ileum was densely adherent to the uterine fundus. Hysterectomy with resection of the involved loop of small bowel followed by end to end hand sewn anastomosis of the bowel was performed. Examination of the resected specimen revealed IUCD as the cause of the fistula (Figure 1b). Post operative course was uneventful and patient remembered retrospectively that IUCD was placed after her last delivery and was never taken out.

Discussion

Worldwide IUCD is one of the most popular forms of reversible

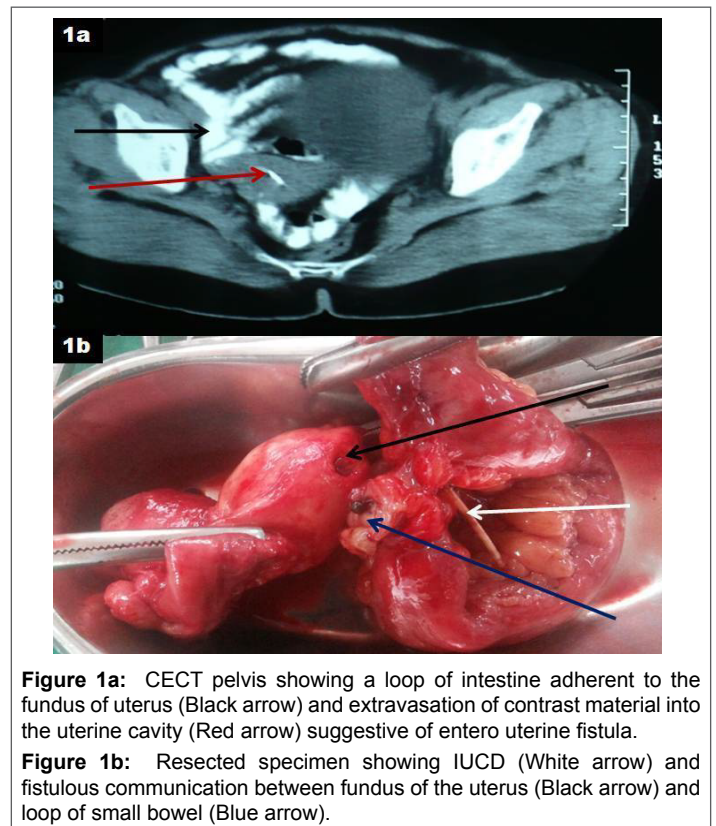


Figure 1a: CECT pelvis showing a loop of intestine adherent to the fundus of uterus (Black arrow) and extravasation of contrast material into the uterine cavity (Red arrow) suggestive of entero uterine fistula.

Figure 1b: Resected specimen showing IUCD (White arrow) and fistulous communication between fundus of the uterus (Black arrow) and loop of small bowel (Blue arrow).

contraception. It acts by inhibiting the fertilized ovum to get implanted in the endometrial cavity. Though considered as safe, possible complications associated with its use include painful abdominal cramps, menstrual abnormalities, spontaneous expulsion, higher incidence of ectopic pregnancy, uterine perforation and pelvic inflammatory disease [3].

Uterine perforation is a rare but potentially serious complication of IUCD use with reported incidence of 0.12 to 0.68 per 1000 insertions [4]. Uterine perforation secondary to IUCD placement may be early that is during or immediately after the placement or delayed that is after several years of placement. Perforation occurs most commonly through the posterior wall of the uterus. Perforations may be partial, with some portion of the device remaining within the endometrial cavity, or complete, with the device remaining extra uterine [5]. In upto 15% cases, migrated IUD may invade adjacent visceral organs, with the intestine most often affected [6]. The migrated IUD can cause perforation or obstruction of the intestine, mesenteric penetration, rectal strictures, and utero vesical fistula [7].

Enterouterine fistula (EUF), an abnormal fistulous communication between uterus and the bowel is an entity rarely encountered in the routine surgical practice. Etiological factors implicated are traumatic or spontaneous rupture of uterus, malignancy arising from uterus or rupture of pelvis abscess into both uterus as well as small bowel [8]. Unusual causes such as that resulting from angio embolization of uterine artery has occasionally been reported [9]. Migrated IUCD causing EUF has rarely been reported in English literature.

The clinical presentation in cases of migrated IUCD is highly variable. Although a small number of patients with present with acute symptoms, most will be relatively asymptomatic. The IUCD strings are used to monitor and remove the device. The presence of the string in the vagina usually means that the IUCD is *in situ*. A missing string is regarded as the first sign of perforation in approximately 80% of the cases [10]. The present patient was not aware of the fact that a missing string is abnormal and hence never reported it. Over a period of time she forgot that an IUCD was *in situ*.

Management of migrated IUCD depends on the mode of presentation. Current consensus is to remove a migrated IUCD even if it is asymptomatic. In elective cases, laparoscopic retrieval of the migrated IUCD is preferable with conversion to open surgery required in upto 22% patients [11]. In cases when the IUCD has invaded into the adjacent organs or in presence of acute symptoms, laparotomy may be required. In case of the present patient, enterouterine fistula of unknown etiology was the tentative diagnosis and hence laparoscopy was not attempted.

Conclusion

Forgotten IUCD should be a differential diagnosis in any patient with enterouterine fistula. Awareness needs to be created in the users of IUCD regarding the need for periodic examination to confirm the normal position of IUCD as well as its timely removal once family is completed.

References

1. Sivin I, Batár I (2010) State-of-the-art of non-hormonal methods of contraception: III. Intrauterine devices. *Eur J Contracept Reprod Health Care* 15: 96–112.
2. Bozkurt M, Yumru AE, Coskun EI, Ondes B (2011) Laparoscopic management of a translocated intrauterine device embedded in the gastric serosa. *J Pak Med Assoc.* 61: 1020–2.
3. Gardyszewska A, Niewiadomska-Kowalczyk M, Szymańska B, Roszkowski P, Czajkowski K (2009) [Extrauterinemislocated IUD]. *Ginekol Pol* 80: 942–5.
4. Broso PR, Buffetti G (1994) [The IUD and uterine perforation]. *Minerva Ginecol.* 46: 505–9.
5. Heinberg EM, McCoy TW, Pasic R (2008) The perforated intrauterine device: endoscopic retrieval. *JSLs.* 12: 97–100.
6. Zakin D, Stern WZ, Rosenblatt R (1981) Complete and partial uterine perforation and embedding following insertion of intrauterine devices. I. Classification, complications, mechanism, incidence, and missing string. *Obstet Gynecol Surv.* 36: 335–53.
7. Chen CP, Hsu TC, Wang W (1998) Ileal penetration by a Multiload-Cu 375 intrauterine contraceptive device. A case report with review of the literature. *Contraception.* 58: 295–304.
8. Peters IB, Williams CA, Dahniya MH (1983) Uteroenteric fistula due to ruptured ectopic pregnancy. *Br J Radiol.* 56: 881–3.
9. Pandey B, Sunanda GV, Crowe P (2012) Enterouterine fistula: a rare and unusual complication of uterine artery embolisation. *J ObstetGynaecol.* 32: 32–3.
10. Ozgun MT, Batukan C, Serin IS, Ozcelik B, Basbug M, et al. (2007) Surgical management of intra-abdominal mislocated intrauterine devices. *Contraception.* 75: 96–100.
11. Mosley FR, Shahi N, Kurer MA (2012) Elective surgical removal of migrated intrauterine contraceptive devices from within the peritoneal cavity: a comparison between open and laparoscopic removal. *JSLs.* 16: 236–41.