

# Minimal Invasive Surgical Release of the Median Nerve at the Wrist: A Study about 36 patients

James YE<sup>1,2\*</sup>, Walla A<sup>1</sup>, Abalo A<sup>1</sup>, Akpoto MY<sup>1</sup>, Bakriga B<sup>1</sup> and Dossim MA<sup>1</sup>

<sup>1</sup>Department of Orthopedic and reconstructive surgery, Sylvanus Olympio Hospital, BP: 57 Lomé, TOGO

<sup>2</sup>Anatomy Laboratory, Health Sciences Faculty of Lomé, BP: 1515 Lomé, TOGO

\*Corresponding author: James Yaovi Edem, Department of Orthopedic and reconstructive surgery, Sylvanus Olympio Hospital, BP: 57 Lomé, TOGO, Tel : 00228 90 04 28 73; E-mail: [nanoj@yahoo.fr](mailto:nanoj@yahoo.fr)

Received date: 20 Nov 2015; Accepted date: 04 Mar 2016; Published date: 09 Mar 2016.

Citation: James YE, Walla A, Abalo A, Akpoto MY, Bakriga B, et al. (2016) Minimal Invasive Surgical Release of the Median Nerve at the Wrist: A Study about 36 patients. J Surg Open Access 2(2): doi <http://dx.doi.org/10.16966/2470-0991.117>

Copyright: © 2016 James YE, et al. This is an open-access article distributed under the terms of the Creative Commons Attribution License, which permits unrestricted use, distribution, and reproduction in any medium, provided the original author and source are credited.

## Abstract

Surgical treatment of carpal tunnel syndrome (CTS) has evolved those recent years. Endoscopic and minimal invasive techniques have grown considerably, to limit the incidence of cutaneous complications associated with conventional open surgery, reducing hospitalization time and allow rapid functional recovery of the hand.

**Purpose:** The purpose of this work is to analyze in our practical conditions, the results of surgical treatment of CTS with a minimal invasive technique using a transverse palmar incision made in the wrist crease.

**Patients and methods:** This was a prospective study of 36 patients who underwent surgical treatment by minimal invasive CTS technique. The series consisted of 24 women and 12 men, whose average age was 43 years. 47.22% of patients were hand workers. All patients had a CTS confirmed by electromyography. The intervention took place under loco regional anesthesia with axillary block. All patients have been operated by the same surgeon. For each patient, the same surgical procedure has been applied. After a transverse incision of about 1cm in the crease of the wrist, it was directed anterograde section of flexor retinaculum (RDF) using a special curved bistoury. A simple bandage was made and no immobilization has been made.

**Results:** In the immediate post-operative follow up, local hematoma was found in 04 patients. Locally, the evolution of the scar was favorable in all patients. At 30<sup>th</sup> day, 34 patients had more functional impairment, or pain in the scar, and had recovered more than 50% grip strength. They could use all their hand for daily activities. At three months, 83% of patients had the same grip strength on both sides.

**Discussion and conclusion:** the interest of this minimal invasive technique is based on the quality of short term postoperative follow up that are more comfortable for the patient, allowing faster functional recovery of the hand, without being more iatrogenic.

**Keywords:** Carpal tunnel syndrome; Minimal invasive surgery

## Introduction

Carpal Tunnel Syndrome (CTS) Surgery, which consists of the release of the median nerve at the wrist by the section of the retinaculum flexor, is an established treatment in case of failure of any conservative treatment (medical treatment, functional rehabilitation, corticoid infiltration) and in severe cases [1]. This surgical treatment in developing countries is typically made in open [2,3]. For this open surgery, the main complication that can occur is painful phenomena near the scar, oftenly disabling for the patient. It also exposes to the risk of occurrence of scarring sheathing the nerve that can cause a recurrence of carpal tunnel syndrome [1].

For about ten years, endoscopic techniques, especially the technique of Chow [4,5] and Agee [6,7], allow remote opening of the nerve, thus avoiding the scarring. Failing to realize this endoscopic surgery, we have set up a mini-open technique, with a more limited exposure to sever under visual control throughout the retinaculum. This minimal invasive technique allows to improve the postoperative and a quick return to work.

The aim of this work is to present our minimal invasive technology and to evaluate its clinical and functional results.

## Materials and Methods

Between January the 1<sup>st</sup> of 2010 and December 31<sup>st</sup> of 2012, 36 patients with Carpal Tunnel Syndrome were treated with our technique. This was

a prospective study that examined 36 patients (24 women and 12 men) with an average age of 39 years. 17 patients in the series had a manual activity. The dominant hand of 27 patients was affected and 12 patients were operated on both sides.

Acroparesthesia were found in all the series and in 25 patients the Tinel's sign was positive. All patients underwent electromyography, which confirmed the diagnosis of nerve damage. Surgical treatment was proposed after confirmation of the diagnosis by the EMG (electromyography) with failure of medical treatment.

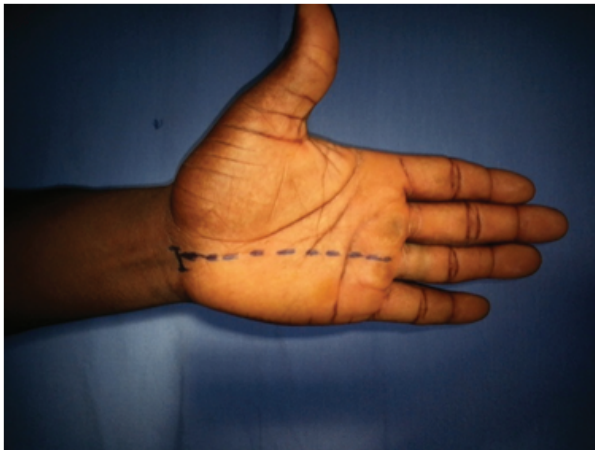All patients read and signed an informed consent document before the procedure.

This was a series mono operator and the same procedure was performed in all patients.

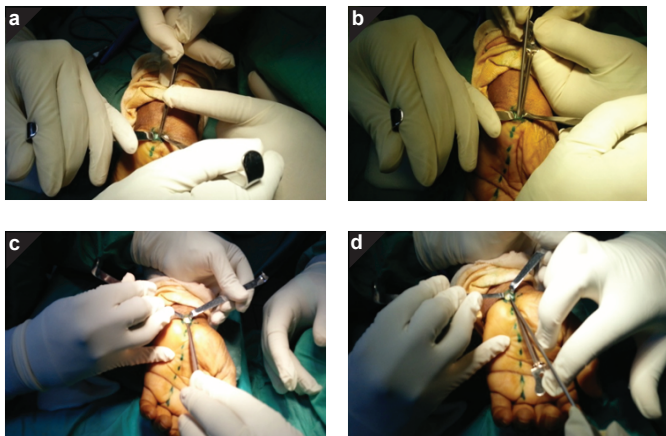
The line of the incision and the direction of the canal release were still drawn before the intervention started (Figure 1).

## Surgical technique

Under the Esmarch Tourniquet placed at the root of the member, we proceed initially to a small transverse incision in the medial tendon of the long volar (Figure 2). The sub-cutaneous plane was dissected with sharp curve scissors of Stevens and sub-cutaneous hemostasis was carried



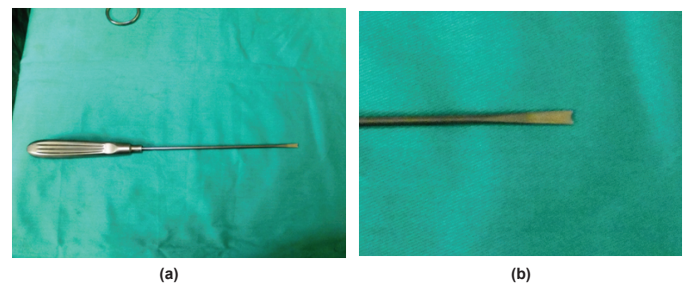
**Figure 1:** Line of the palmar incision and direction of the opening of Flexors Retinaculum (into dotted)



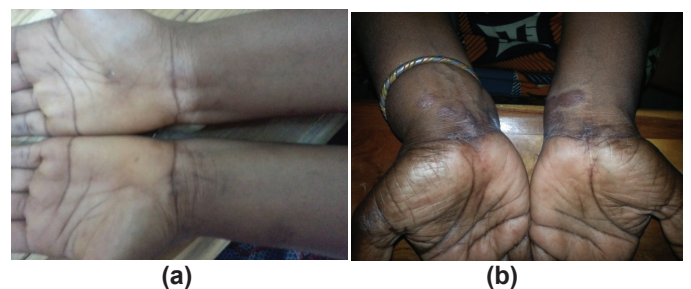**Figure 2:** Section of the Flexors Retinaculum and Carpi Volare Introduction of the canula probe under the Flexors Retinaculum. b) Section of the Flexors Retinaculum of proximal and distal. c) Introduction of the probe canula proximal under the volar ligament of the carpus. d) Section of the carpi volare of distal in proximal

out during this dissection. The aponeurotic plan of the big palmar was always approached with the scissors of Stevens and the operative field for the surgeon was exposed by two small retractors that aid positions in both corners of the incision. After dissection of the fibers of the palmar aponeurosis, and of the anterior surface of the flexor, retinaculum was exposed and easily proceeds to a careful dissection above the flexor retinaculum to expose the anterior aspect of the distal portion. A small transverse incision was made approximately 4 mm in front of the flexor retinaculum. A cannulated probe was then inserted in the endo ductal and proximal to distal, with a specific curved bistoury (Figure 3), we realize a section of the flexor retinaculum opposite the fourth radius. The cannulated probe was then withdrawn and reintroduced in the carpi volare that we cut off by the same procedure. Using a curved Metsenbaum scissors, we proceed to the verification of the complete section of the flexor retinaculum. Incomplete section resulted in the feeling in the tip of the scissors a form of stretched guitar string.

The tourniquet was then released and after closing the sub-cutaneous plane with absorbable 4/0 thread, then the surgical wound was closed with a subcuticular suture. A simple bandage was done and renewed after 72 hours. The patient left the hospital the same day and was allowed to use his hand immediately.



**Figure 3:** (a and b) Image of the bistoury in bevel used to cut off the Flexors Retinaculum



**Figure 4:** (a and b) Favorable operating scars on two patients one month of recoil before.

All parameters related to the intervention, including intraoperative incidents and immediate, sides and late postoperative complications were noted and studied.

After eight months of average recoil, all patients were re-examined. Three parameters were evaluated: the force of striking with the palm, holding and function of the hand. The strength and the grasp were studied compared to the healthy side. The function of the hand was evaluated according to DASH's score.

## Results

The average duration of the intervention from the incision to closure averaged 18 mn with extremes between 10 to 35 minutes. The ALR has failed in 10 patients and 10 patients experienced pain under tourniquet.

In all patients, we were able to cut the Flexor Retinaculum by our technique. In 16.66% of cases, the proximal distal section of the Flexor Retinaculum was slightly working. In 19.44% cases the section was incomplete at the first time. It persisted a residue from retinaculum which was found after palpation of Medsembum scissors. No haemorrhagic incidents have even been noted.

The immediate surgical follow up was uneventful in 77.77% cases. Intense postoperative pain, justifying treatment with stage II analgesics, were found in 11.11% cases. Four patients (11.11%) had a postoperative hematoma that motivated the establishment of a compression bandage. At the end, no sensomotor deficit, which may reflect iatrogenic nerve injury, were detected. In all cases, the occurrence of these complications did extend the hospital stay of 24 hours.

At one month, all wounds were healed (Figure 4). No cases of infection were noted. Two cases (5.55%) of hypertrophic scar justified injecting dermocorticoid. Functionally, in 100% cases, acroparesthesia disappeared the day after surgery. 27.7% (10 cases) had residual pain for a week. 21 patients or 58.33% of cases have started to use their hands normally after a week.

After eight months, all patients were reviewed. The strength averaged

3/5 throughout the group. The DASH score of the whole group was 46.33% with extreme scores of 78 and 30.

## Discussions

The Carpal Tunnel Syndrome is a rare and little-known disease in our communities, in contrast to Western countries. No study has estimated the incidence of this disease in a melanoderma person and especially to clarify the results of surgical treatment in sub-Saharan Africa. The only studies found in literature are clinical cases where the disease was associated with other pre-existing conditions [2,3]. All of our patients had a definite clinical diagnosis, oriented on the one hand by the presence of acroparesthesia in the territory of the median nerve and confirmed by the positivity of tinell test. However, we confirmed the nerve conduction attack on the basis of results of the electromyogram that was realized in all patients of the group. This electrical examination is indeed recommended by virtually all authors [1] who question the specificity of this clinical grid and recommend the implementation of electrical test to confirm nerve conduction abnormalities. Surgical treatment of this condition, which is established in severe forms rebels any other therapeutic method, has evolved in recent years. The release of the nerve by the flexor retinaculum section after a palmar longitudinal incision was replaced with endoscopic techniques [4-7] and minimal invasive [8-10]. The development of minima invasive and endoscopic techniques aimed to reduce the length of hospital stay and their common point is the nerve release by one or two shorter incisions. These recent techniques have the advantage of a faster recovery in activity, due to better recovery of strength and reduced scar pain. Endoscopic techniques [4-7] give extraordinary results compared to the scarring, complications found in conventional open technique.

However these endoscopic techniques are much more expensive due to the cost of endoscopic equipment. Therefore minimal invasive techniques are an alternative to endoscopic techniques in our country where technical platforms are very limited. Technically, the Retinaculum Flexor (RDF) section remains the main difficulty in minimal invasive techniques. We used a curved bistoury mounted on an elongated handle and that was easy to be part of our incision. The curvature of the knife facilitated the section of the Retinaculum Flexor (RDF). The use of knifelight, bistoury used by Yeo et al. [11] in their minimal invasive method, it was observed a faster resumption of activities in all patients. This saves time in the resumption of activities was also found in Aslani et al. [9] who compared a group of 105 patients, the results of the conventional method, endoscopic techniques and minimal invasive method. The occurrence of such per operative incidents mainly depends on the surgeon's dexterity and his habit against these minimal invasive techniques. Among the first patients in our group, the section of the Retinaculum Flexor (RDF) was a bit successful. These were the first cases operated. So there is a learning curve in the realization of these minimal invasive techniques. Per operative incidents by these minimal invasive techniques are rare, unlike endoscopic techniques. According to some authors, the occurrence of such incidents in per operative endoscopic techniques is linked to the caliber of the endoscope unlike bistoury much thinner used in most open min techniques [4-7,12]. These iatrogenic lesions were not found in our study. Apart from the absence of peroperative incidents and major postoperative complications, revision of all patients allowed us to note positive developments in a majority of cases in our group. These minimal invasive techniques according to all authors [8-10,13-17], also have the advantage of being less expensive, reduce very significantly the duration of hospital stay, to allow recovery Quick daily and professional activities. They can be a good alternative for the treatment of this disease in our communities where orthopedic endoscopy is not yet developed.

## Conclusion

Surgical release of the median nerve in the carpal tunnel by our

minimal invasive technique appears to be a reliable method to the results of our series. Its interest lies in the quality of short-term postoperative that is more comfortable for the patient. It allows the faster functional recovery of the hand without giving further iatrogenic injury than conventional techniques. However, the success of this technique which must be performed by specialized expert hands inevitably imposes a learning curve in which the different times of the intervention must be mastered by the surgeon. Moreover, although it is less expensive than endoscopic techniques, the provision of specific instruments is crucial.

## References

1. Moreel P, Dumontier C (2007) Encyclopédie Médico-Chirurgicale – Techniques chirurgicales – Orthopédie-Traumatologie. Elsevier Masson SAS, Paris 44-362.
2. Goga IE (1990) Carpal tunnel syndrome in black South Africans. *J Hand Surg Br* 15: 96-99.
3. Munie T (2005) Surgical management of carpal tunnel syndrome in neurosurgery practice in Ethiopia and review of literature. *Ethiop Med J* 43: 79-83.
4. Chow JC (1996) Endoscopic carpal tunnel release. *Clin Sports Med* 15: 769-784.
5. Chow JC, Hantes ME (2002) Endoscopic carpal tunnel release: thirteen years' experience with the technical Chow. *J Hand Surg Am* 27: 1011-1018.
6. Agee JM, Peimer CA, Pyrek JD, Walsh WE (1995) Endoscopic carpal tunnel release: a prospective study of complications and surgical experience. *J Hand Surg Am* 20: 165-171.
7. Agee JM, McCarroll HR Jr, Tortosa RD, Berry DA, Szabo RM, et al. (1992) Endoscopic carpal tunnel release of the: a randomized prospective multicenter study. *J Hand Surg Am* 17: 987-995.
8. Jin GQ, Yang J, Li CY, Ming XF, Zhao XF, et al. (2012) Carpal tunnel syndrome Treatment of with mini-incision decompression. *Zhongguo Gu Shang* 25: 58-61.
9. Aslani HR, Alizadeh K, Eajazi A, Karimi A, Karimi MH, et al. (2012) Comparison of carpal tunnel release with three different techniques. *Clin Neurol Neurosurg* 114: 965-968.
10. Isik HS, Bostanci U (2011) Experience of Carpal Tunnel Syndrome That united operated using a limited skin incision. *Turk Neurosurg* 21: 177-180.
11. Yeo KQ, Yeo EM (2007) Comparison of the results of open carpal tunnel release and carpal tunnel release Knifelight. *Singapore Med J* 48: 1131-1135.
12. Kernt B, Neu J (2011) Injury to the median nerve minimally invasive after-decompression: surgical entre les discrepancy report and actual running of Surgery. *Unfallchirurg* 114: 538-540.
13. Sanati KA, Mansouri M, Macdonald D, Ghafghazi S, Macdonald E, et al. (2011) Surgical Technical and return to Work Following carpal tunnel release: a systematic review and meta-analysis. *J Occup Rehabil* 21: 474-481.
14. Cellocco P, Rossi C, El Boustany S, Di Tanna GL, Costanzo G (2009) Minimally invasive carpal tunnel release. *Orthop Clin North Am* 40: 441-448.
15. Nazzi V, Franzini A, Messina G, Broggi G (2008) Carpal tunnel syndrome: minimally invasive matching technical surgical. *Technical note. J Neurosurg* 108: 1033-1036.
16. Elsharif M, Papanna M, Helm R (2014) Long-term follow up outcome results of Knifelight carpal tunnel release and conventional open release following a departmental randomized controlled trial. A prospective study. *Pol Orthop Traumatol* 79: 67-70.
17. Fernandes CH, Nakachima LR, Hirakawa CK, Gomes Dos Santos JB, Faloppa F (2014) Carpal tunnel release using the Paine retinaculotomy inserted through a palmar incision. *Hand (NY)* 9: 48-51.