

# Blunt Diaphragmatic Rupture Involving the Esophageal Hiatus: Case Report of an Extremely Rare Situation

Mohamed Hamid\*, Youssef Chaoui, Mohamed Mountasser, Anas Majbar, Farid Sabbah, Mohammed Raiss, Abdelmalek Hrra, Mouna Alaoui and Mohammed Ahallat

Department of Surgery, Hôpital Ibn-Sina, Rabat, Faculté de Médecine et de Pharmacie Rabat, Mohammed V University Souissi, Rabat, Morocco

\*Corresponding author: Mohamed Hamid, Department of Surgery, Hôpital Ibn-Sina, Rabat, Faculté de Médecine et de Pharmacie Rabat, Mohammed V University Souissi, Rabat, Morocco, E-mail: [mohamed.hamid@um5s.net.ma](mailto:mohamed.hamid@um5s.net.ma)

Received date: 26 Apr 2017; Accepted date: 18 Aug 2017; Published date: 25 Aug 2017.

Citation: Hamid M, Chaoui Y, Mountasser M, Majbar A, Sabbah F, et al. (2017) Blunt Diaphragmatic Rupture Involving the Esophageal Hiatus: Case Report of an Extremely Rare Situation. J Surg Open Access 3(4): doi <http://dx.doi.org/10.16966/2470-0991.156>

Copyright: © 2017 Hamid M, et al. This is an open-access article distributed under the terms of the Creative Commons Attribution License, which permits unrestricted use, distribution, and reproduction in any medium, provided the original author and source are credited.

## Abstract

Acute traumatic diaphragmatic rupture in blunt trauma is a rare entity. The crural extension of a hemidiaphragmatic tear been reported only once. The aim of this study is to report a case of a blunt diaphragmatic rupture involving the esophageal hiatus.

**Case:** A 27-year-old male, a truck driver, was admitted to the emergency department following a violent road traffic accident causing a blunt thoraco-abdomino-pelvic trauma. After stabilization of the patient, a radiological evaluation showed a complex fracture of the pelvis and left clavicle, and a left lung contusion. Seventy-two hours later, the patient presented an uncontrollable vomiting and respiratory distress. A new CT-scan revealed a left diaphragmatic rupture. An emergency surgery was performed. After a midline laparotomy, exploration revealed a large central tear of the left hemidiaphragm. The stomach, transverse colon and greater omentum had herniated through the defect into the left hemithorax. The diaphragmatic defect was repaired.

During a final exploration of the abdomen, the left triangular and falciform ligaments were divided by electrocautery while caudal traction was placed on the liver. A second rupture involving the esophageal hiatus was identified. It was repaired and the esophageal hiatus reconstructed using interrupted silk sutures.

Postoperatively, the patient was managed in the intensive care unit for 4 days. Subsequent recovery was uncomplicated.

**Keywords:** Blunt chest trauma; Diaphragm rupture; Esophageal hiatus

## Introduction

Acute traumatic diaphragmatic rupture in blunt trauma is a rare traumatic injury and often reflects the severity of the trauma. This lesion is a diagnostic and therapeutic challenge and has special features in the management of thoracic and abdominal injuries often associated. We report a case of a left diaphragmatic rupture involving the esophageal hiatus.

## Case

A 27-year-old male, a truck driver, without significant pathological history, was admitted to the emergency department following a violent road traffic accident causing a blunt thoraco-abdomino-pelvic trauma. After stabilization of the patient, a radiological evaluation (X-ray and body scan) showed a complex fracture of the pelvis and left clavicle, treated conservatively, and a left lung contusion. Seventy-two hours later, the patient presented an uncontrollable vomiting and respiratory distress. Subsequently, a new CT-scan revealed a diffuse opacity of the left lung with the presence of fluid levels (Figure 1), confirming the diagnosis of left diaphragmatic rupture. Therefore, the patient underwent an urgent surgery because of the uncontrollable respiratory distress.

After a midline laparotomy, exploration revealed a large central tear involving the left hemidiaphragm (Figure 2). The stomach, transverse colon and greater omentum had herniated through the defect into the left hemithorax. There were no other intra-abdominal or retroperitoneal

injuries. The hernial contents were reintroduced into the abdomen, and the diaphragmatic defect was repaired using non-absorbable silk interrupted sutures.

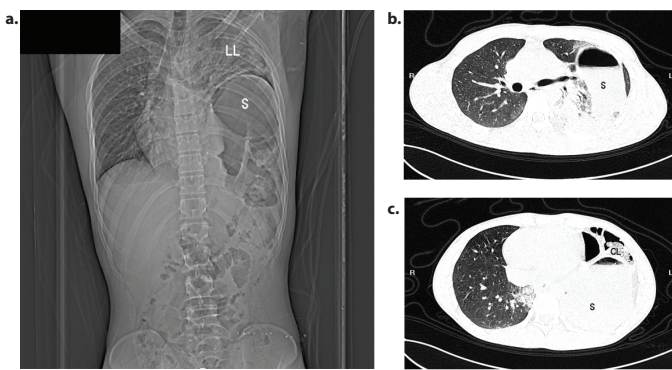
During a final exploration of the abdomen, the left triangular and falciform ligaments were divided by electrocautery while caudal traction was placed on the liver. A second rupture involving the esophageal hiatus were identified (Figure. 3). It was repaired and the esophageal hiatus reconstructed using interrupted silk sutures. An intercostal catheter was left in the left hemithorax.

Postoperatively, the patient was managed in the intensive care unit for 4 days. Subsequent recovery was uncomplicated.

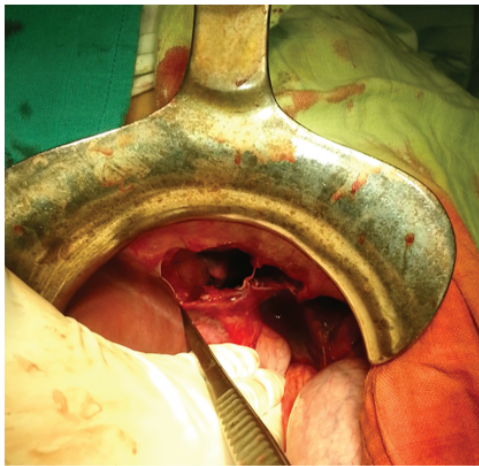
## Discussion

Acute traumatic diaphragmatic rupture in blunt trauma is a rare entity. It occurs in less than 8 % of blunt abdominal trauma patients [1-4]. It is usually associated with other life threatening injuries (52%-100%) distracting from the diaphragmatic injury [4,5]. In the multiply injured patient, emergent priorities are directed at resuscitation, stabilization, and treatment of cardiovascular problems.

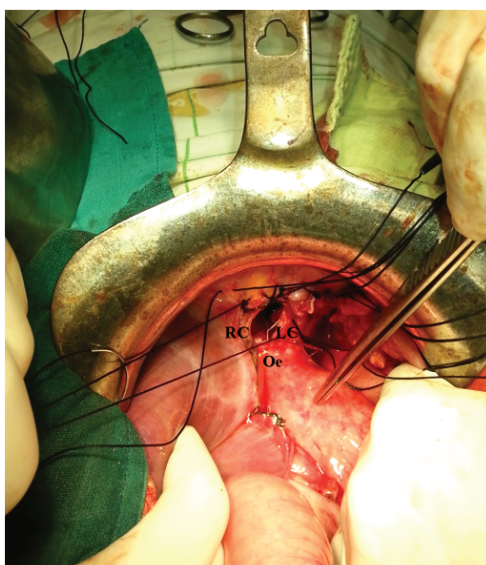
Injuries of the left hemidiaphragm are three times more frequently than injuries of the right side following blunt trauma [3,6], possibly due to a buffering effect of the liver on the right hemidiaphragm [5] as in this case.



**Figure 1:** CT images demonstrate a grossly distended stomach (S) in the left hemithorax, the collapsed left lung parenchyma (LL), the heart is displaced toward the right. (1a) with an air fluid level within (1b), herniated colonic loop (CL) (1c). R: Right, L: Left.



**Figure 2:** An intraoperative photograph of the diaphragmatic defect after reduction of the omentum, the stomach and transverse colon.



**Figure 3:** Extension of the rupture to the esophageal hiatus discovered after the mobilization of the left liver lobe. RC: Right crus, LC: Left crus, Oe: Esophagus.

There are no specific symptoms or signs leading directly to a diagnosis of diaphragmatic rupture [7,8]. The diagnosis is easily missed and requires a high index of suspicion, not because the chest radiograph fails to reveal abnormalities, but rather because the abnormalities present are interpreted incorrectly (7-66%) [4,8].

The progressive herniation of abdominal contents may occur through the defect in the thorax making an indirect specific sign (100%) but less sensitive (55%) [7]; even if the herniation does not take place initially, as in this case, the significant gradient between the higher intra-abdominal and the lower intrathoracic pressures will result in the herniation. The typical organs that herniate into the thoracic cavity include the stomach, spleen, colon and the small bowel [7].

Acute traumatic diaphragmatic injuries are treated by surgical reduction of the herniated organs and closure of the diaphragmatic defect. Given the high rate of associated injuries to intra-abdominal organs, it is generally recommended to approach the diaphragmatic injury through a midline laparotomy [2,9].

The location and extent of the diaphragmatic tears in diaphragmatic rupture varies; furthermore, most articles in the literature do not precisely describe the location and extent of the lesions.

The visualization of both hemidiaphragms should be systematic in every exploratory laparotomy for blunt trauma. Palpation alone is not sufficient and will result in injuries being missed [8]. The caudal suspension of the liver and the section of the left triangular, falciform, and right triangular ligaments if necessary for right hemidiaphragmatic allow a good exposure [8].

The most reported ruptures are in the posterolateral area and extending centrally in a radial fashion, frequently toward the angle between the pericardium and the esophageal hiatus [6,7]. A transverse or central lesions and peripheral detachment also can be found.

Involvement of the esophageal hiatus is uncommon [7,10], the crural extension of a hemidiaphragmatic tear consequent to blunt trauma has been reported only once [8,11]. In this case, the mobilization of the left liver lobe by the section of the left triangular and falciform ligaments showed the extension of the tear to the esophageal hiatus.

The use of prosthetic mesh to achieve a tension-free repair of large diaphragmatic defects is not advised in the acute setting [9].

## Conclusion

Blunt traumatic diaphragmatic rupture is rare. A hemidiaphragmatic tear consequent to blunt trauma may involve the esophageal hiatus. The visualization of both hemidiaphragms should be systematic in every exploratory laparotomy for blunt trauma.

## Competing Interests

The authors declare that there is no conflict of interest regarding the publication of this paper.

## Authors' contributions

All authors contribute in the management of the patient and the redaction of this article.

## References

1. Dirican A, Yilmaz M, Unal B, Piskin T, Ersan V, et al. (2011) Acute traumatic diaphragmatic ruptures: A retrospective study of 48 cases. *Surg Today* 41: 1352-1356.

2. Hanna WC, Ferri LE, Fata P, Razek T, Mulder DS (2008) The current status of traumatic diaphragmatic injury: lessons learned from 105 patients over 13 years. *Ann Thorac Surg* 85: 1044-1048.
3. Peer SM, Devaraddeppa PM, Buggi S (2009) Traumatic diaphragmatic hernia-our experience. *Int J Surg* 7: 547-549.
4. Bocchini G, Guida F, Sica G, Codella U, Scaglione M (2012) Diaphragmatic injuries after blunt trauma: are they still a challenge? Reviewing CT findings and integrated imaging. *Emerg Radiol* 19: 225-235.
5. Scharff JR, Naunheim KS (2007) Traumatic diaphragmatic injuries. *Thorac Surg Clin* 17: 81-85.
6. Schumpelick V, Steinau G, Schluper I, Prescher A (2000) Surgical embryology and anatomy of the diaphragm with surgical applications. *Surg Clin North Am* 80: 213-239.
7. lochum S, Ludig T, Walter F, Sebbag H, Grosdidier G, et al. (2002) Imaging of diaphragmatic injury: a diagnostic challenge? *Radiographics* S103-S116.
8. Wyffels PL, Kenny JN (1984) Primary repair of bilateral diaphragmatic rupture with crural involvement. *Am J Surg* 147: 414-417.
9. Hanna WC, Ferri LE (2009) Acute traumatic diaphragmatic injury. *Thorac Surg Clin* 19: 485-489.
10. Mueller CF, Pendarvis RW (1994) Traumatic injury of the diaphragm: Report of seven cases and extensive literature review. *Emer radiol* 1: 118-132.
11. Andrus CH, Morton JH (1970) Rupture of the diaphragm after blunt trauma. *Am J Surg* 119: 686-693.