

Pseudoaneurysm Formation after Laparoscopic Partial Nephrectomy

Bruno Lopes Cancado Machado*

Department of Urology, University of Arkansas for Medical Sciences, Little Rock, Arkansas, USA

***Corresponding author:** Bruno Lopes Cancado Machado, Department of Urology, University of Arkansas for Medical Sciences, Little Rock, Arkansas, USA, E-mail: bmachado@uams.com

Received: 12 Jun, 2018 | **Accepted:** 22 Jun, 2018 | **Published:** 27 Jun, 2018

Citation: Machado BLC (2018) Pseudoaneurysm Formation after Laparoscopic Partial Nephrectomy. J Surg Open Access 4(2): dx.doi.org/10.16966/2470-0991.169

Copyright: © 2018 Machado BLC. This is an open-access article distributed under the terms of the Creative Commons Attribution License, which permits unrestricted use, distribution, and reproduction in any medium, provided the original author and source are credited.

The Laparoscopic Partial Nephrectomy (LPN) is the “gold standard” to management of small renal masses (Figure 1) [1,2]. The patient, a 38 year Male at 8th post-operative day from right upper pole PN, presented at ER with a voluminous gross hematuria (Figure 2). The clinical diagnosis was a renal pseudoaneurysm. The patient was hemodynamically stable, and a medical approach was tried. After 12 hours of clinical management, the hematuria had not stopped. A transfemoral arteriography was done, and the Pseudoaneurysm diagnosis was confirmed (Figure 3). An intravascular embolization was performed (Figure 4) and the hematuria ceased in the day after.

The patient had two small episodes of hematuria in the next 48 hours after the endovascular procedure. Those episodes were not

reflected in his hemodynamic status and laboratorial blood work. After one and a half year of follow up, the patient has no oncologic or hematuria recurrence.

The pseudoaneurysm after LPN is a rare event. It happens in only 2% or less of the patients [2]. The prompt diagnosis and treatment are crucial to avoid major complications [3].

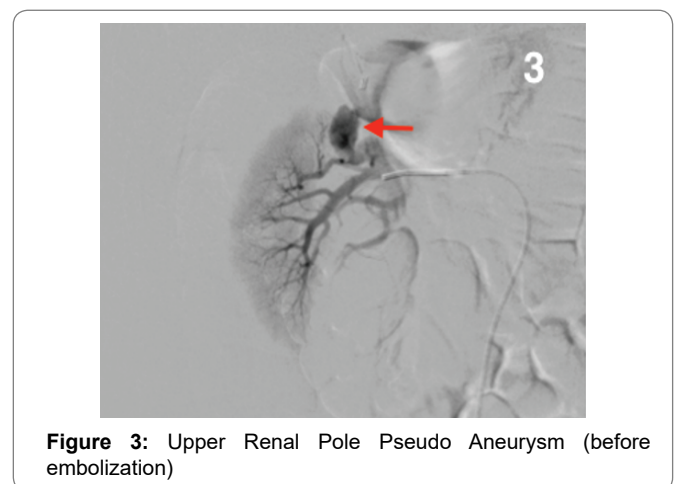
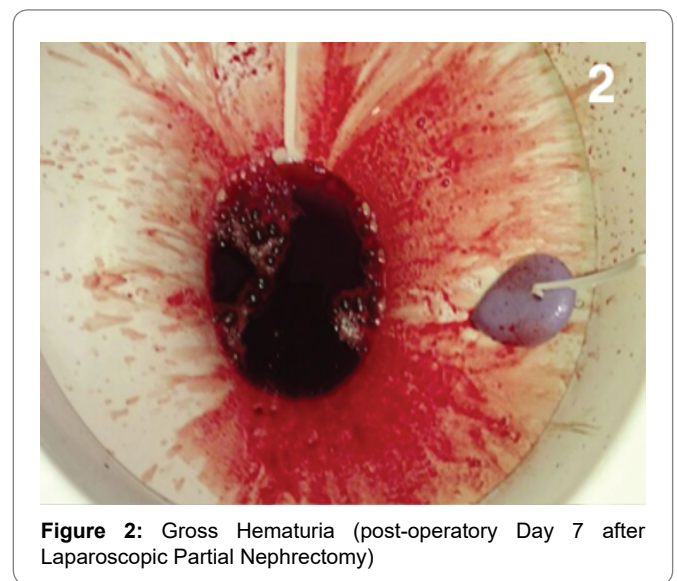
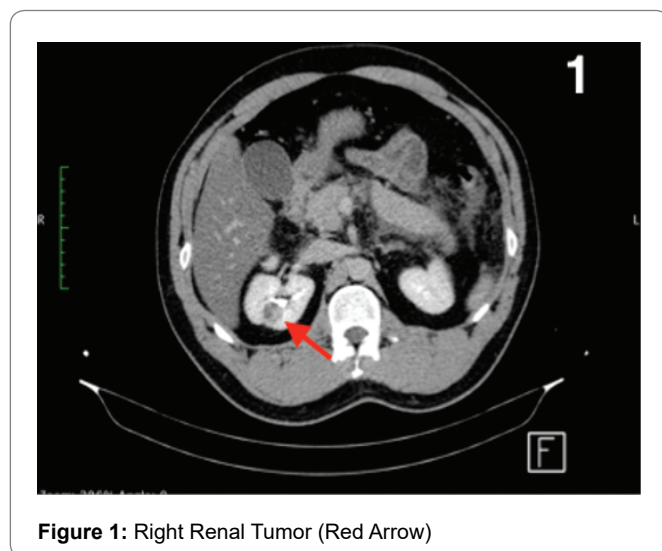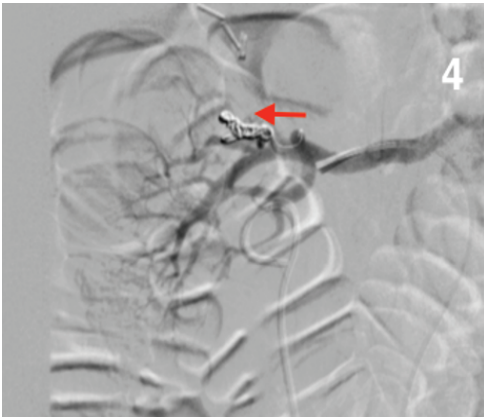




Figure 4: Upper Renal Pole Pseudo Aneurysm (after embolization)

References

1. Sampogna G, Pugliese R, Elli M, Vanzulli A, Forgione A (2017) Routine clinical application of virtual reality in abdominal surgery. *Minim Invasive Ther Allied Technol* 26: 135-143.
2. Gupta N, Patel A, Ensor J, Ahrar K, Ahrar J, et al. (2017) Multiple Renal Artery Pseudoaneurysms in Patients Undergoing Renal Artery Embolization Following Partial Nephrectomy: Correlation with RENAL Nephrometry Scores. *Cardiovasc Intervent Radiol* 40: 202-209.
3. İşik A, Firat D, Idiz UO (2018) Approaches to Recurrent/Complicated and Acute Cases. *Türkiye Klinikleri Journal of General Surgery Special Topics* 11: 112-114.